A Crash Course in Diagnosing Common and Not-So-Common Head and Neck Lesions

Kathleen T. Montone, M.D., FASCP
Zubair W. Baloch, M.D., Ph.D., FASCP
Virginia A. LiVolsi, M.D., FASCP

Department of Pathology and Laboratory Medicine
University of Pennsylvania

Financial Disclosure Information

Kathleen T. Montone, M.D., FASCP – NONE

Zubair W. Baloch, M.D., Ph.D., FASCP –VERACYTE CORPORATION, CONSULTANT

Virginia A. LiVolsi, M.D., MASCP – VERACYTE CORPORATION, CONSULTANT

Course Objectives

- Differential diagnosis and work up of necrotizing sinonasal lesions.
- Differential diagnostic considerations in salivary gland lesions
- Differential diagnosis of cystic neck lesions

Cystic Lesions of Head and Neck: Cytomorphology, Histopathologic Follow-up and Ancillary Studies.

Zubair W. Baloch, MD, PhD
Professor of Pathology & laboratory medicine. UPENN medical center. Philadelphia, PA.

Disclosure

- Consultant, Veracyte, INC.

Course Objectives

- Generate a cytologic differential diagnosis for various cystic and solid head and neck lesions.
- Recognize the pitfalls in the cytologic and histologic diagnosis of primary and metastatic head and neck lesions.
- Discuss the value of special techniques in the diagnosis of head and neck and salivary gland tumors.

Case 1

- 60-year-old man with right neck mass
- ? Tail of parotid mass vs. lymph node
- US – cystic mass
  - Favor metastasis to cervical node
  - Thyroid US – no suspicious nodules
- Panendoscopy
  - No mucosal abnormalities
  - ? Mass of right tonsil

FNA of right neck mass

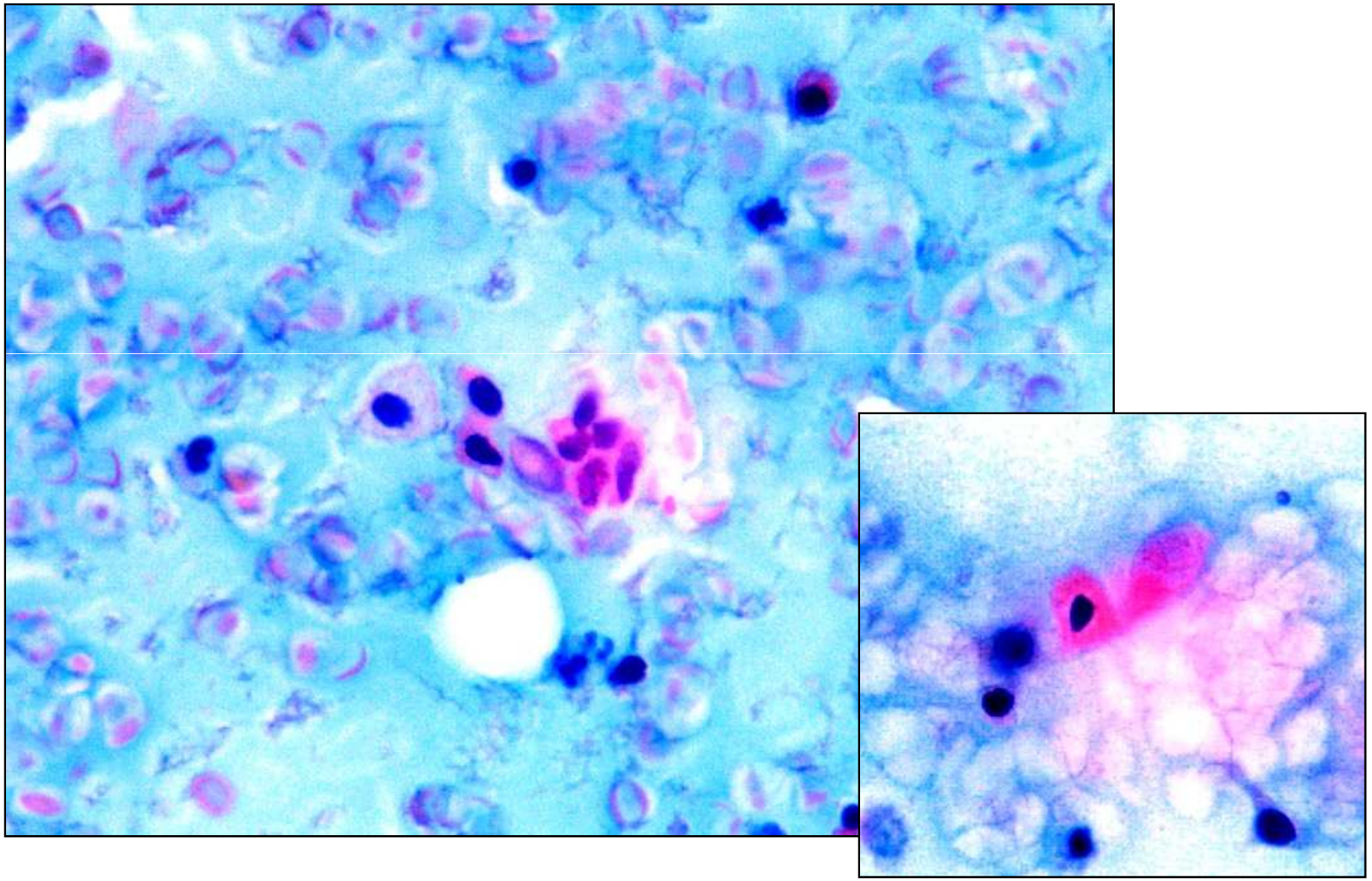

FNA of right neck mass

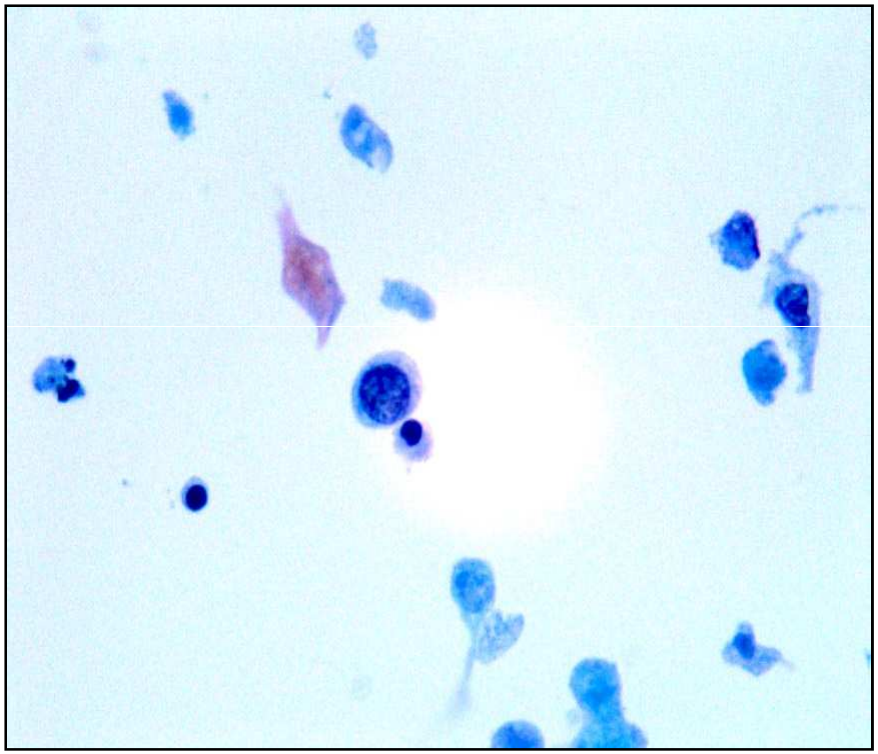

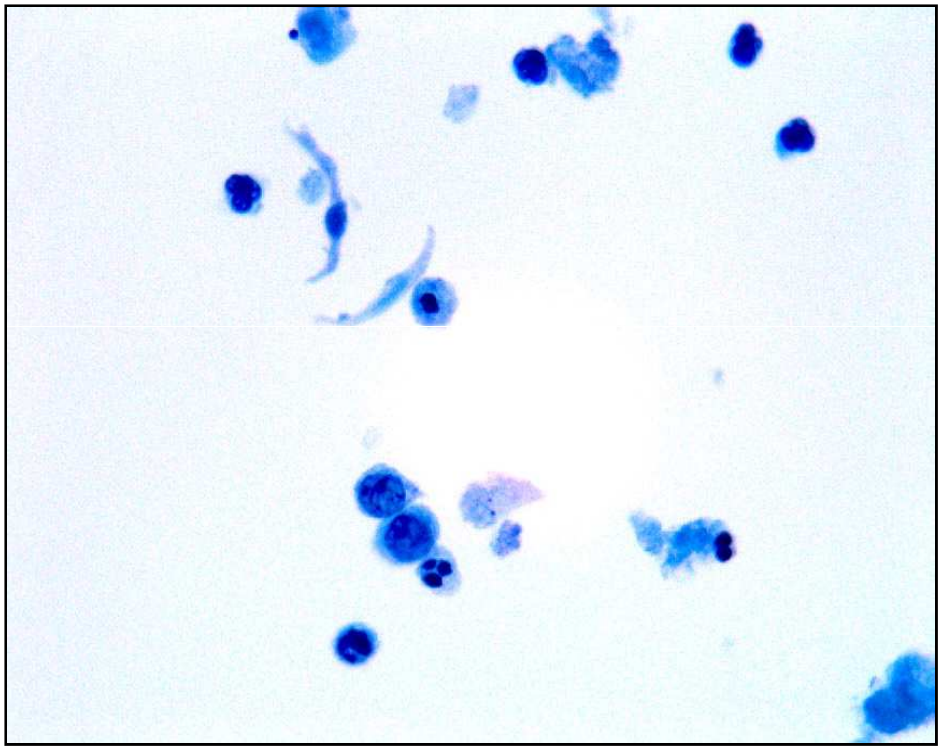

FNA of right neck mass

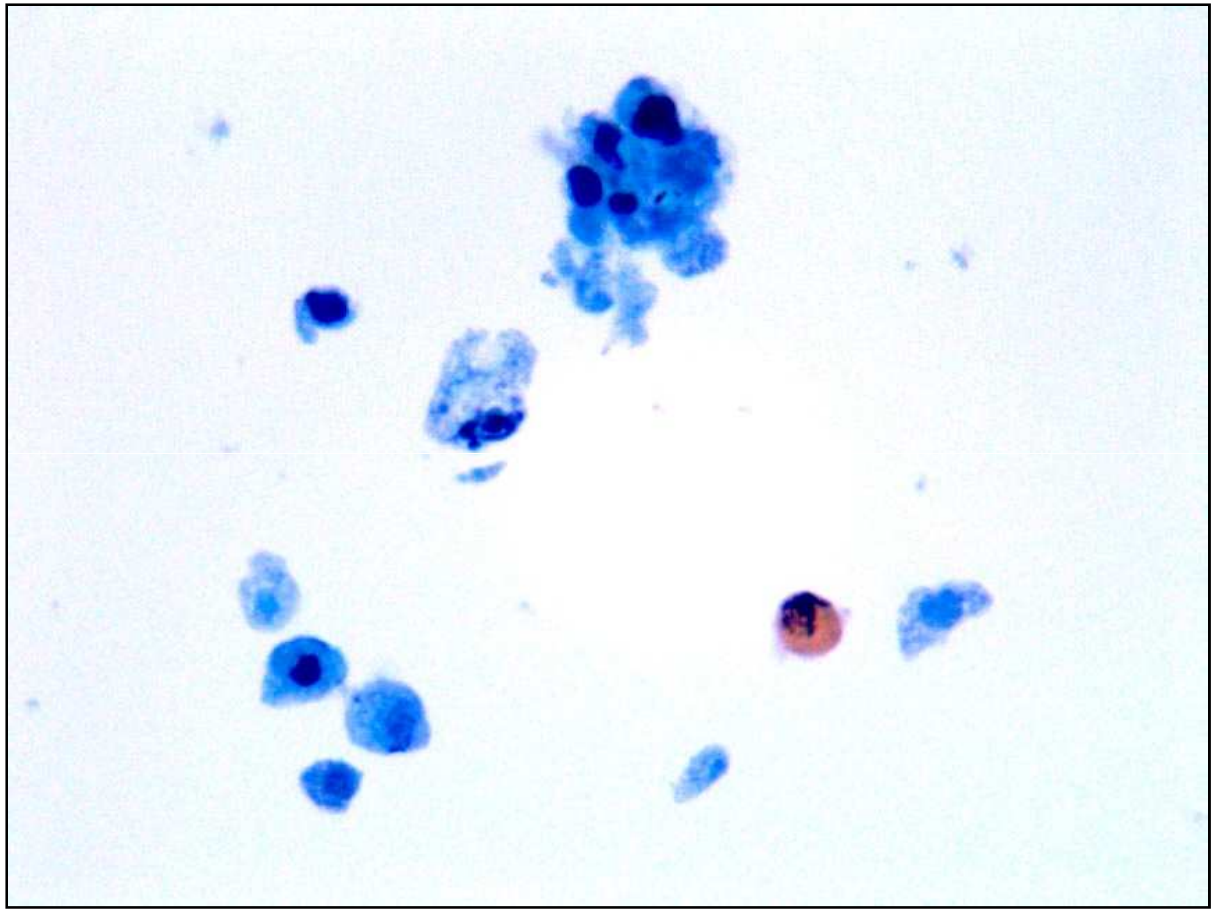

Cytology Dx: Squamous cell carcinoma

Tonsil Biopsy

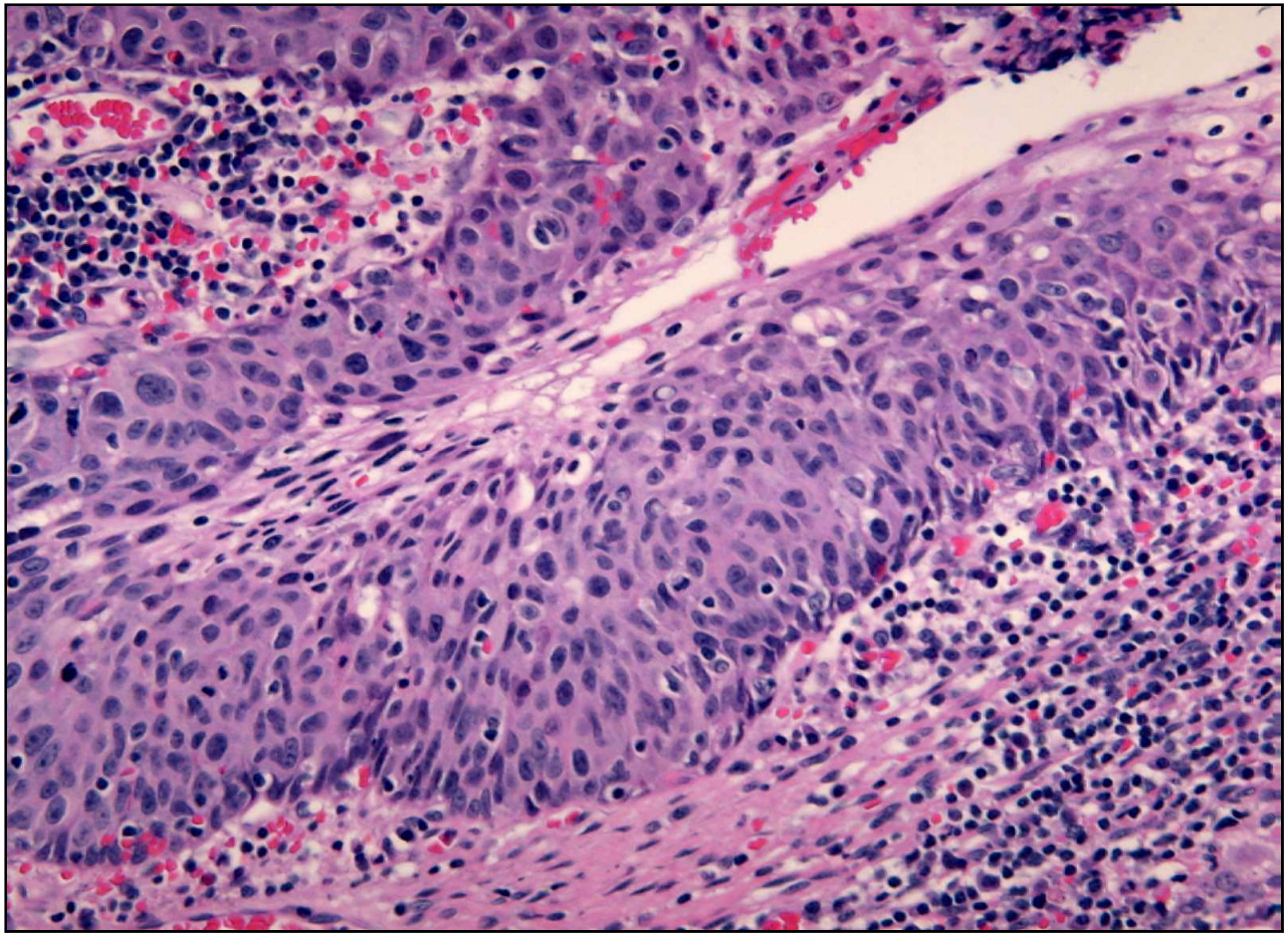

Squamous cell carcinoma

Incidence of unsuspected carcinoma in cervical cystic lesions

Study	***Incidence (%)***	***No. of Patients***
Krogdahl (1979)	4	7/161
Cinberg et. al (1982)	22	4/18
Granstrom & Edstrom (1989)	21	9/42
Flannagan et. al (1994)	16	4/25
Gourin & Johnson (2000)	10	12/121
Sheahan et. al (2002)	24	8/33

Sensitivity of FNA in the diagnosis of malignancy in cystic neck lesions

Study	***Sensitivity (%)***
Cinberg et al. (1982)	33
Granstrom & Edstrom (1989)	33
Flannagan et al. (1994)	50
Gourin & Johnson (2000)	37.5
Sheahan et al. (2002)	73
Moatamed et al. (2009)	76
Baykul et al. (2010)	90

Cystic Lesions of the Neck

- Congenital
- Acquired
- Majority of neck cysts in newborns and infants are developmental
- Children and adults – Inflammatory or neoplastic

Cystic Lesions of the Neck

Congenital / Developmental	***Traumatic***	***Inflammatory***	***Neoplastic Benign***	***Neoplastic Malignant***
Branchial Cleft Cyst	Arteriovenous fistula	Abscess	Cystic Schwannoma	Cystic Nodal Mets from SCC
Thyroglossal duct cyst	Laryngocele	Tuberculosis	Parathyroid cyst	Cystic Nodal Mets from PTC
Lymphatic malformations		Ludwigs Angina*	Goitrous nodule or Cystic PTC	Cystic Mets from other organs
Epidermoid or Dermoid		HIV related – Lymphoepithelial cyst	Thymic cyst	Salivary gland
Bronchogenic & Esophageal duplication cysts		Ranula	Salivary Gland	

Congenital Cysts

- First Branchial Cleft Cyst
  - Residual embryonic tract
  - Extends from external auditory canal (EAC) through the parotid gland to the submandibular region
  - Type 1 – Periauricular
  - Type 2 – Periparotid (extending from the EAC to the angle of mandible)
- II, III, IV branchial cleft cysts

Branchial Cleft Cyst-FNA

- Turbid white yellow fluid
  - Variable number of squamous cells and aellualr squames
  - Cellular debris
  - Inflammatory cells

  - Squamous cell with atypia?
  - Branchial cleft cyst in older patients?

Benign Squamous Cystic Lesion
vs.
Cystic Mets of Squamous Carcinoma

Not so easy

45-year old man with left neck cystic mass

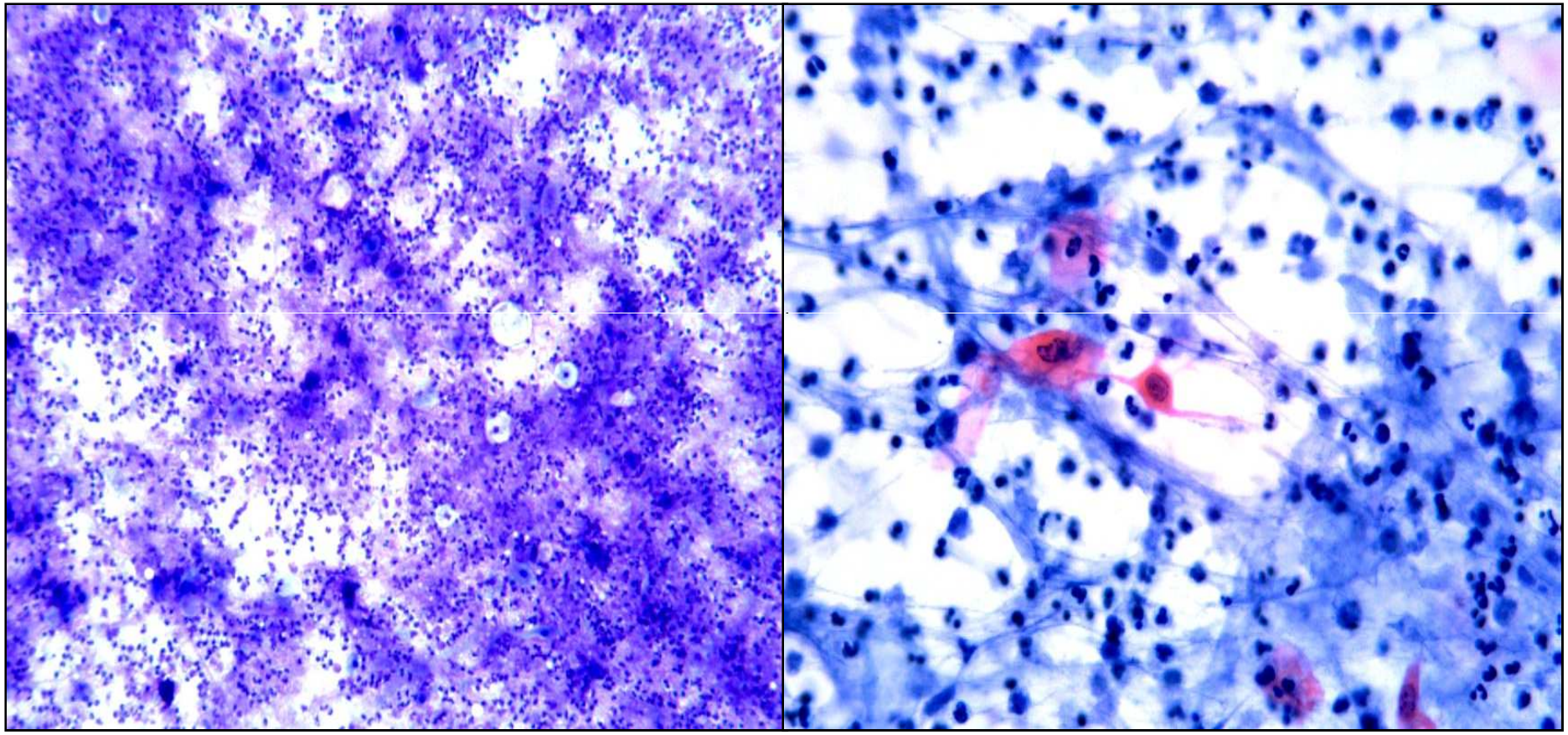

45-year old man with left neck cystic mass

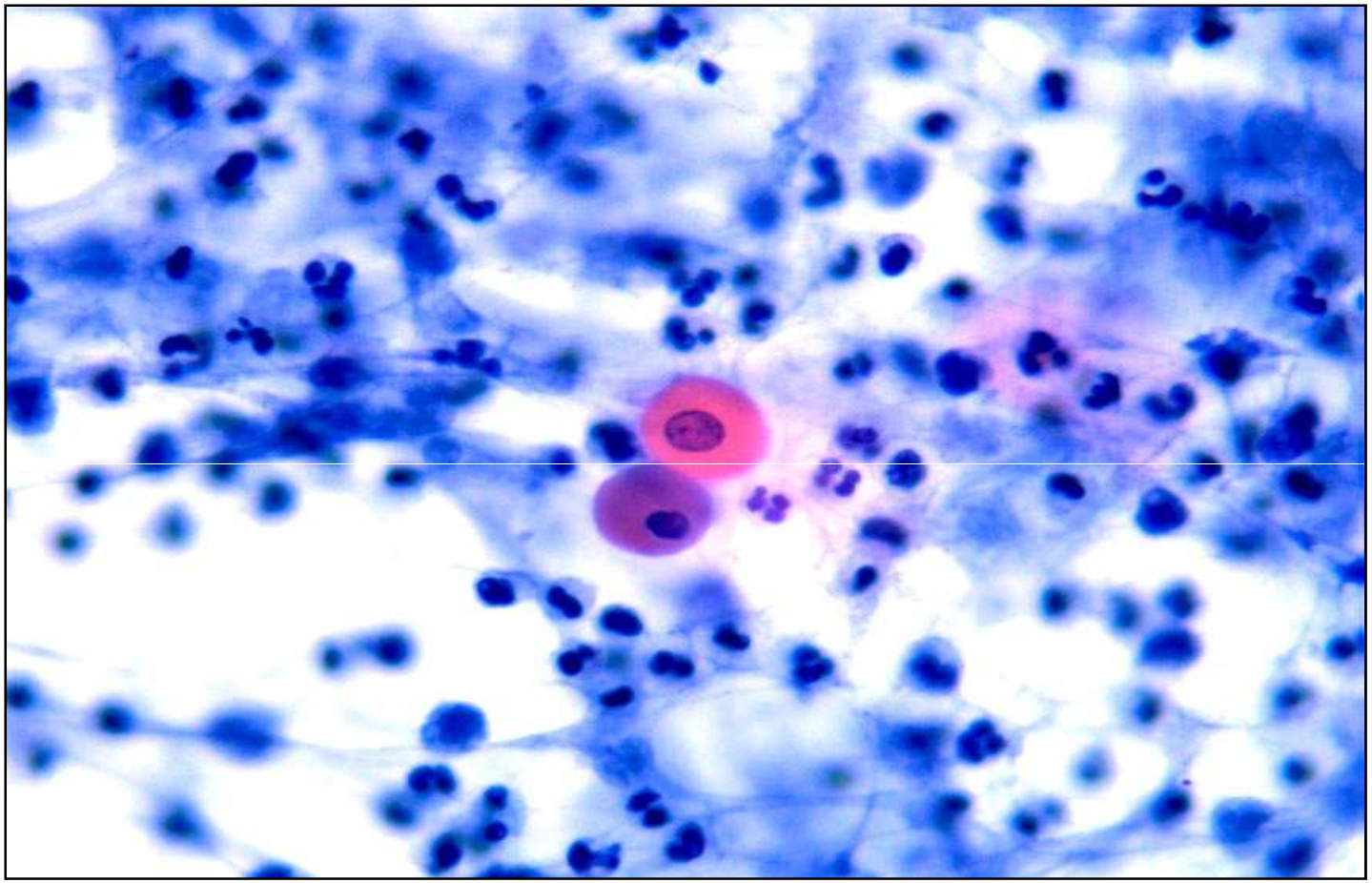

Atypical squamous cells in the background of marked acute inflammation

45-year old man with left neck cystic mass

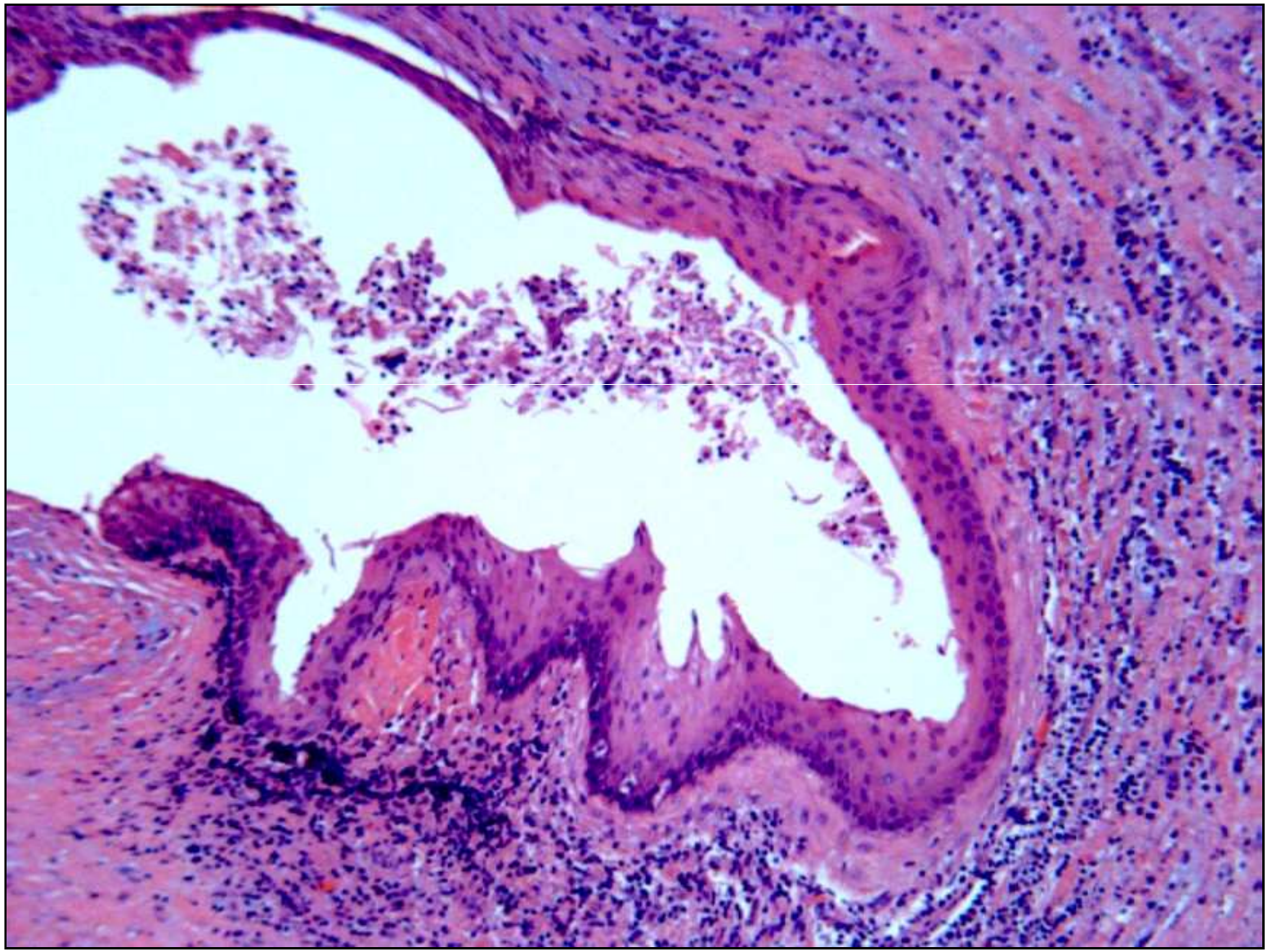

45-year old man with left neck cystic mass

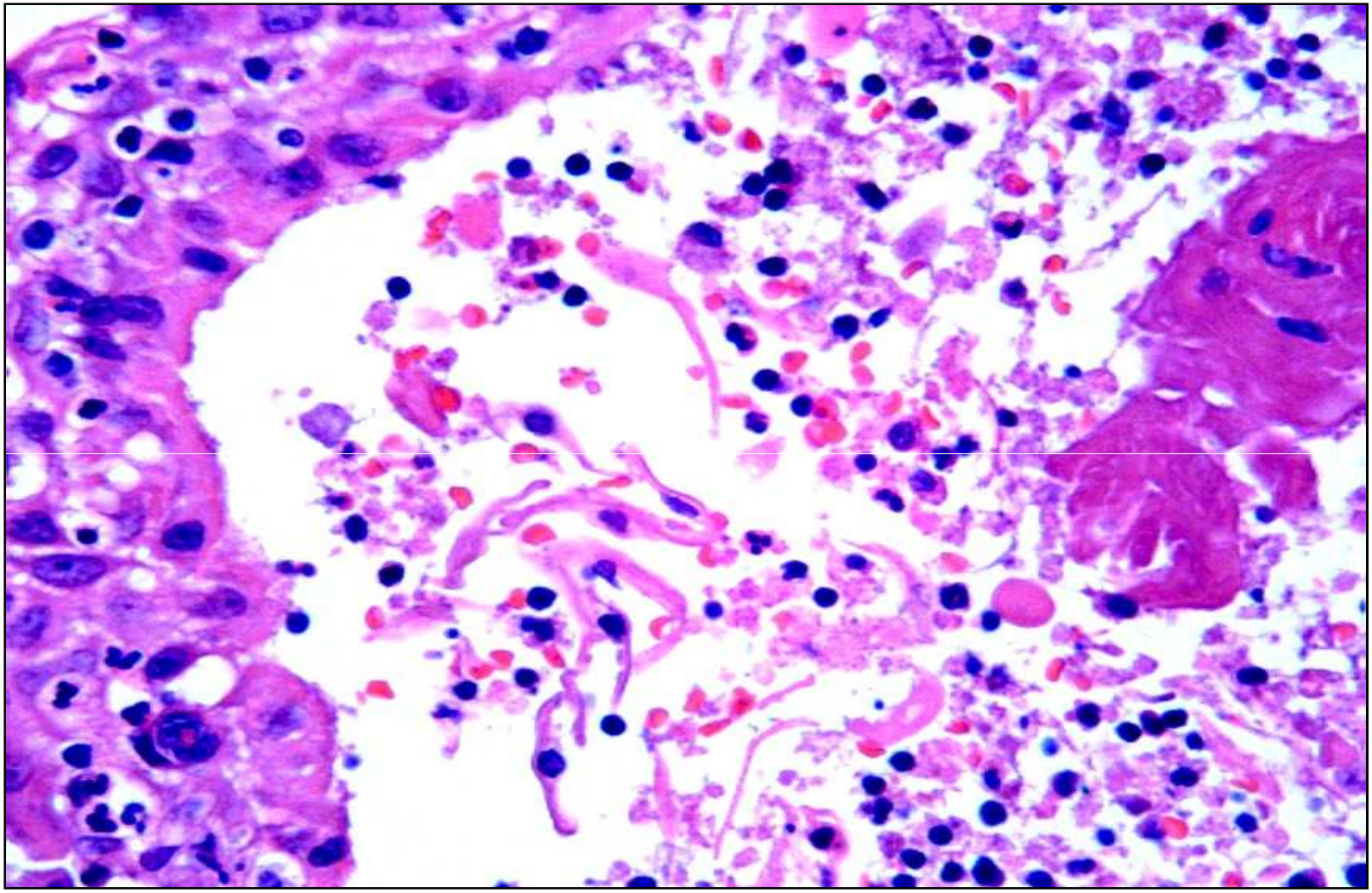

Inflamed branchial cleft cyst

Benign Squamous Cystic Lesion
vs.
Cystic Mets of Squamous Carcinoma

Cytologic Features	***Benign Mean/Std.Err***	***Malignant Mean/Std.Err***	***P-value***
Cell-Groups	1.0 / 0.36	3.3 / 0.28	<.0001
Single Cells	3.3 / 0.33	2.1 / 0.34	NS
Anucleate Cells	2.9 / 0.43	1.5 / 0.33	NS
Nuclear Atypia	0.58 / 0.26	3.6 / 0.15	<.0001
Backgr-Necrosis	1.0 / 0.32	2.7 / 0.27	<.0004
Backgr-Infl	1.0 / 0.39	1.6 / 0.35	NS
P53 staining	1.1 / .16	1.4 / .14	NS

Benign Squamous Cystic Lesion
vs.
Cystic Mets of Squamous Carcinoma

Inflamed Branchial Cleft Cyst

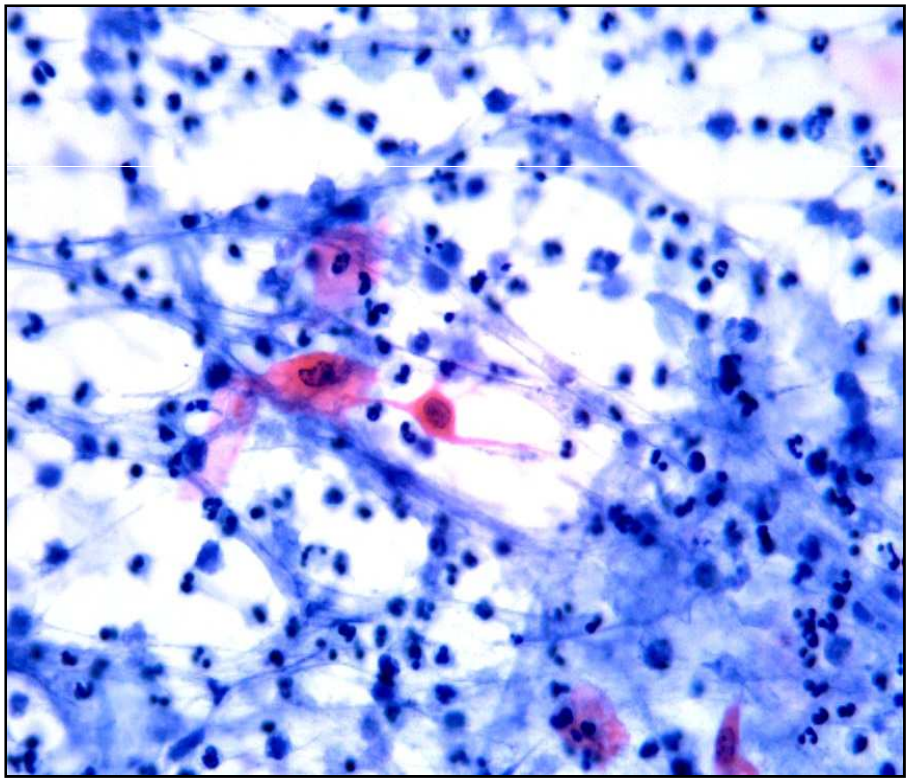

Cystic Mets of Squamous Carcinoma

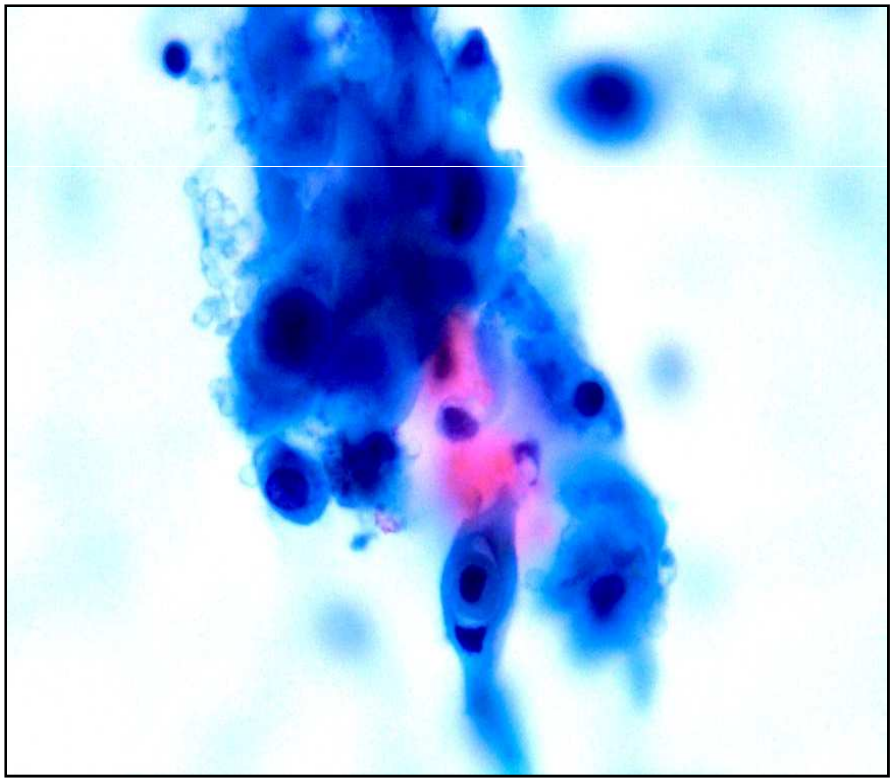

Benign Squamous Cystic Lesion
vs.
Cystic Mets of Squamous Carcinoma

- Clues
  - Clinical history – could be occult primary
  - Inflammation – common in benign
    - Acute inflammation with keratinizing squamous lesions
  - N/C ratio
    - Maintained in benign lesions
  - Nuclear atypia
  - Excisional biopsy
  - P53, p16

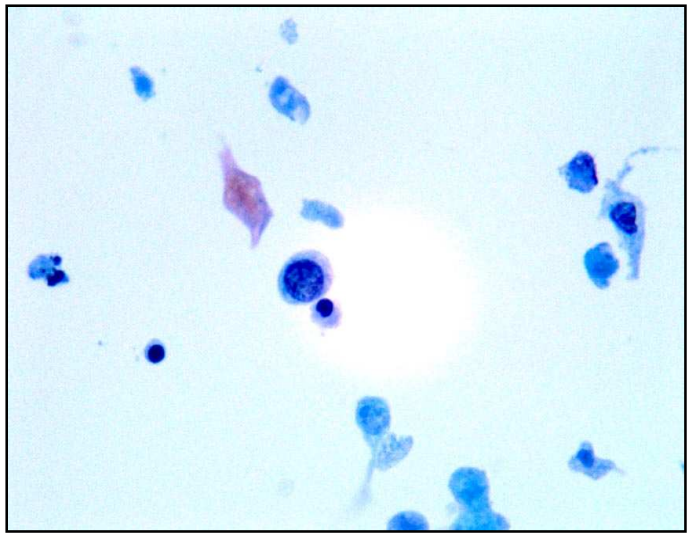

HPV in Squamous Cell Carcinoma

Head & Neck Squamous Cell Carcinomas (HNSCCs)

- HNSCCs- 6.5% of annual cancer cases worldwide
  - Estimated 38/100,000 new cases/yr (U.S.)
  - Median age = 60 yrs
  - 2/3 Males: 1/3 Females
  - Incidence in Western Europe and U.S increasing over last few decades

Oncogenesis of HPV

- **Multistep/Multifactor process**
  - Oncogenes
  - Modification of cellular genes
  - Possible genetic susceptibility of host
  - Impaired cell-mediated immunity
- **Genome of dsDNA incorporation**
  - "Early" Region encodes for "Early Proteins" E1-E7 (important in pathogenesis and transformation)
  - E6, E7 classified as oncogenes
    - E6 binds to p53 and degrades it
    - E7 binds to pRB and causes dysfunction
      - Results in inhibition of the cell cycle control and facilitation of tumor development

HPV in Oropharyngeal Cancer

- Significantly higher HPV prevalence found in oropharyngeal SCCs that oral or laryngeal SCCs (Kreimer et al., 2005)
- Proposed that HPV-positive oropharyngeal SCC is a distinct entity, less dependant on smoking and alcohol use (Klussmann et al, 2003)

HPV in Other Head & Neck Tumors

- Prevalence varies in the literature
  - Possibly due to methods of analysis
    - 14-35% by PCR
    - 25% by Southern Blot
    - 18% by FISH
  - Most common HPV locations (other than oropharynx)- [Dahlstrand & Dalianis, 2005]
    - Tongue Cancer (19-100%)
    - Laryngeal Cancer (10-50%)

Termine et al. 2008

Subgroup	*Number of Studies*	Mean prevalence (%)
HNSCC n.s.	**15**	**24.1**
OSCC	**47**	**38.1**
ISH based	13	32.9
PCR based	52	34.8
HNSCC n.s.s. ISH based	2	n.c.
HNSCC n.s.s. PCR based	13	20.8
OSCC PCR based	36	39.9
OSCC ISH based	11	29.8
Overall	62	34.5

HPV Status and Prognosis

HPV and Prognosis in Oropharyngeal Cancer

- **HPV may be a favorable prognostic factor** (Gillison et al, 2000;Mellin et al., 2000)
  - Mellin et al., 2000
    - 60 pts with tonsillar cancer
      - 52% of pts with HPV +ve tumors were disease free after 3 years
      - 21% of pts with HPV –ve tumors were disease free after 3 years
    - Pts with HPV +ve tumors had significantly increased 5-year survival rates compared to HPV –ve tumors (53% vs. 31%, p=0.047)
    - HPV +ve tumors favorable independent of tumor stage, gender, age or differentiation

HPV and Prognosis in Oropharyngeal Cancer

Gillison et al., 2000

- 253 head and neck cancer patients
  - 60 oropharyngeal cancers (mostly tonsil)
- **Results:**
  - Disease-specific survival significantly higher for HPV +ve tumors
  - No change in disease-specific survival for other head and neck cancers
- Multiples studies have shown **no change** in survival for HPV +ve tumors (**except oropharynx**)[reviewed by Dahlstrand & Dalia, 2005]

How Adequate are Head and Neck Fine-needle Aspiration Specimens for HPV Molecular Analysis?

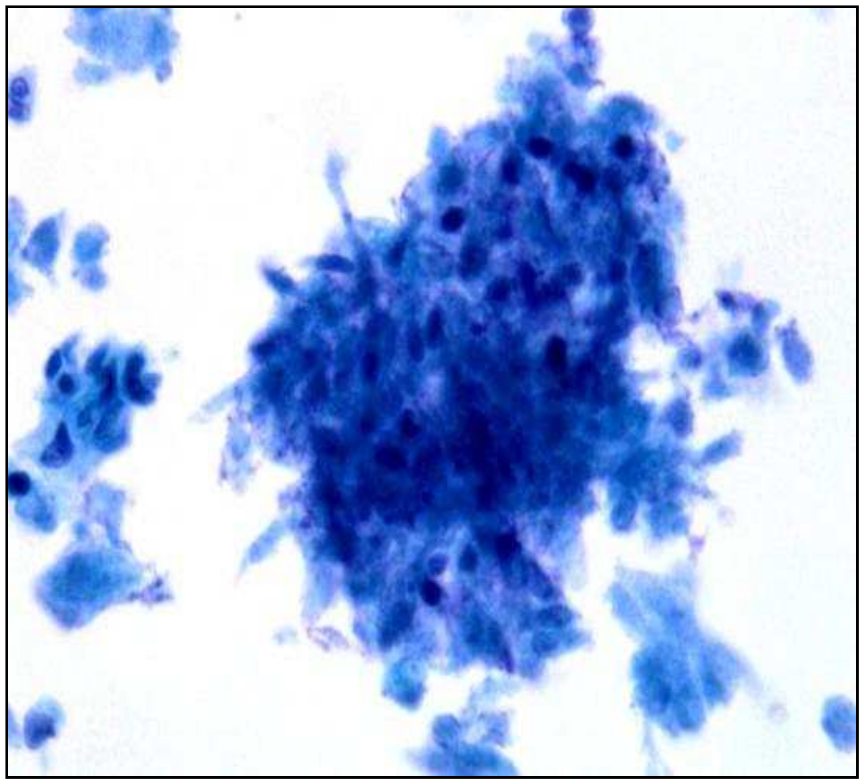

Vs.

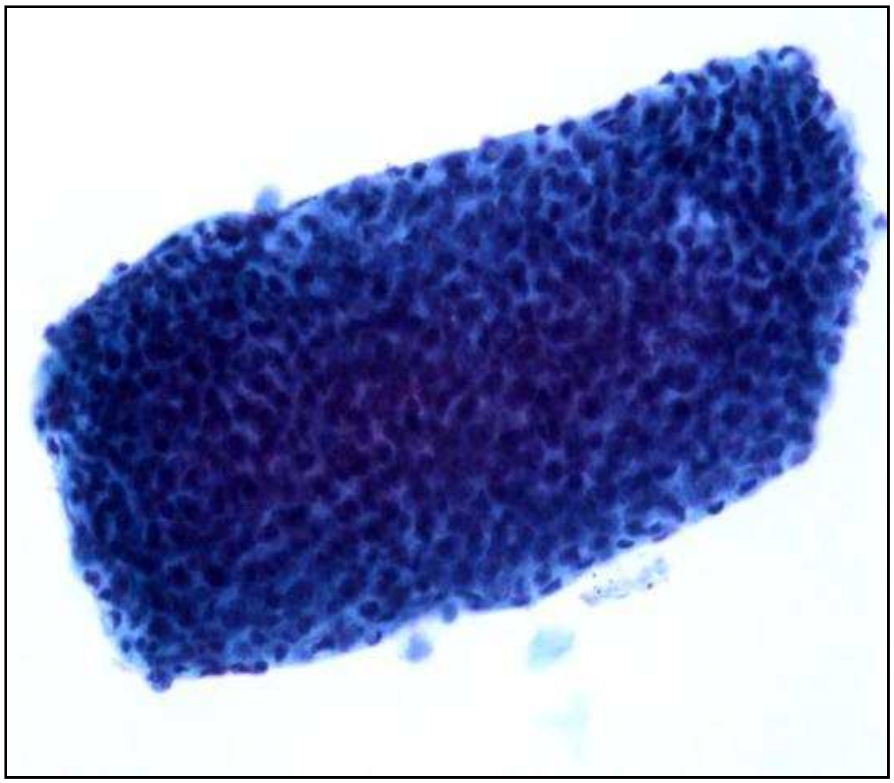

How Adequate are Head and Neck Fine-needle Aspiration Specimens for HPV Molecular Analysis?

- 42 specimens in 40 patients
  - 37 LN's & 5 others ites
  - On-site evaluation in 41 (98%)
  - Final diagnosis – SCC in all
  - 9 cases >80% tumor necrosis
  - Adequate DNA for molecular analysis -28 (67%)
    - 7 (25%) necrotic specimens had adequate for HPV analysis

Thyroglossal Duct Cyst

- Most common congenital neck mass
- Located in mid-line or paramedian (left side)
- Closely related to hyoid bone
  - 20% Suprahyoid, 65% infrahyoid & 15% at the level of hyoid bone **(Grossman & Yousem 1994)**
- Characteristic appearance on US, CT and MRI
  - Hypoechoic thin walled cyst
  - Debris – Hemorrhage or infection
  - Solid mass – Carcinoma (95% PTC & 5% SCC)

Thyroglossal Duct Cyst

- Differential diagnosis
  - Dermoid cyst
  - Necrotic lymphadenopathy
  - Cystic goitrous nodule arising from thyroid isthmus
  - Thymic cyst
  - Branchial cleft cyst – paramedian location
  - Cystic hygroma – paramedian location

Thyroglossal Duct Cyst - FNA



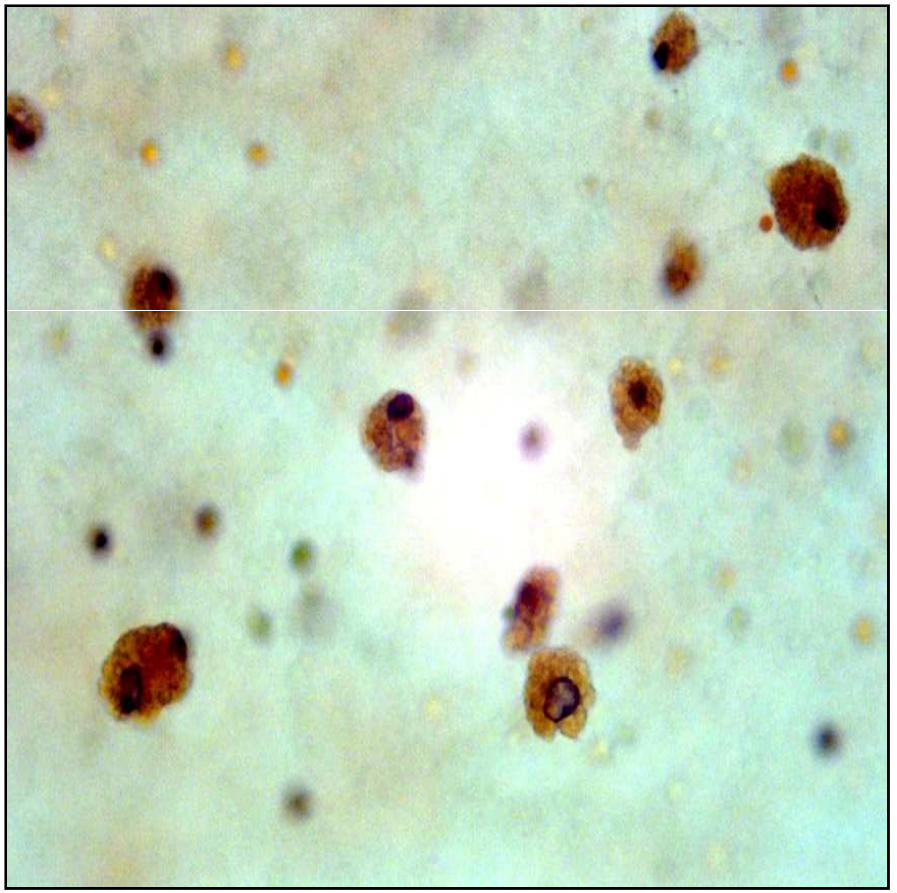

Thyroglossal Duct Cyst

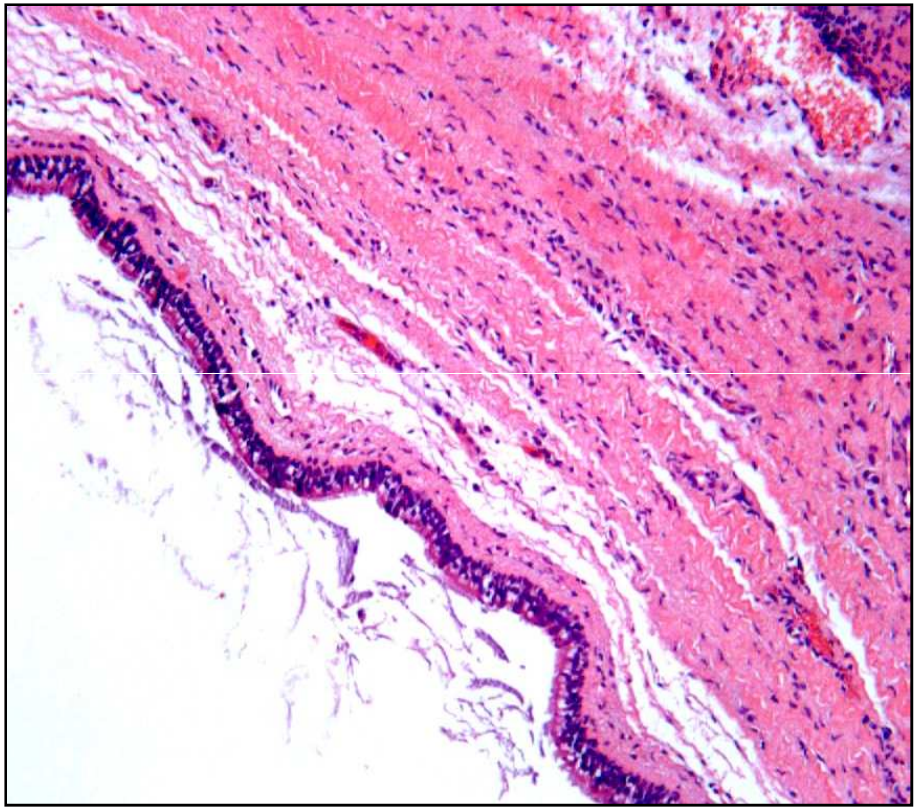

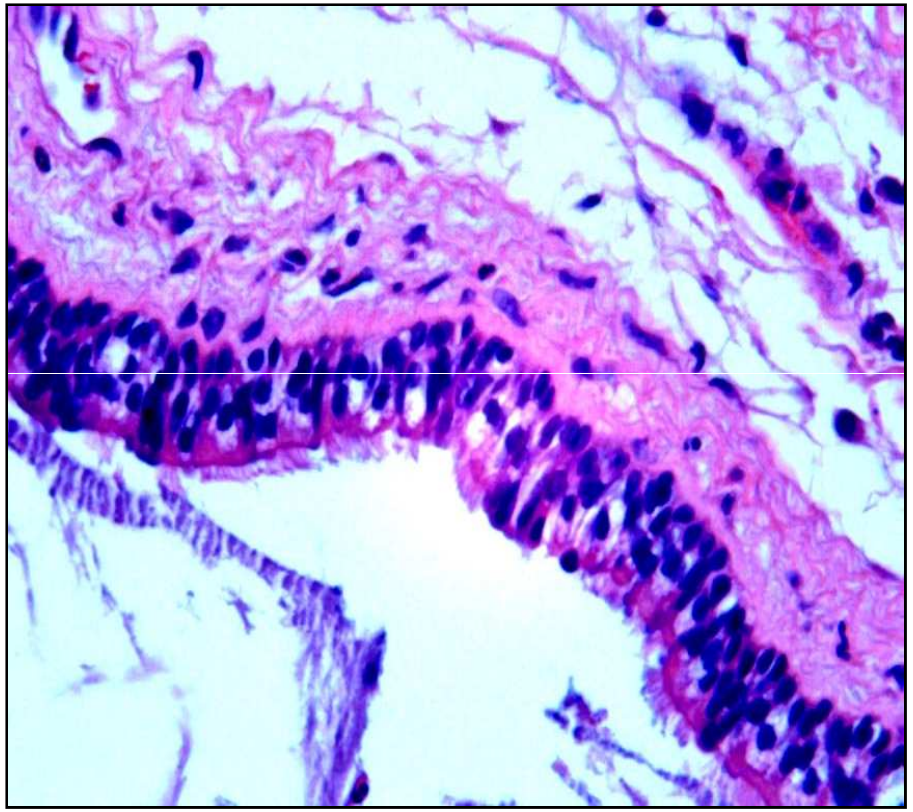

Lined by respiratory or squamous epithelium, or both
Mucus glands – seen in 60% of cases
Infection - Granulation tissue or scar
Thyroid tissue – Routine section 5%; serial sections 40%

Thyroglossal Duct Cyst

- Carcinoma – 95% PTC & 5% SCC
- Criteria
  - Demonstration of thyroglossal remnant
  - Normal thyroid gland (US exam?) to differentiate from PTC metastasis from thyroid

Thyroglossal Duct Cyst Carcinoma

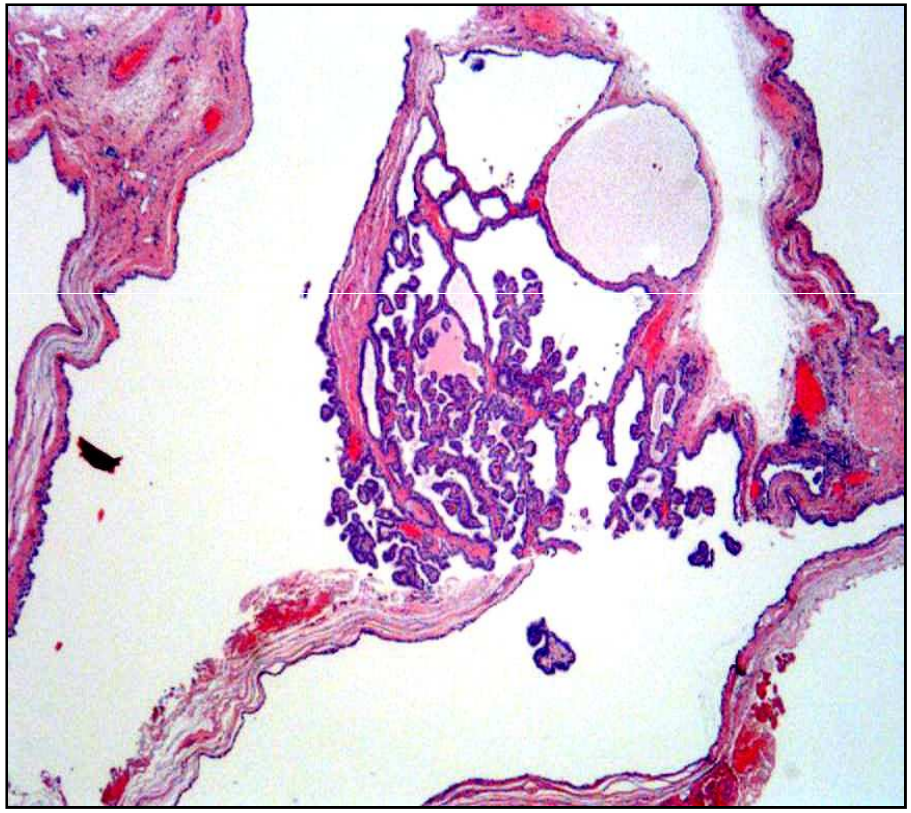

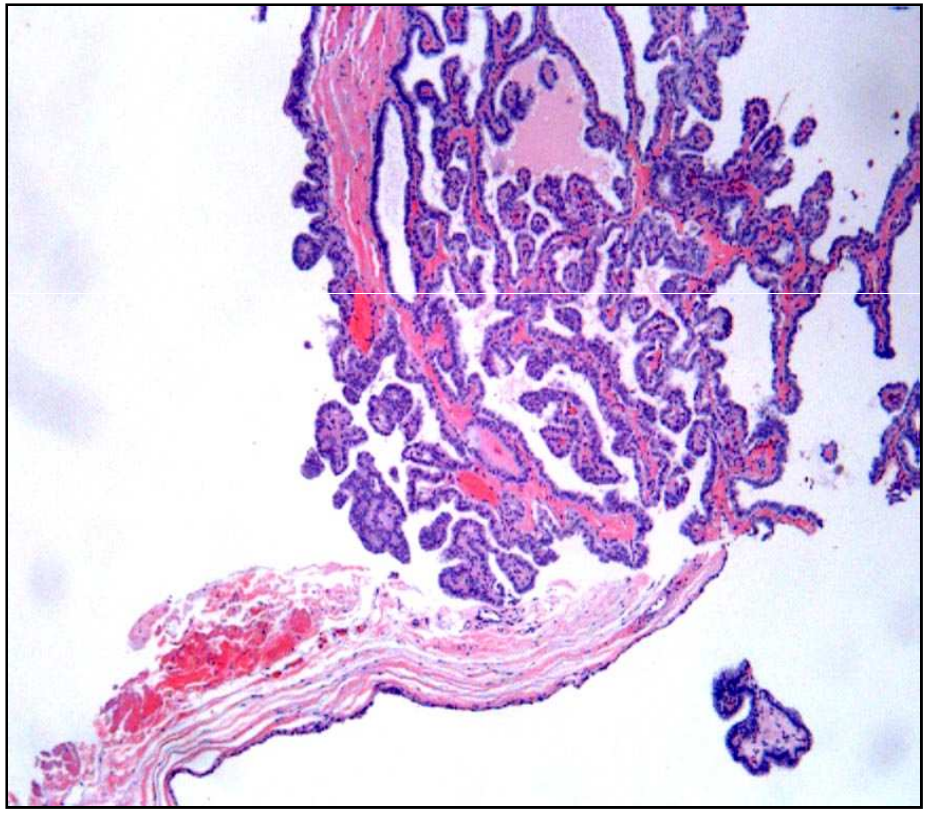

Thyroglossal Duct Cyst Carcinoma

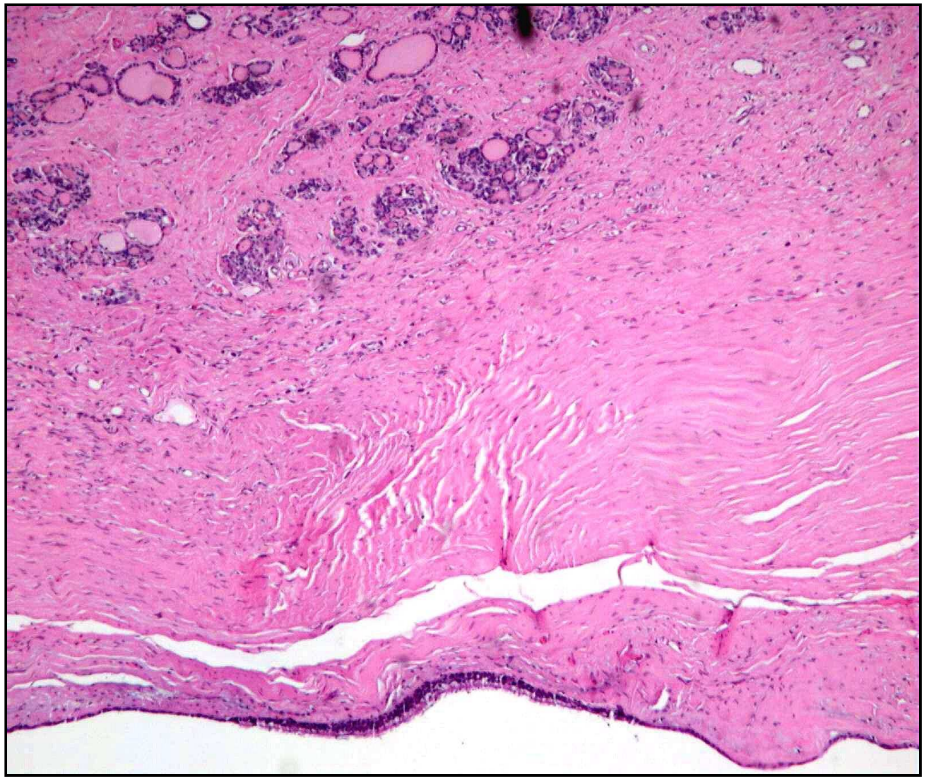

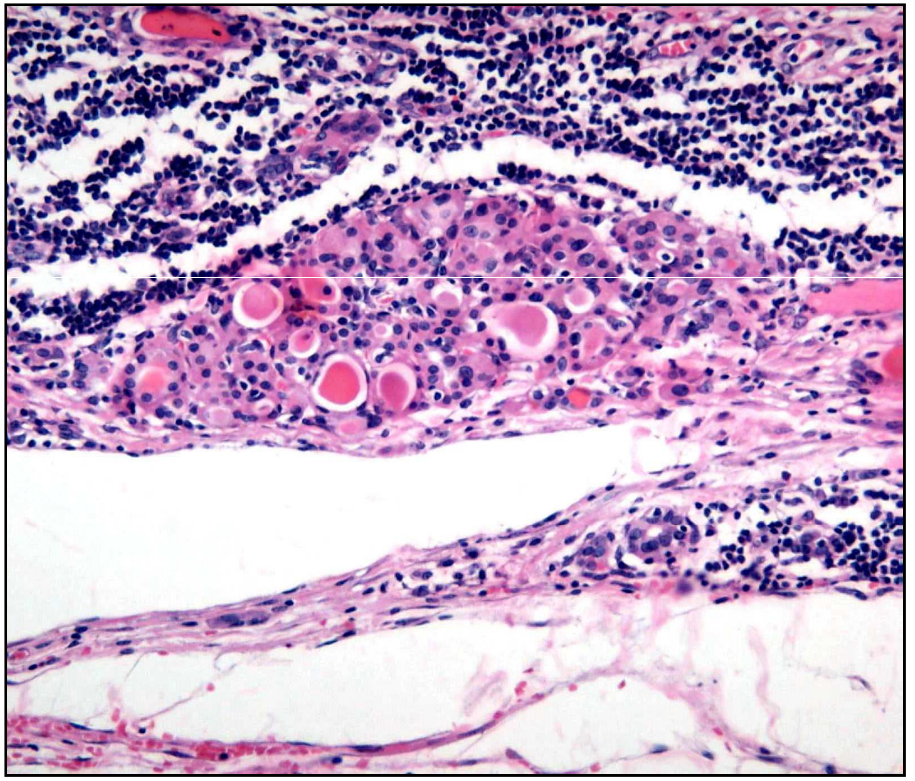

35-year-old woman with left lateral neck cystic mass

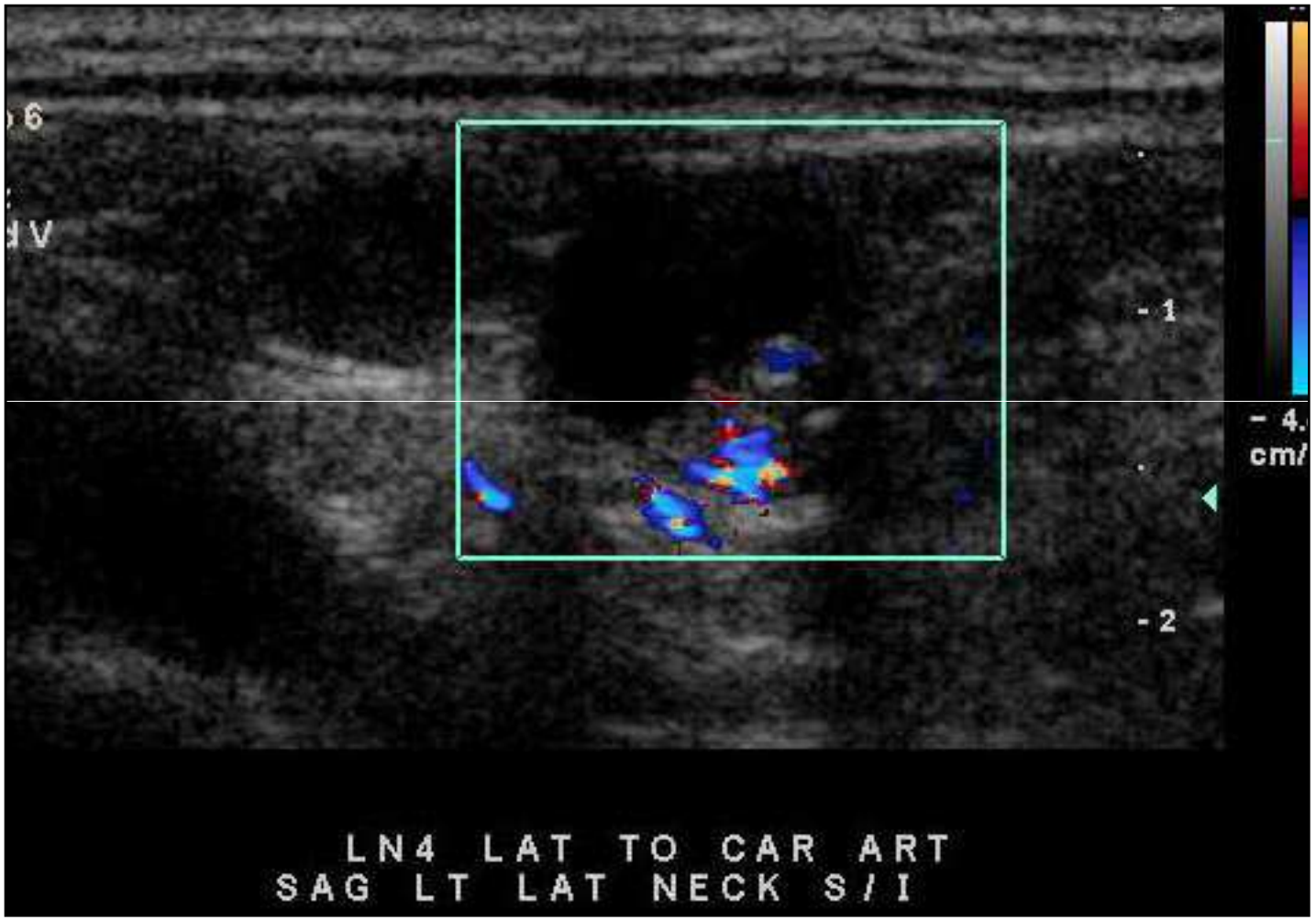

35-year-old woman with left lateral neck cystic mass



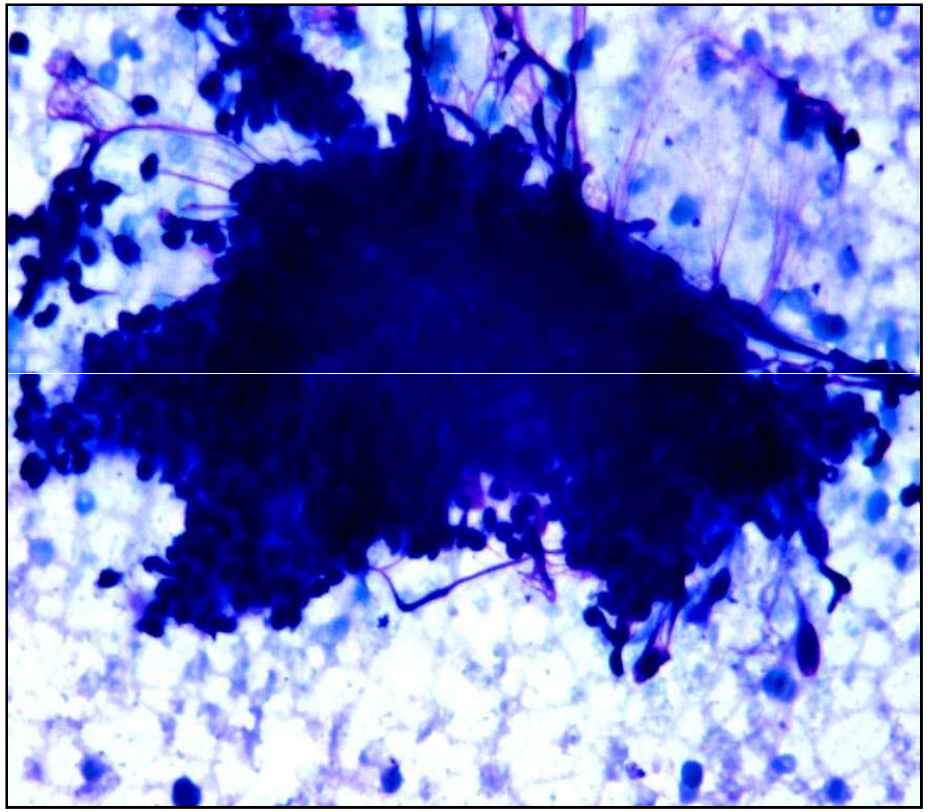

35-year-old woman with left lateral neck cystic mass

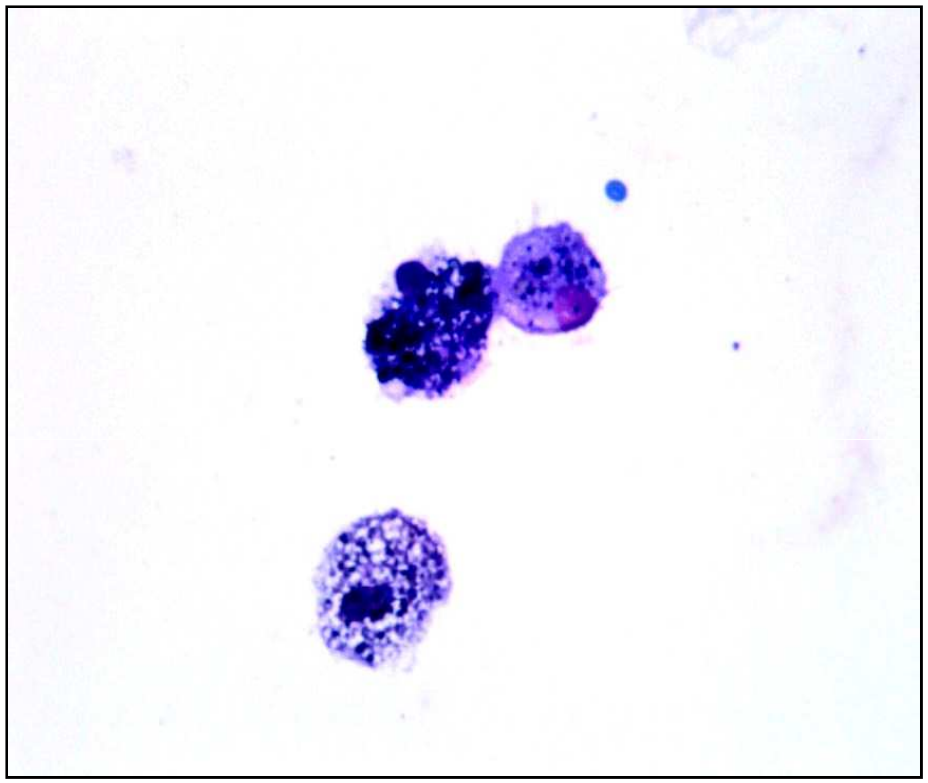

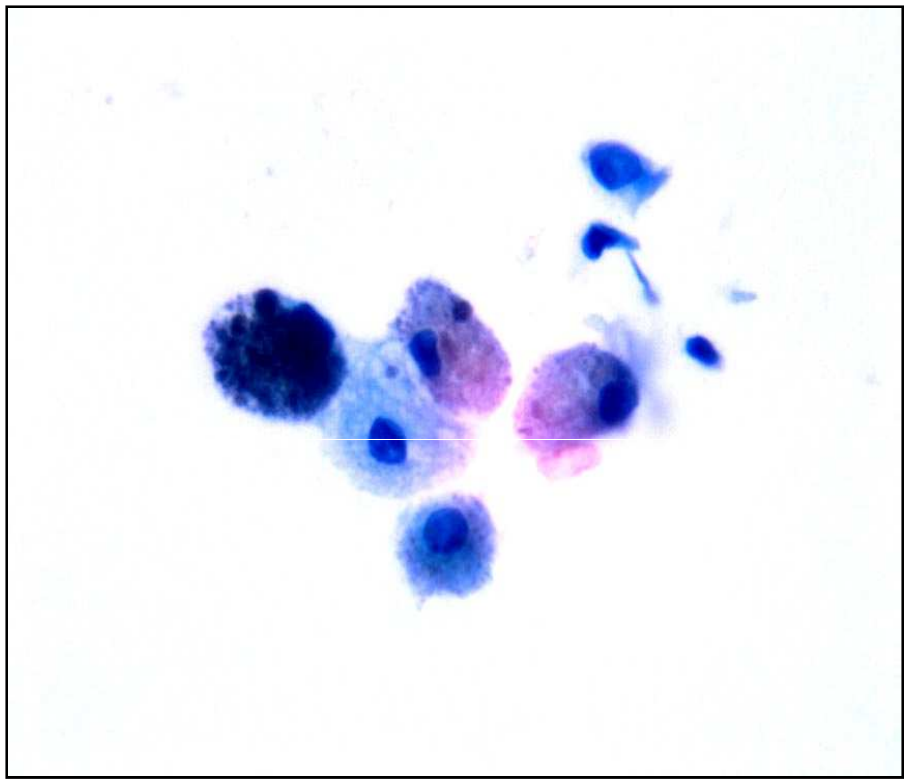

Cytology Diagnosis: Lymphocytes and few macrophages in a background of "colloid" type material. Rule-out metastatic papillary thyroid carcinoma

35-year-old woman with left lateral neck cystic mass

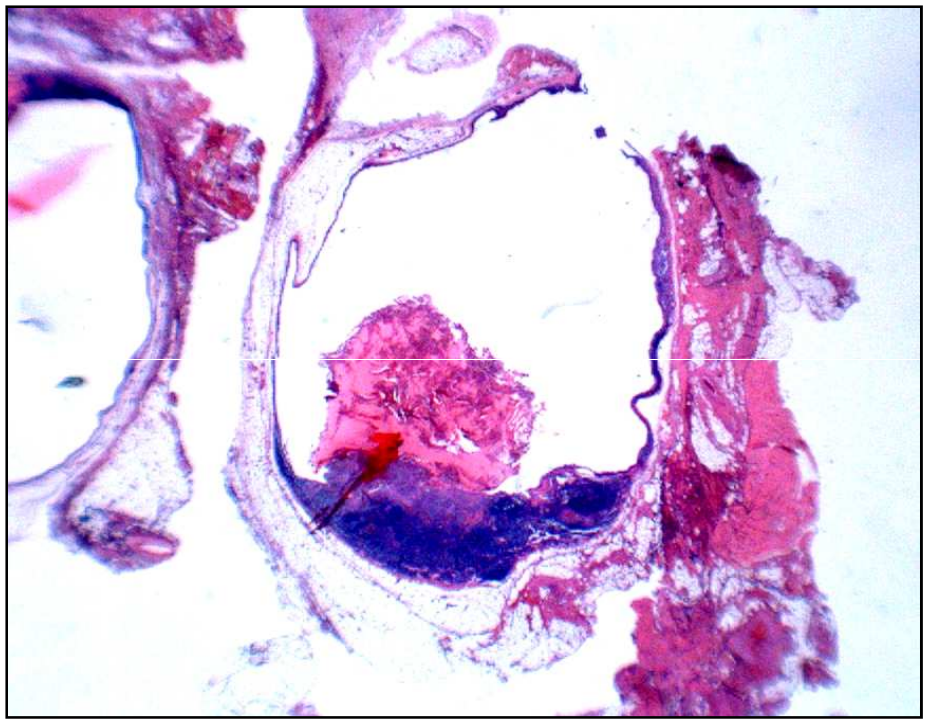

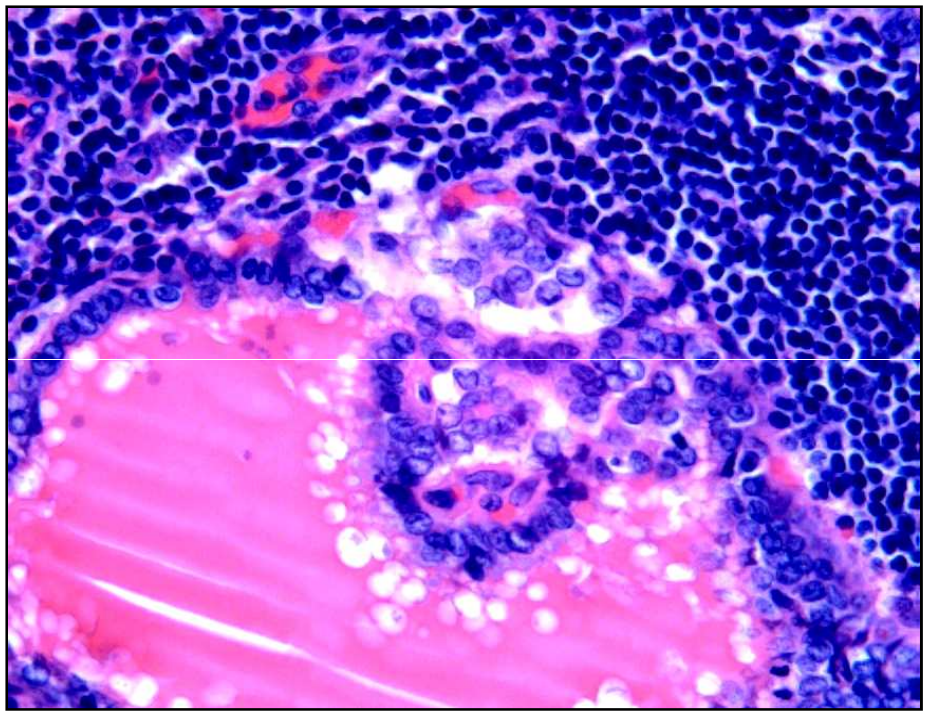

Histology Diagnosis: Metastatic papillary thyroid carcinoma;
TTF-1 and Thyroglobulin positive

35-year-old woman with left lateral neck cystic mass
Total Thyroidectomy

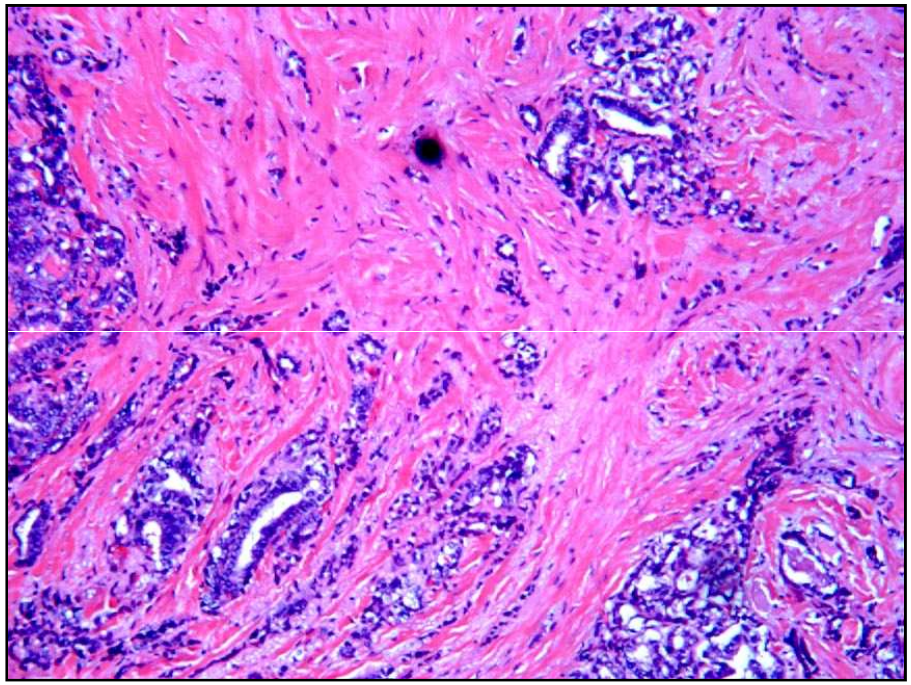

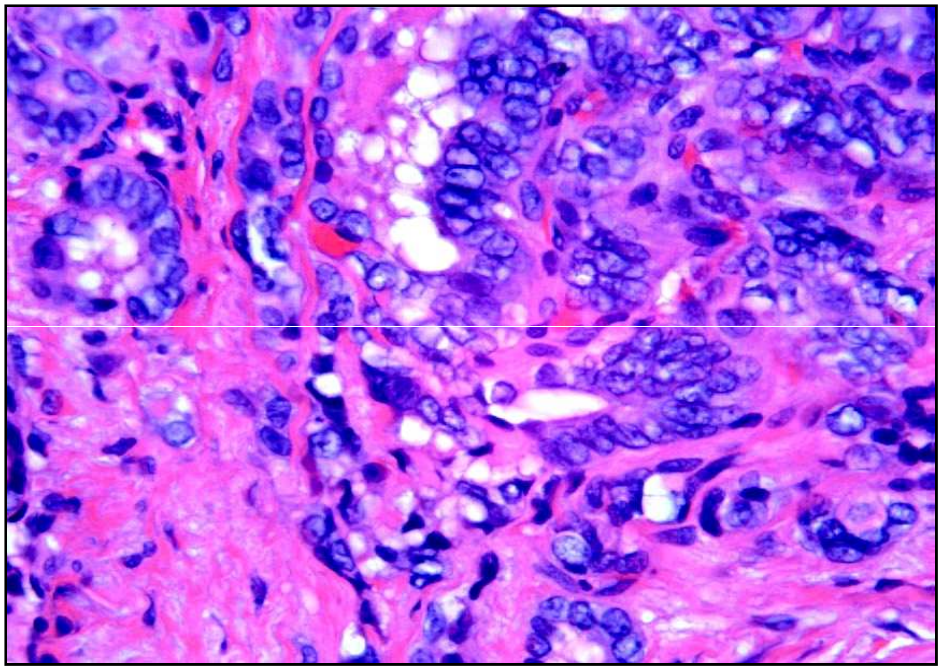

Histology Diagnosis: Papillary microcarcinoma 0.9 cm

Cystic neck mass with no history

- Lymphocytes
- Colloid like background material
- Macrophages
- No epithelial cells
- Suspicious for thyroid cancer metastasis
- What next?

Cystic neck mass suspicious for thyroid carcinoma metastasis

- On-site evaluation – suspicious
  - Ultrasound examination of thyroid
  - Aspiration of suspicious thyroid nodule
  - Thyroglobulin level assessment of the aspirate

- No on-site evaluation
  - Recommend ultrasound evaluation of thyroid
  - Repeat FNA with thyroglobulin level assessment of the aspirate

Thyroglobulin measurement in the lymph node aspirates of patients with PTC

	TG Levels ≥10 ng/ml			***TG Levels ≤10 ng/ml***		
Cytologic-DX						
	PTC	Other CA	No F/U	PTC	Other CA	No F/U
PTC (n=39)	25	0	3	10*	1**	0
NTS (n=35)	5	0	0	0	0	30
NDX(n=23)	3	0	1	0	0	19
ATYP (n=15)	9	0	0	4*	0	1
OTHER (n=3)	0	1***	0	0	1****	0

DX = Diagnosis, TG = Thyroglobulin, F/U = surgical pathology follow- up, PTC = Papillary thyroid carcinoma, CA = Carcinoma, NTS = No tumor seen, NDX = Non-diagnostic, ATYP = Atypical/Suspicious, * = includes cases of tall cell variant of papillary carcinoma, ** = metastatic well-differentiated follicular derived carcinoma *** = poorly differentiated carcinoma, **** = carcinoma not otherwise specified.

32-year-old man with bilateral parotid gland masses

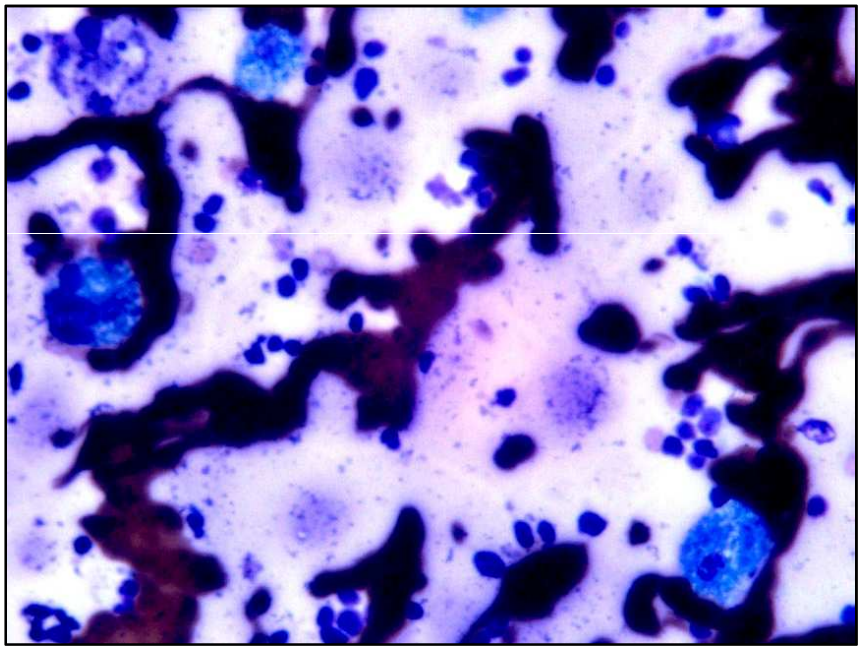

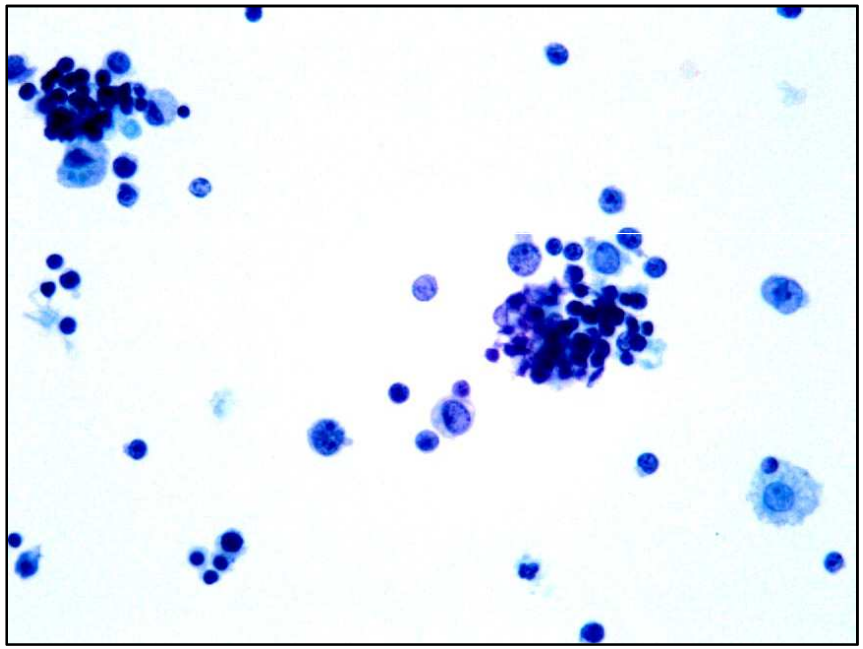

32-year-old man with bilateral parotid gland masses

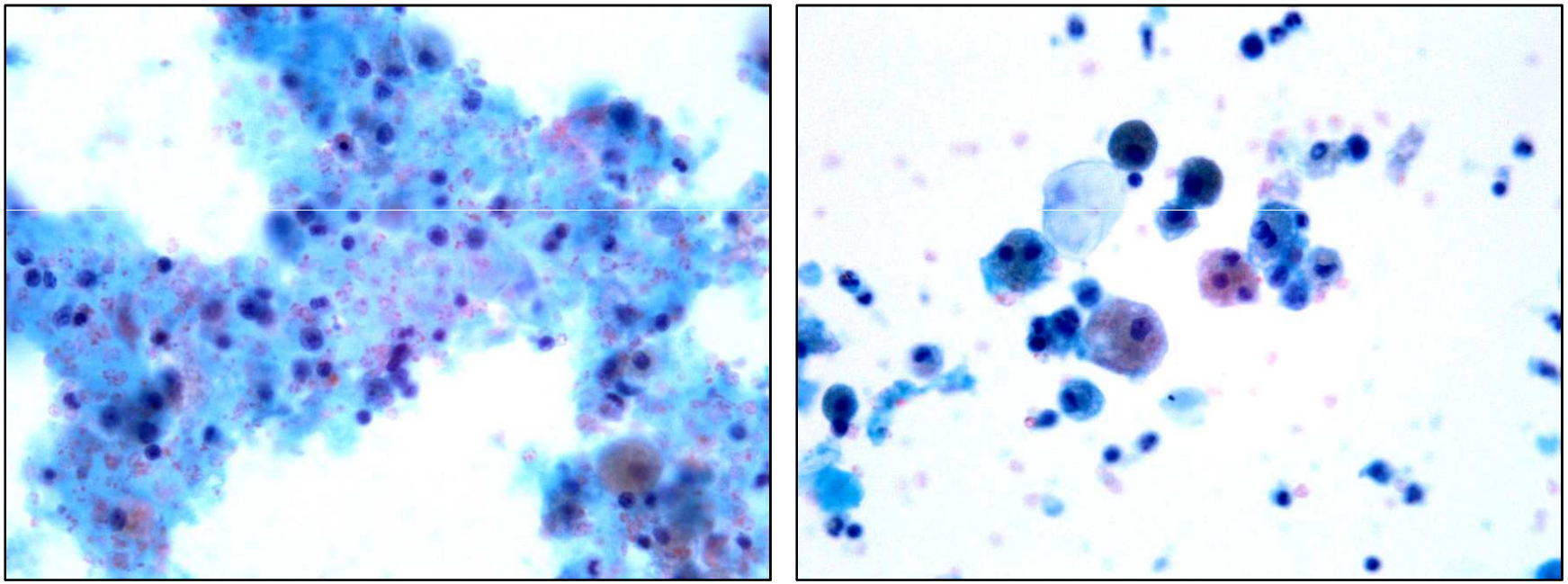

32-year-old man with bilateral parotid gland masses- HIV +

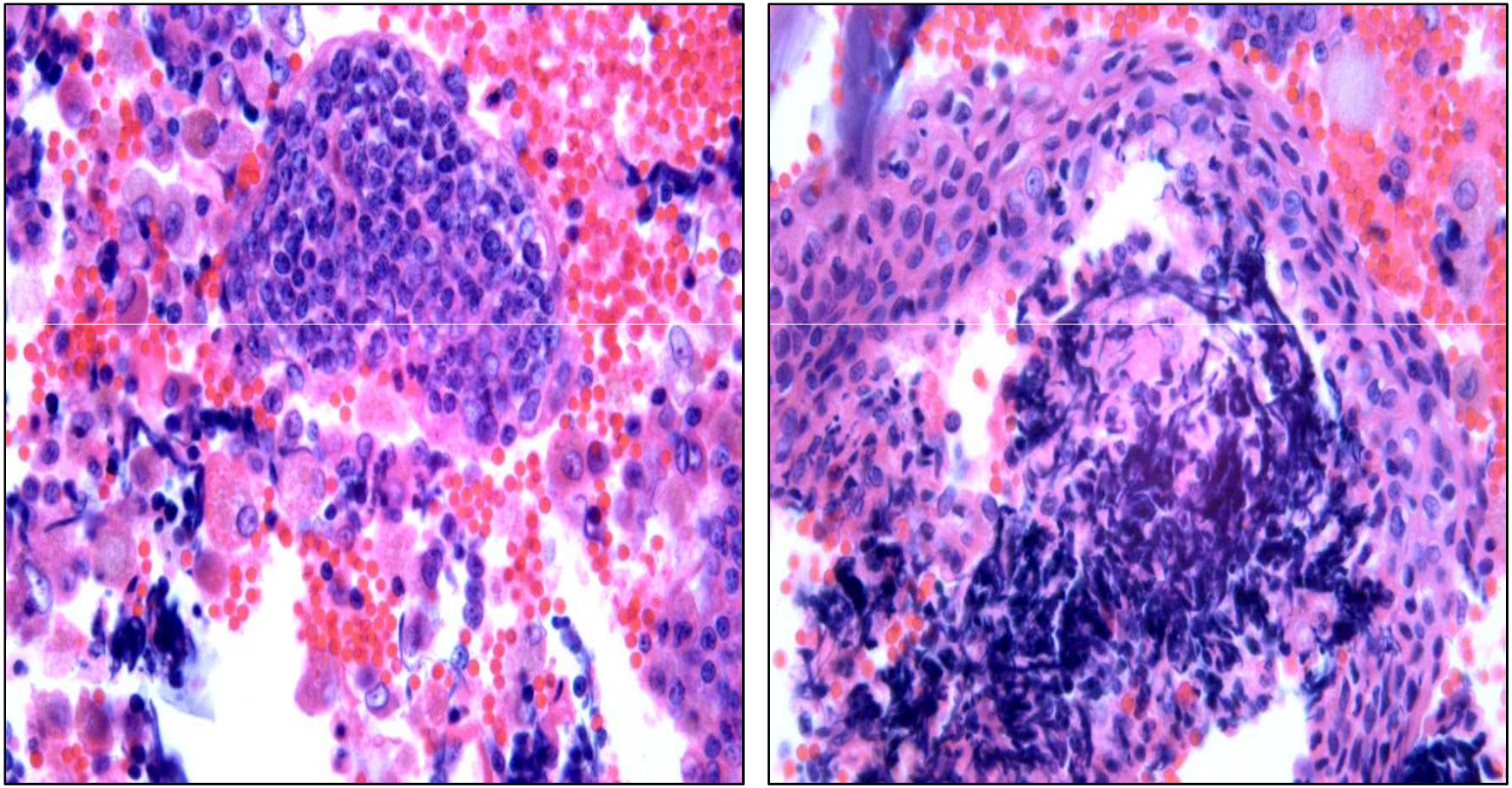

Lymphoepithelial Cyst

Warthin's Tumor

Primarily occurs within parotid gland

- Second most common salivary gland neoplasm – 5-10%
- Believed to originate from salivary duct remnants entrapped within glandular lymphoid tissue

Clinical features:

- 50-79 year-old
- Common in men
- Bilateral

Warthin's Tumor

Cytology

Mixed population of lymphocytes

Sheets of oncocytes

Background debris (grossly mobile oil consistency)

Warthin's Tumor Cytology

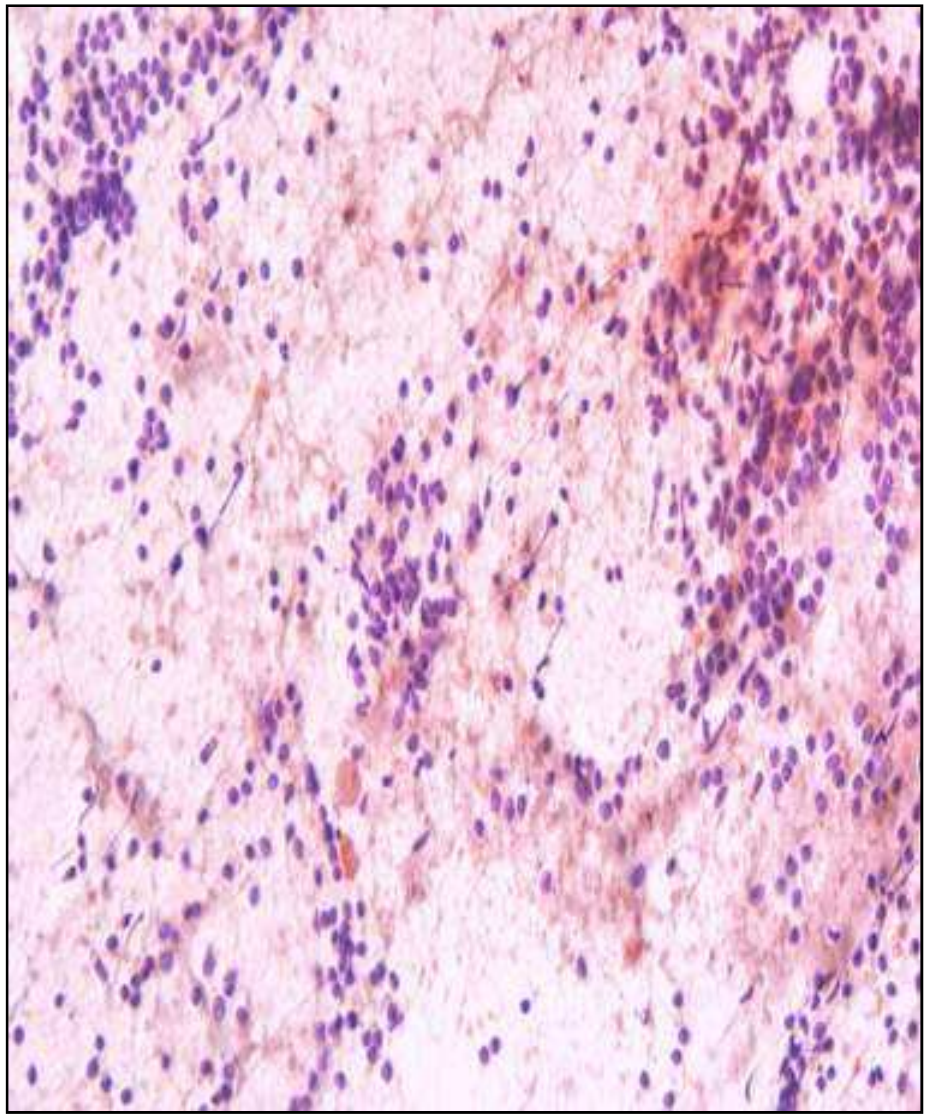

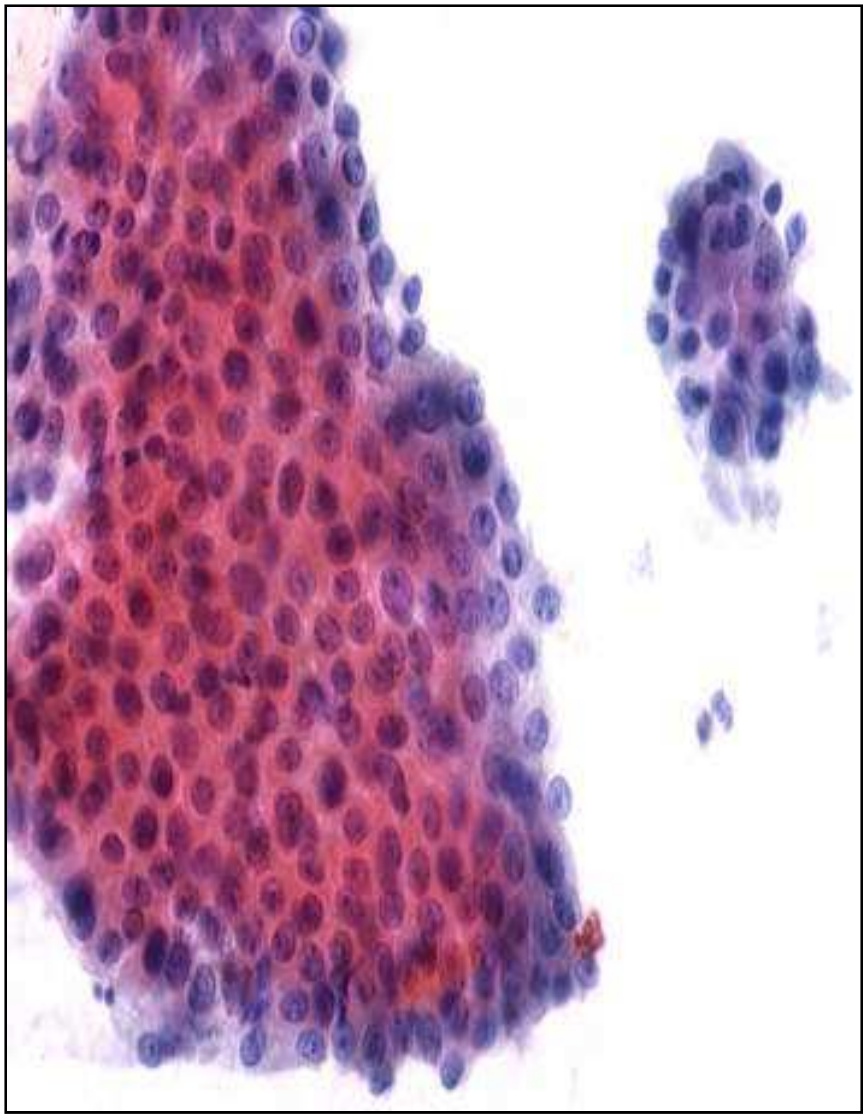

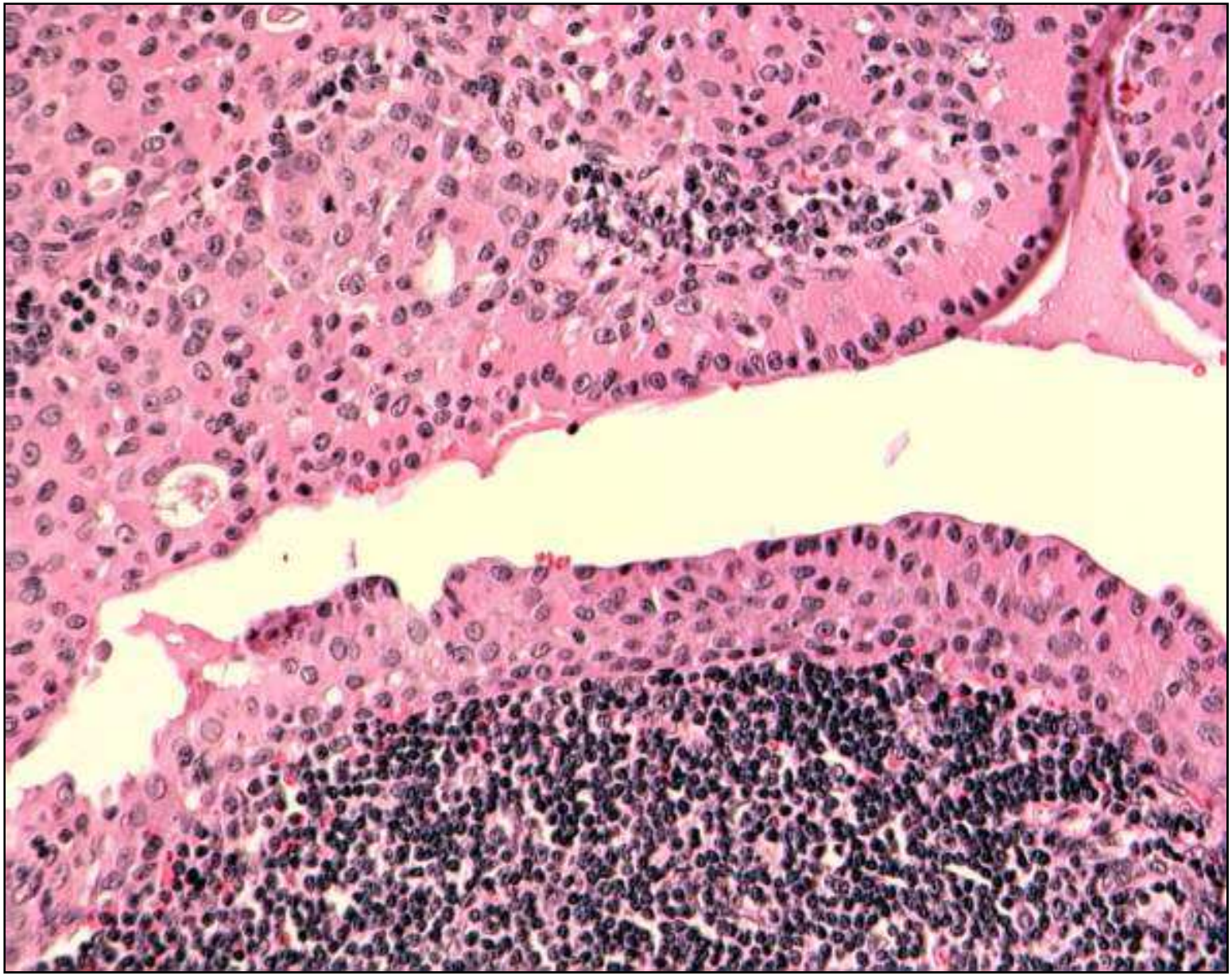

Oncocytic Mucoepidermoid Carcinoma

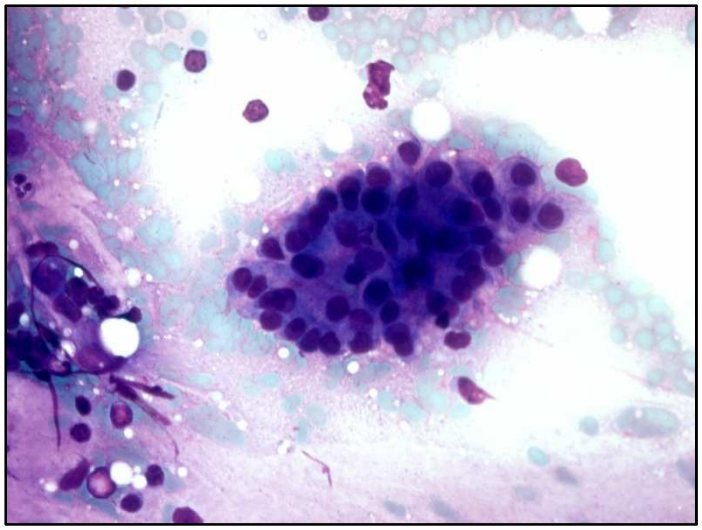

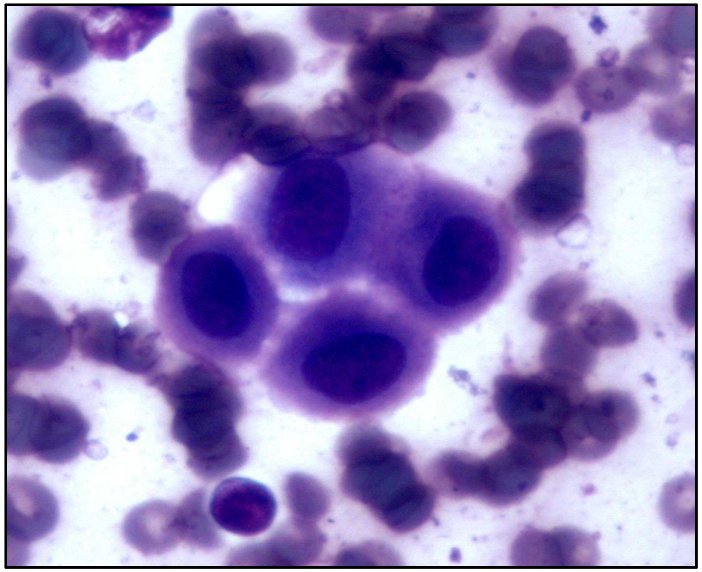

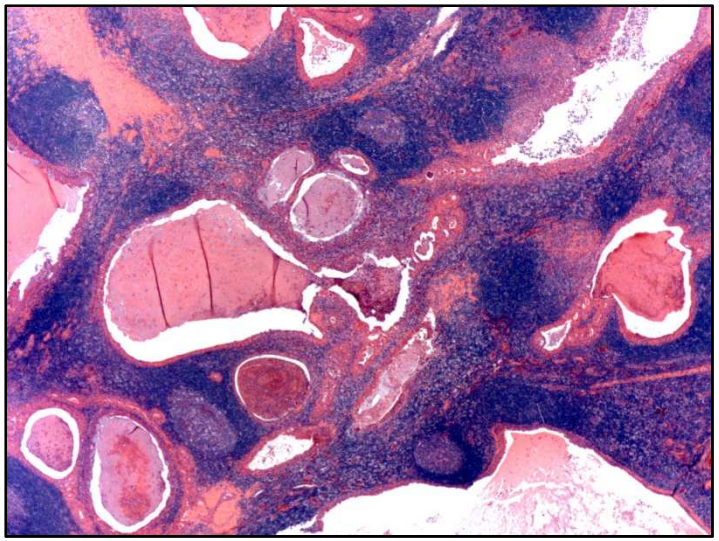

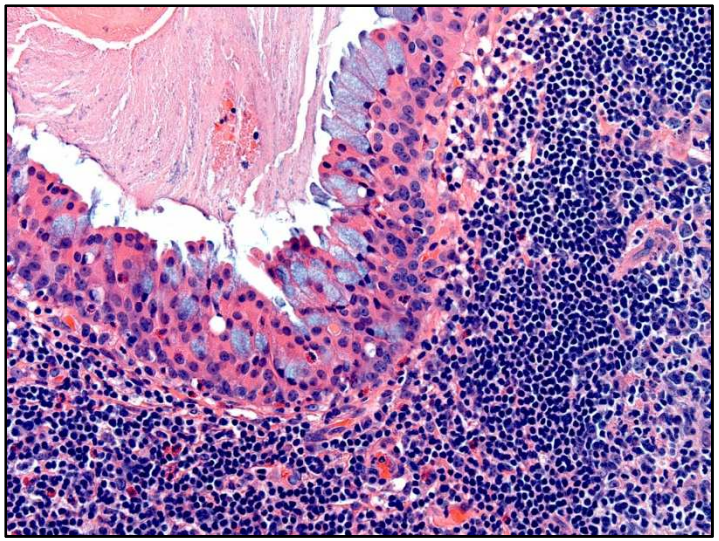

Overlapping Cytologic Features

- Lymphocytes
  - Chai et al *(Diag Cytopathol 1997)*
  - 61 cases with prominent lymphoid component
    - Warthins 33 cases
      - Warthins-31, Benign cyst-1, SCCA-1
    - Other epithelial malignancies 6 cases
      - Oncocytoma; Pleomorphic adenoma, ACC
    - Lymphomas 12 cases
    - Benign 10

Overlapping Cytologic Features

- *Lymphocytes*
  - Intraparotid LN
  - Lymphoepithelial cyst
  - Chronic Sialadenitis
  - Warthin's
  - Acinic cell carcinoma
  - Mucoepidermoid Carcinoma
  - Lymphoma

Approach to cystic neck lesion

Background – Mucoid

- Histiocytes & lymphocytes
  - Mucus retention cyst
- Salivary gland
    - Chronic sialadenitis
    - Sialolithiasis
    - Mucoepidermoid carcinoma
    - Myxoid and chondroid fragments – Pleomorphic adenoma – rare
- Atypical cells
    - Malignancy – Mets vs. primary

Approach to cystic neck lesion
Background – watery proteinaceous fluid

- **Lymphocytic infiltrate & few epithelial cells**
  - Lymphoepithelial cyst
  - Thyroglossal duct cyst – midline location
- **Salivary gland**
  - Lymphocytes and oncocytes
    - Warthin's tumor
  - Atypical keratinized cells
    - Squamous cell carcinoma
    - Metaplasia in benign tumor – history of previous FNA
- **Keratinized cells**
  - Atypical – Squamous cell carcinoma
  - Branchial cleft cyst

Approach to cystic neck lesion

- Benign vs. malignant squamous cystic lesion
  - Background – inflammation?
  - Necrotic debris
  - Cellularity – increased in SCC?
  - Abnormal keratinization / Dyskeratosis
  - Nuclear atypia

Approach to cystic neck lesion

- Cystic mass suspicious for thyroid cancer
  - Recommend ultrasound of thyroid and aspiration of suspicious nodules
  - TTF-1 and thyroglobulin (should do both) if enough cells
  - Thyroglobulin assessment of FNA specimen

CASE HISTORY

43 yo female with history of nasal septal perforation and Bechet's syndrome. A functional endoscopic surgery (FESS) was performed

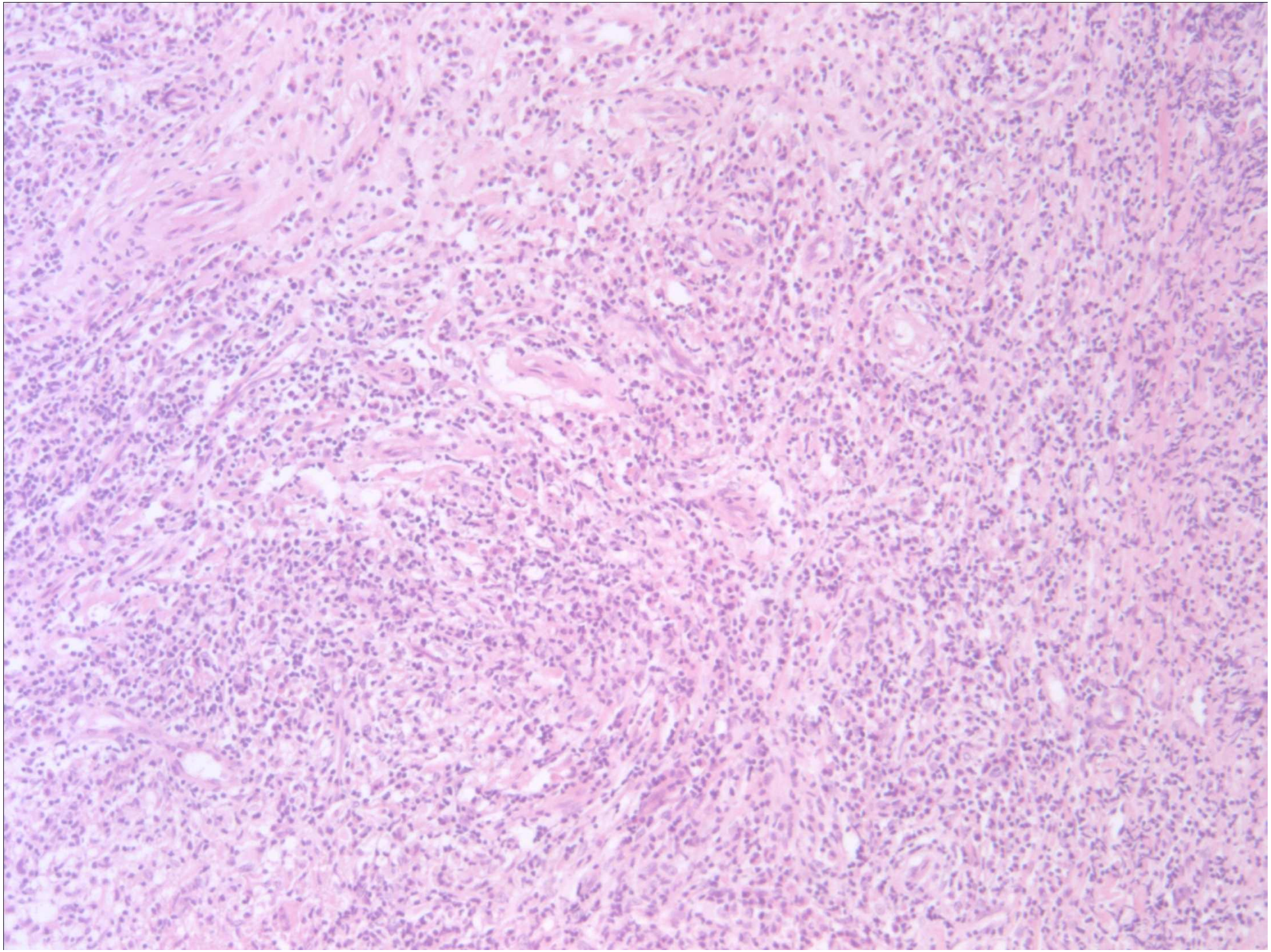

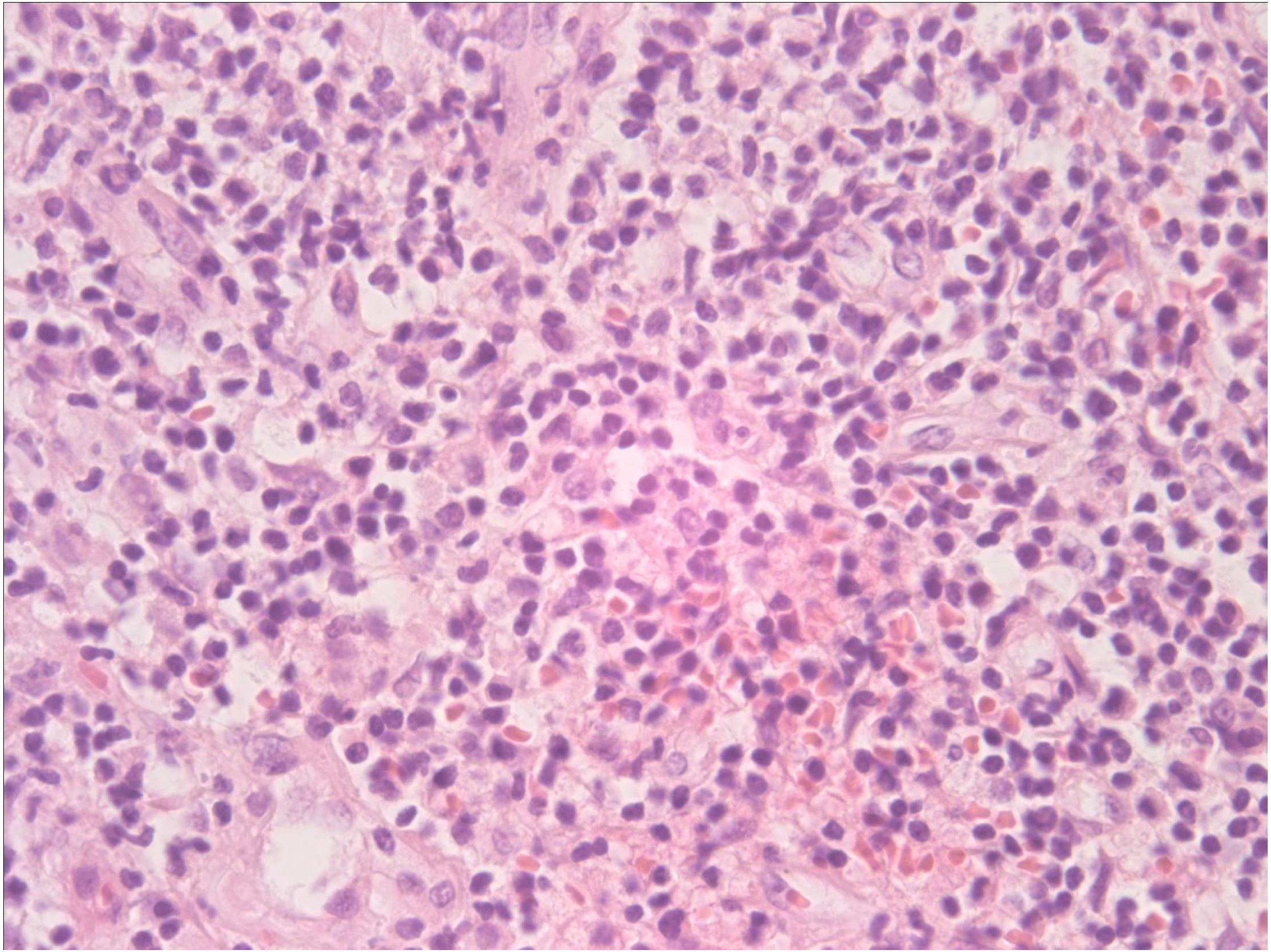

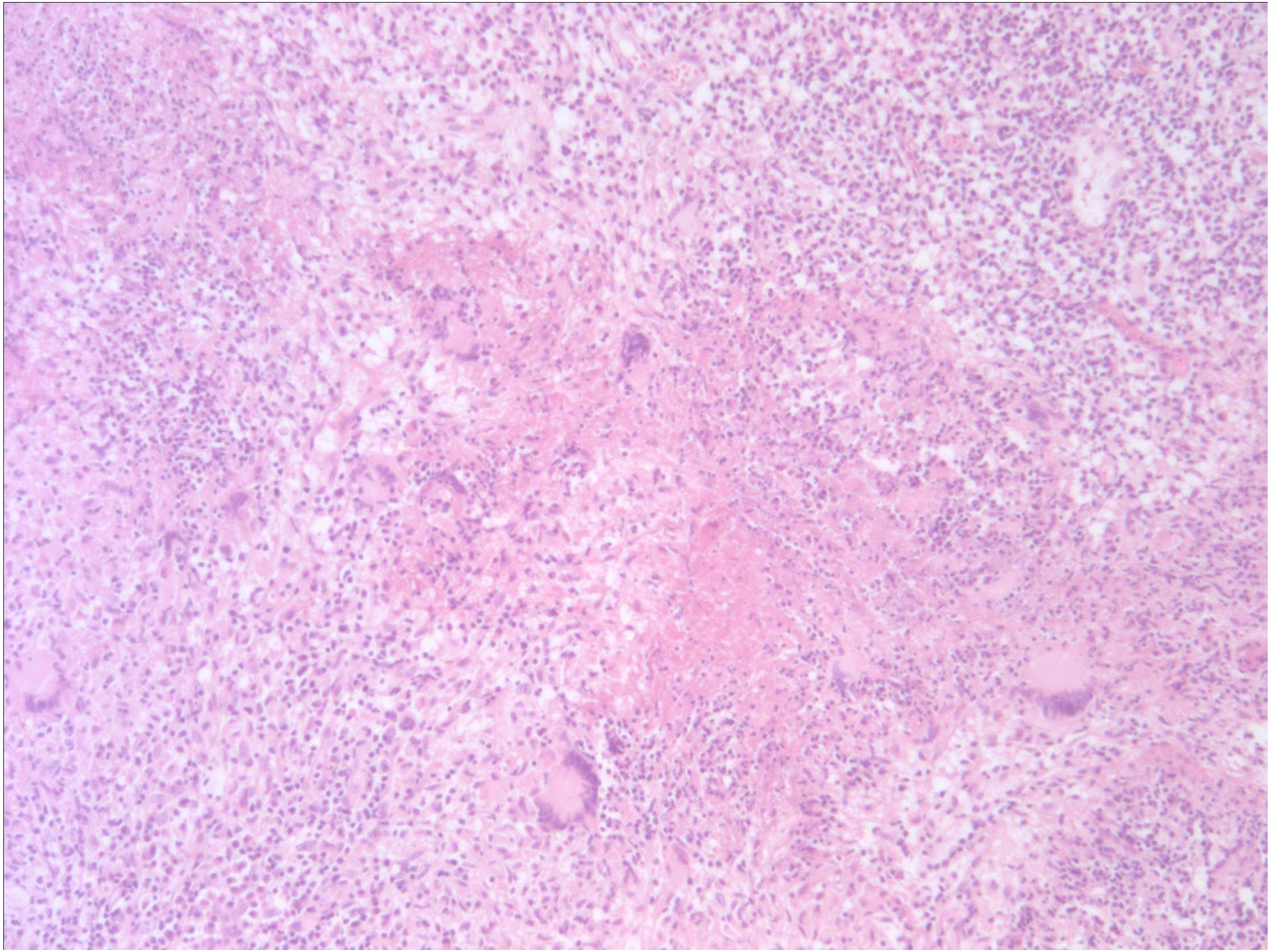

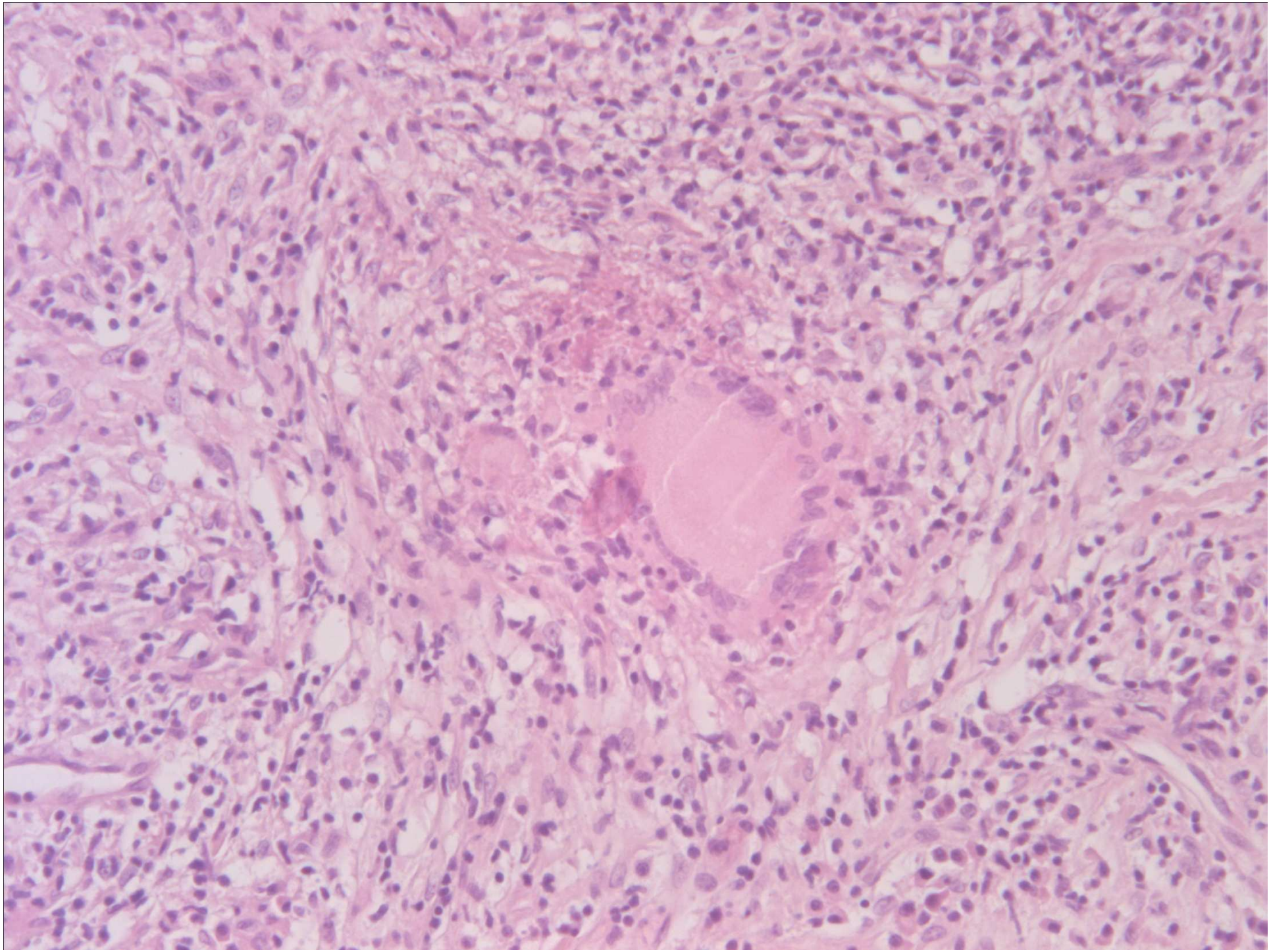

Necrotizing Sinonasal Diseases: DDX

- Infection: Bacteria, Mycobacteria, Fungus, Virus, Protozoa
- Vasculitis: Wegener's, Churg Strauss, Microscopic polyangiitis
- Neoplastic: Extranodal NK/T-cell lymphoma, other
- Drug abuse

Approach to Necrotizing Sinonasal Lesions

- Is it infectious?
  - Histology: type of inflammation, granulomas
  - Special stains: gram, Grocott (GMS), AFB, Fite
- Is it neoplastic?
  - Types of cells; Atypical lymphoid cells,density of cells; EBER studies
- Is it autoimmune?
  - Vasculitis, serologies, clinical history
- Is it self-induced?
  - Drug abuse history?

Sinonasal Infections

- Fungus
  - Aspergillus, Zygomyces, other
- Bacterial
  - Klebsiella (Rhinoscleroma)
  - Pseudomonas
  - Syphilis
- Mycobacterial
  - Leprosy
  - TB
- Protozoa
  - Leishmaniasis
  - Rhinosporidiosis

Fungal Rhinosinusitis

- A variety of disease processes involving the sinonasal tract caused by or associated with the presence of a variety of fungal pathogens.
- Seen commonly worldwide
- A common cause of chronic rhinosinusitis resulting billions of dollars in health care costs annually.

2009 ISHAM Classification: Fungal Rhinosinusitis: Terminology

- Invasive
  - Acute invasive (fulminant)
  - Granulomatous invasive
  - Chronic Invasive
- Non-invasive
  - Localized fungal colonization of nasal or paranasal sinus mucosa (Saprophytic fungal infestation)
  - Fungus Ball
  - AFRS

Acute Invasive Fungal Rhinosinusitis

- AKA fulminant/necrotizing fungal rhinosinusitis
- Symptoms < 4 weeks duration
- Aggressive, tissue and vascular invasive fungal disease.
- Usually immunocompromised
- Small lesion – rapidly progresses to involve sinus/face/orbit
- Zygomycetes/Aspergillus
- Wide debridement/intravenous antifungal agents.
- Poor prognosis

Inferior Frontal Lobes

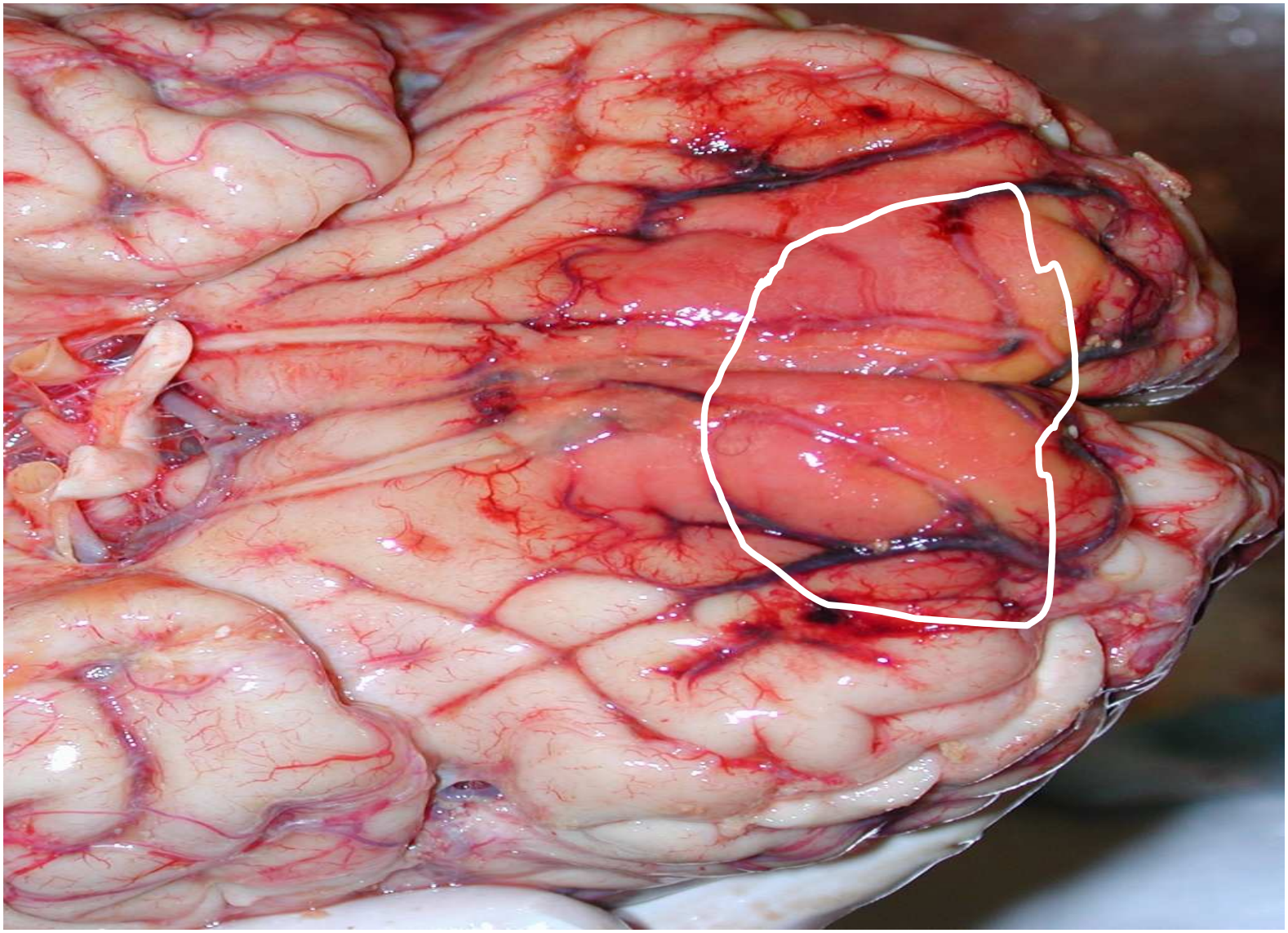

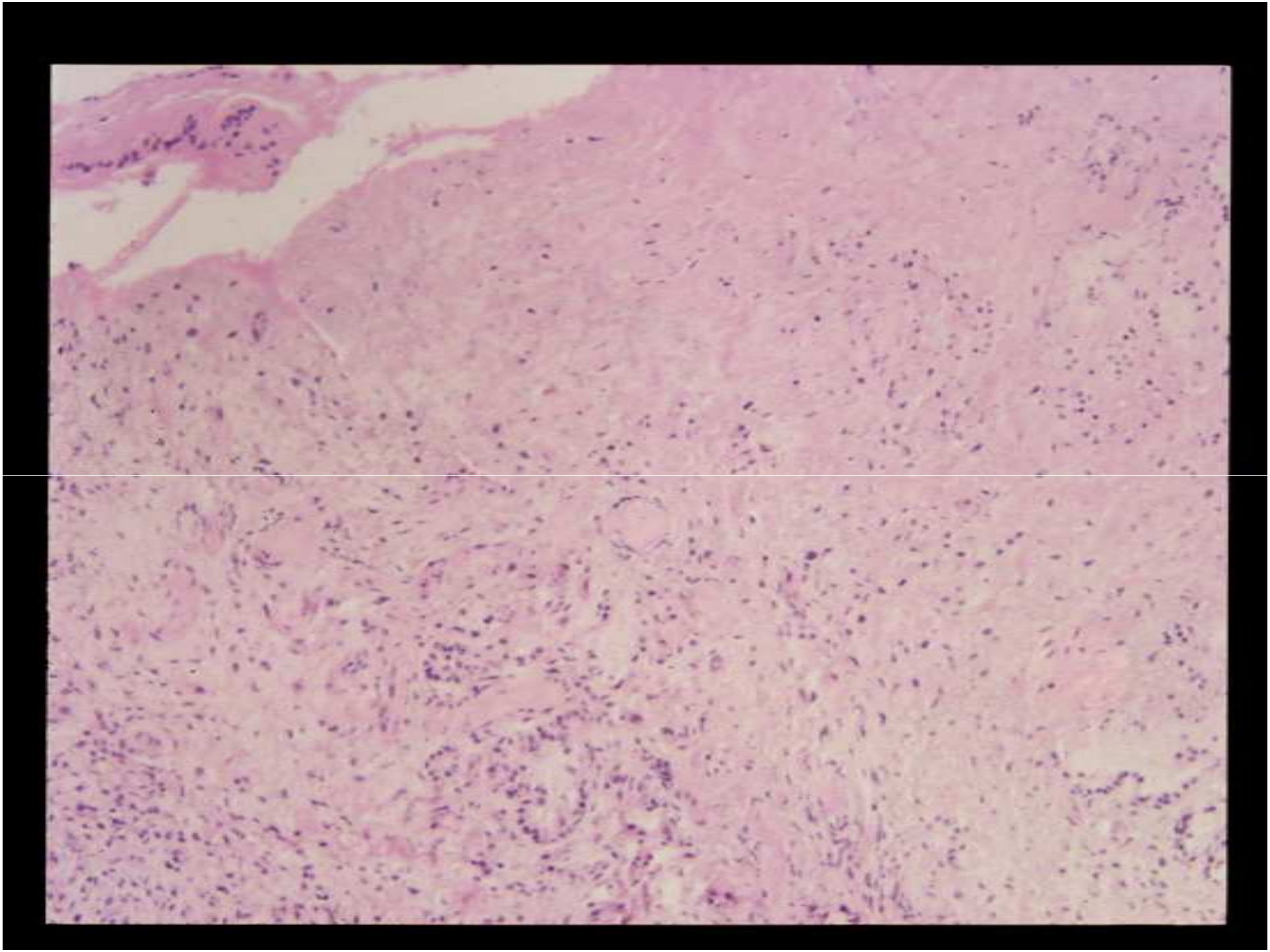

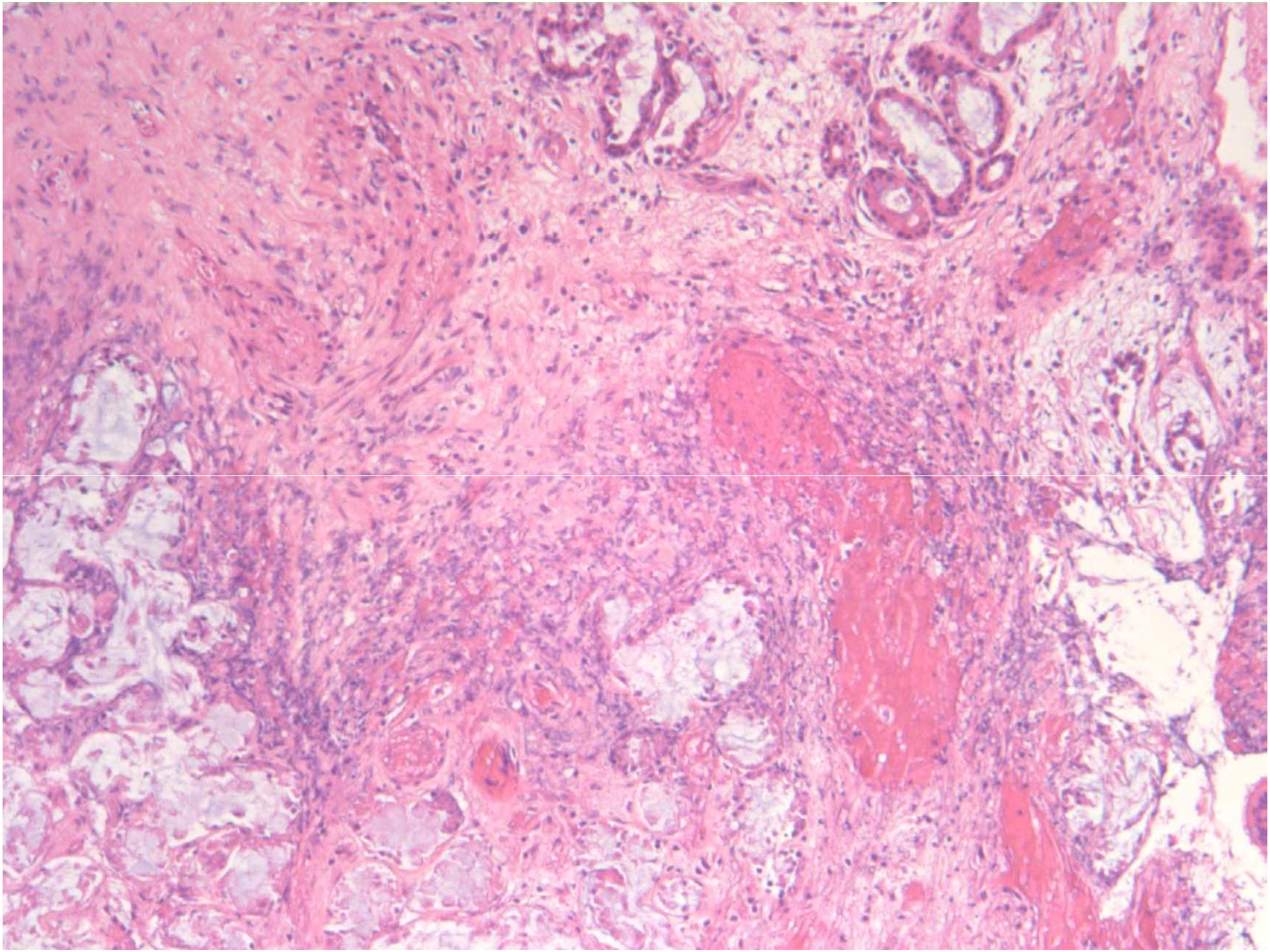

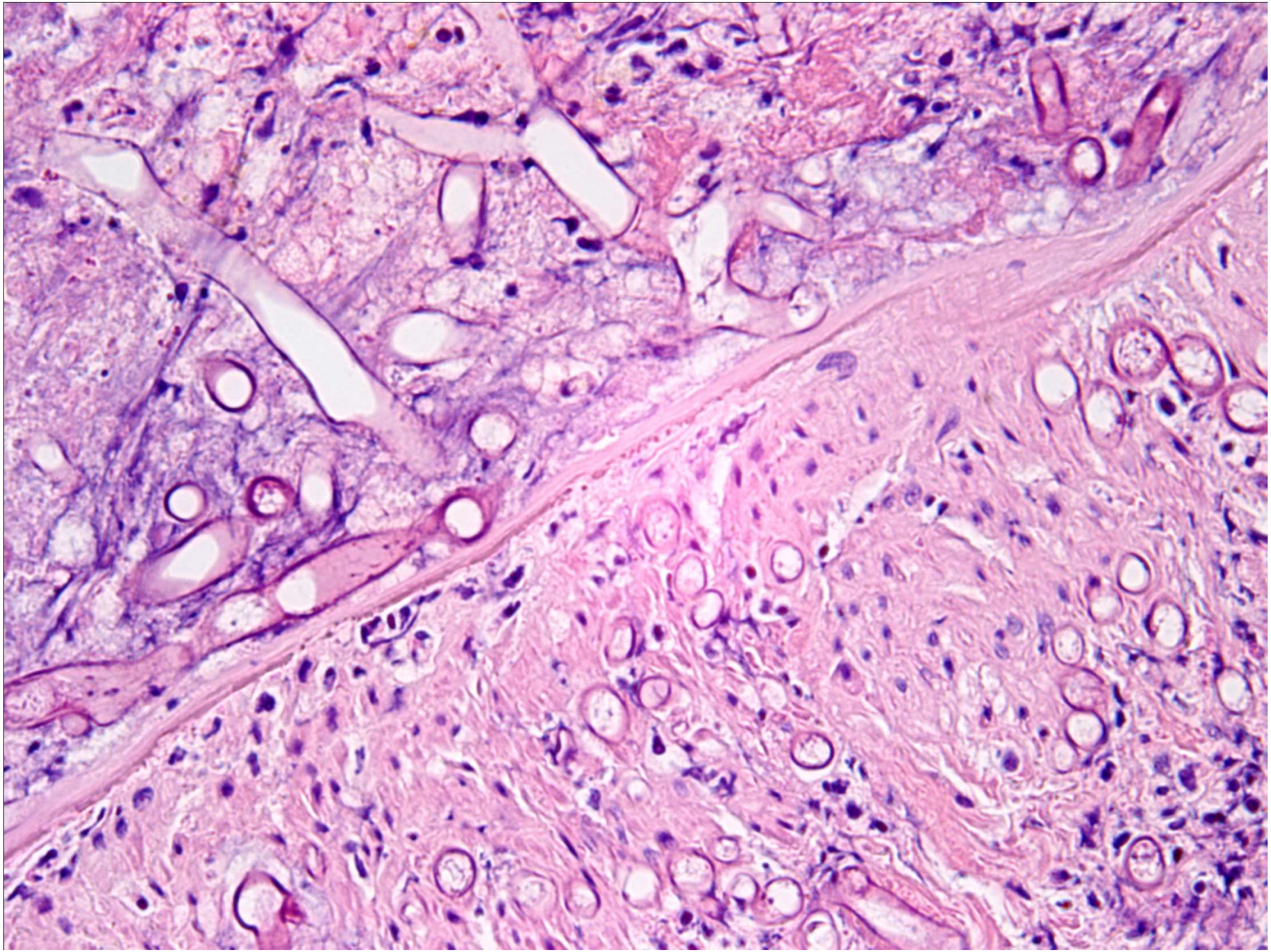

Can we do anything if cultures are negative (>30% of the time) or were not performed at the time of surgery but we still see fungus?

ISH or IHC for Aspergillus sp.

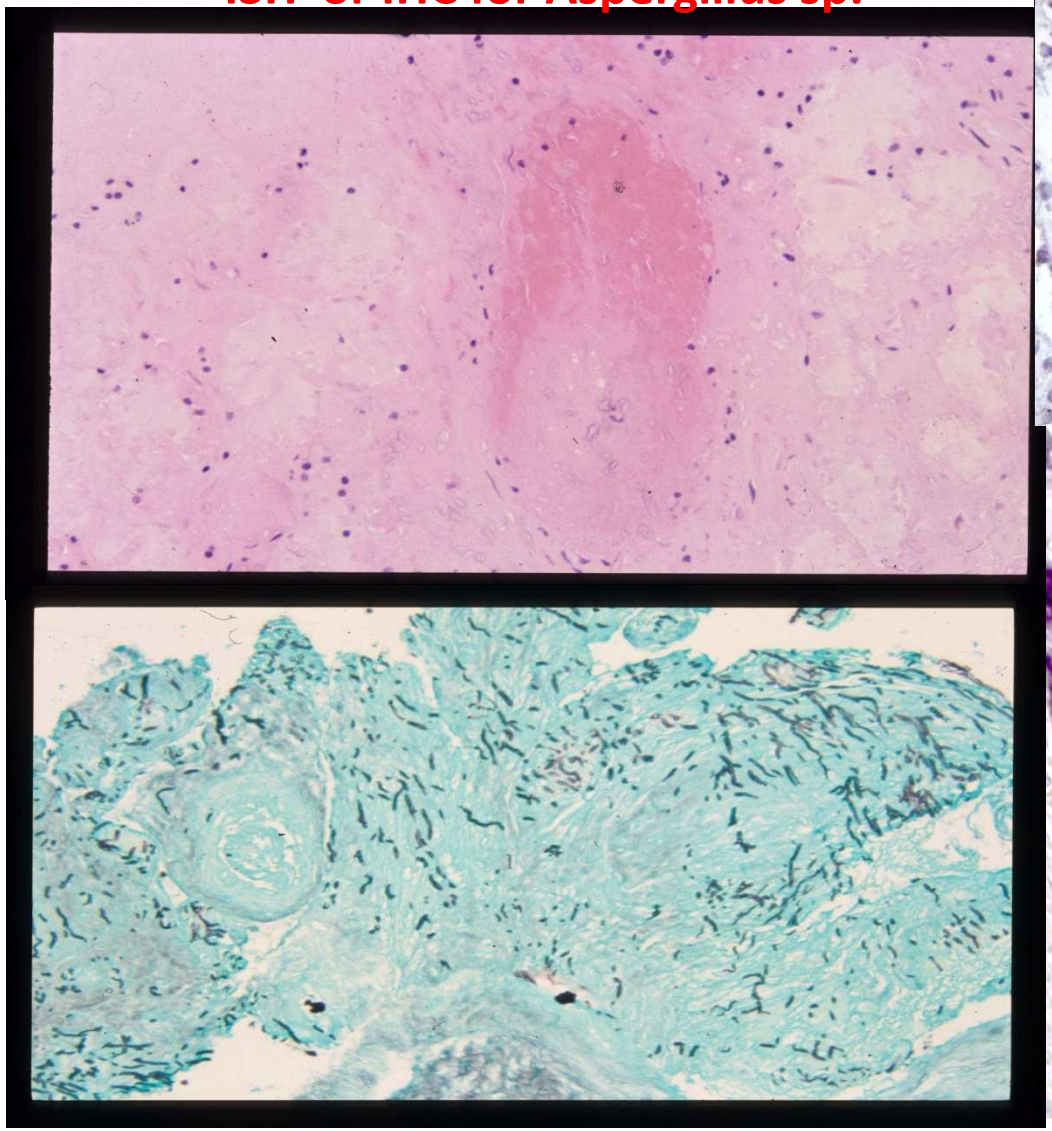

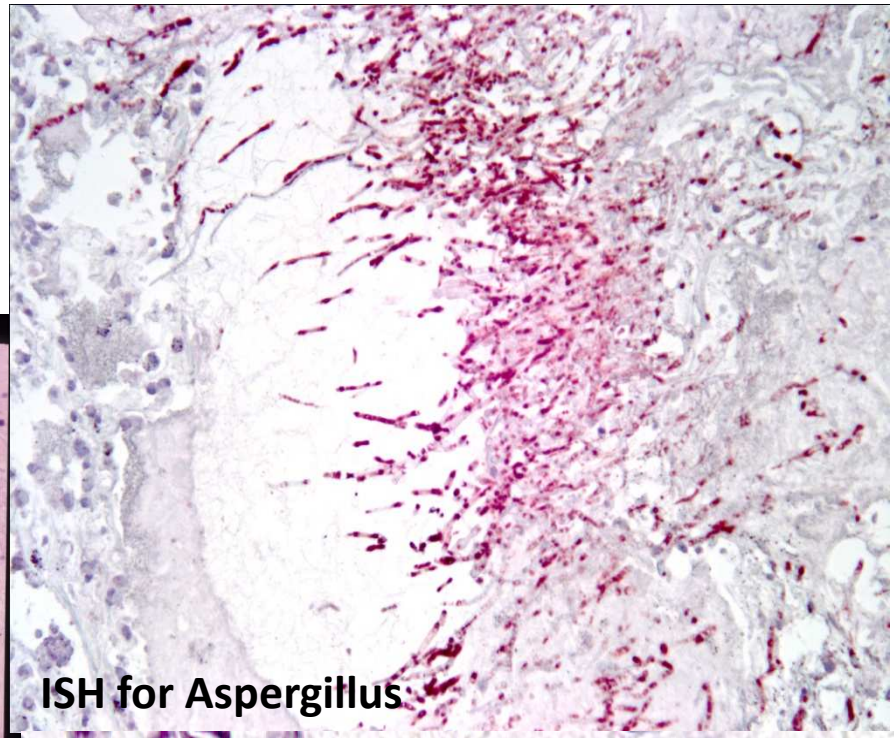

ISH for Aspergillus

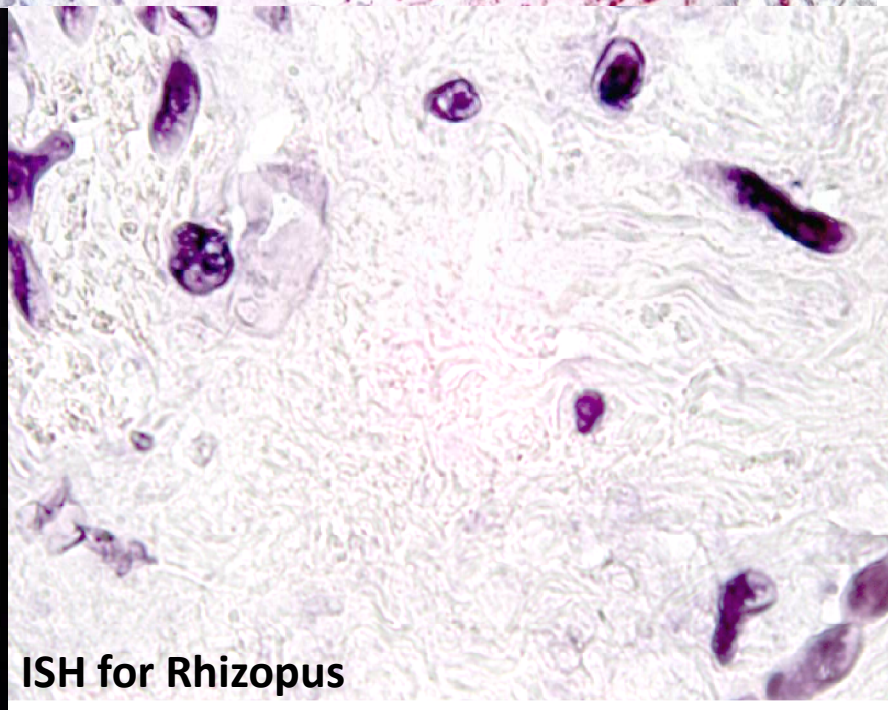

ISH for Rhizopus

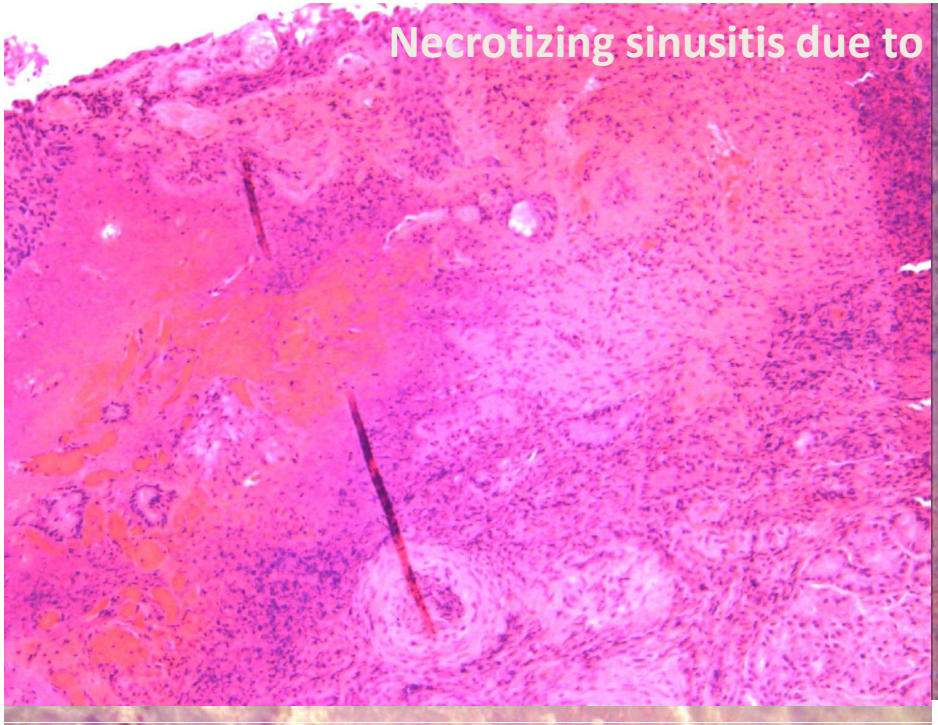

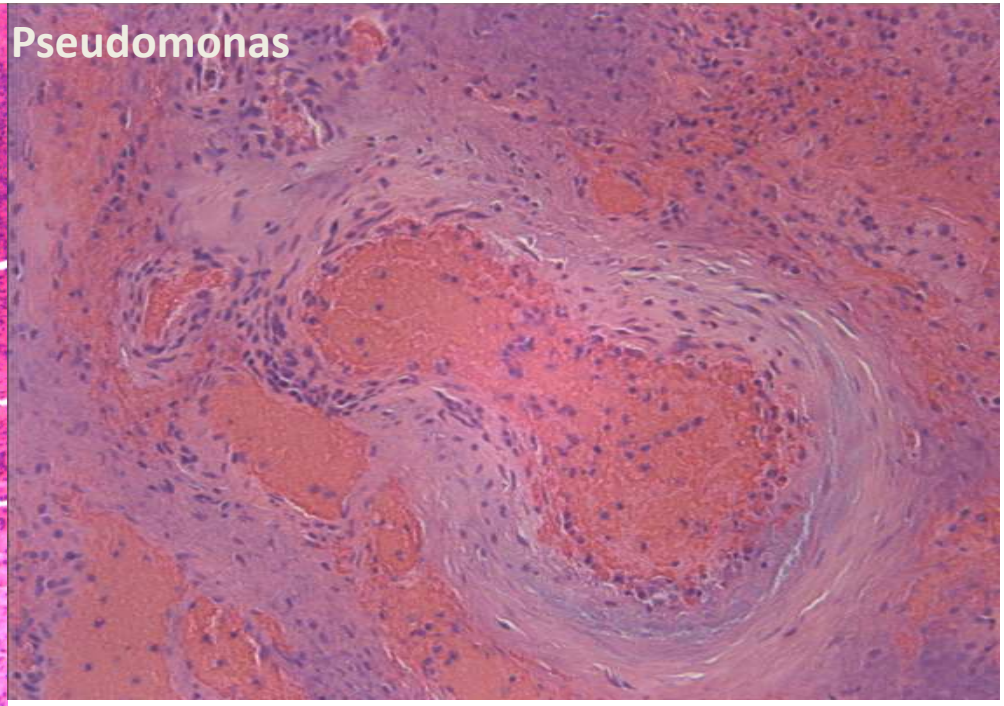

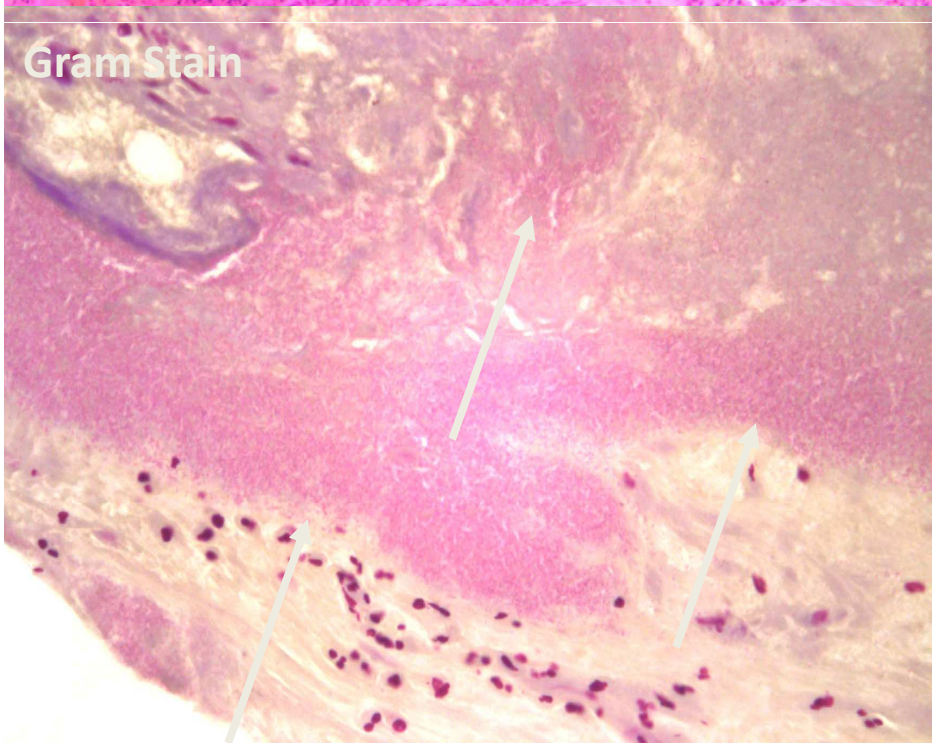

Bacterial infections can produce picture similar to fungal infections

Chronic Invasive Fungal Sinusitis

- **Chronic Invasive**
  - **Rare**
  - **Seen in diabetics.**
  - **Usually starts in ethmoid/extends to orbit**
  - **Invasion of fungus into sinonasal mucosa with associated granulomas and giant cells and necrosis**
  - **Tx: Surgery/IV antifungals**
  - **Prognosis: poor**

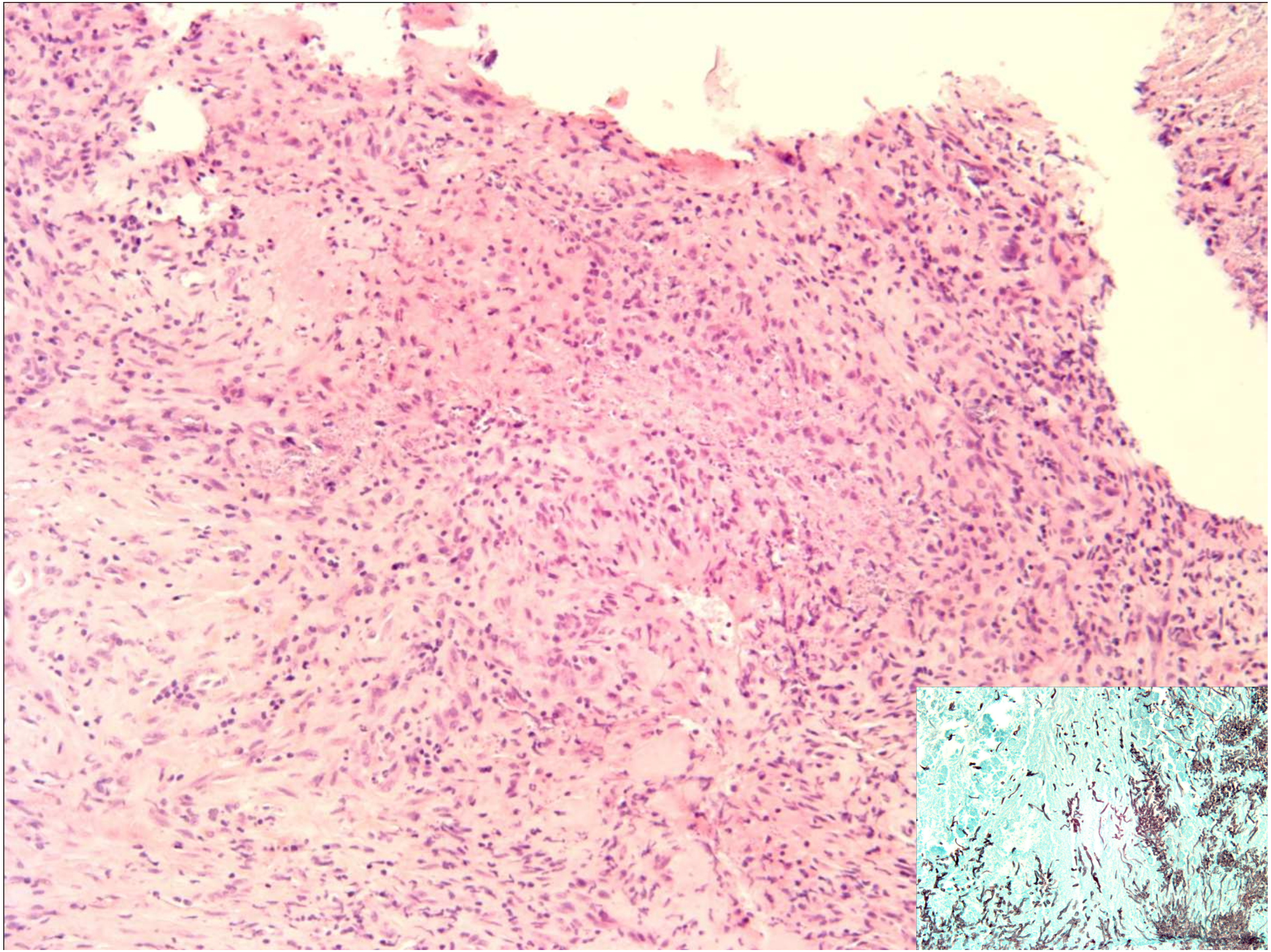

Chronic Granulomatous Fungal Sinusitis

- **Seen in immunocompetent patients**
- **Indolent behavior**
- **Good prognosis**
- **Paranasal sinuses most common**
- **Endemic in Sudan**
- ***A. flavus* most common organism**
- **Difficult to treat**

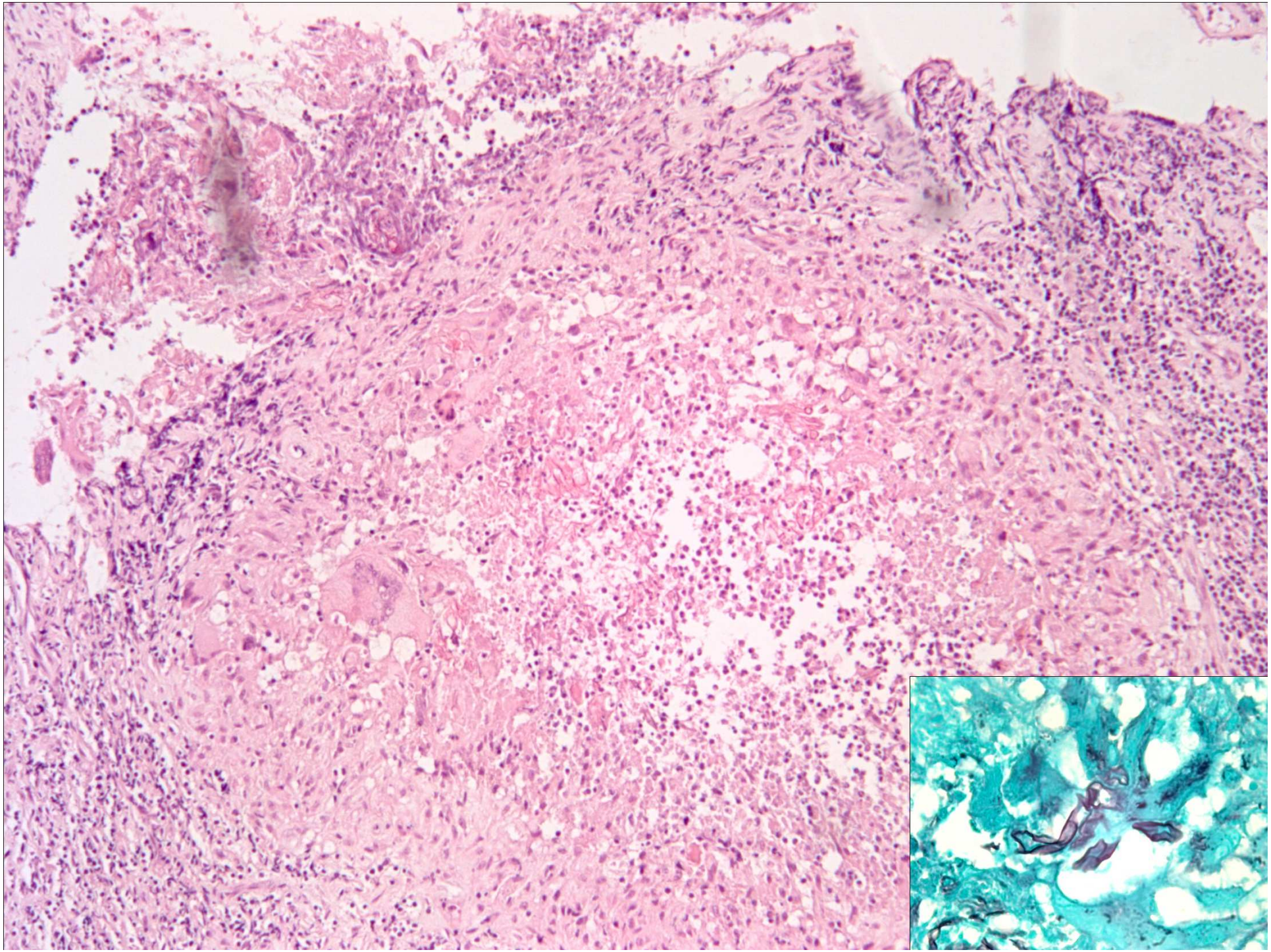

Rhinoscleroma

- Chronic granulomatous disease caused by *Klebsiella rhinoscleromatis*.
- M=F; <30 yo; Low SEC
  - Poor hygiene
  - Poor living conditions
  - Malnutrition
  - Genetic component
  - Endemic in Egypt, Central and South America, North and Central Africa, Eastern Europe
- Affects nasal cavity, paranasal sinuses, orbit, larynx, middle ear, tracheobronchial tree

Rhinoscleroma (*Klebsiella rhinoscleromatosis*

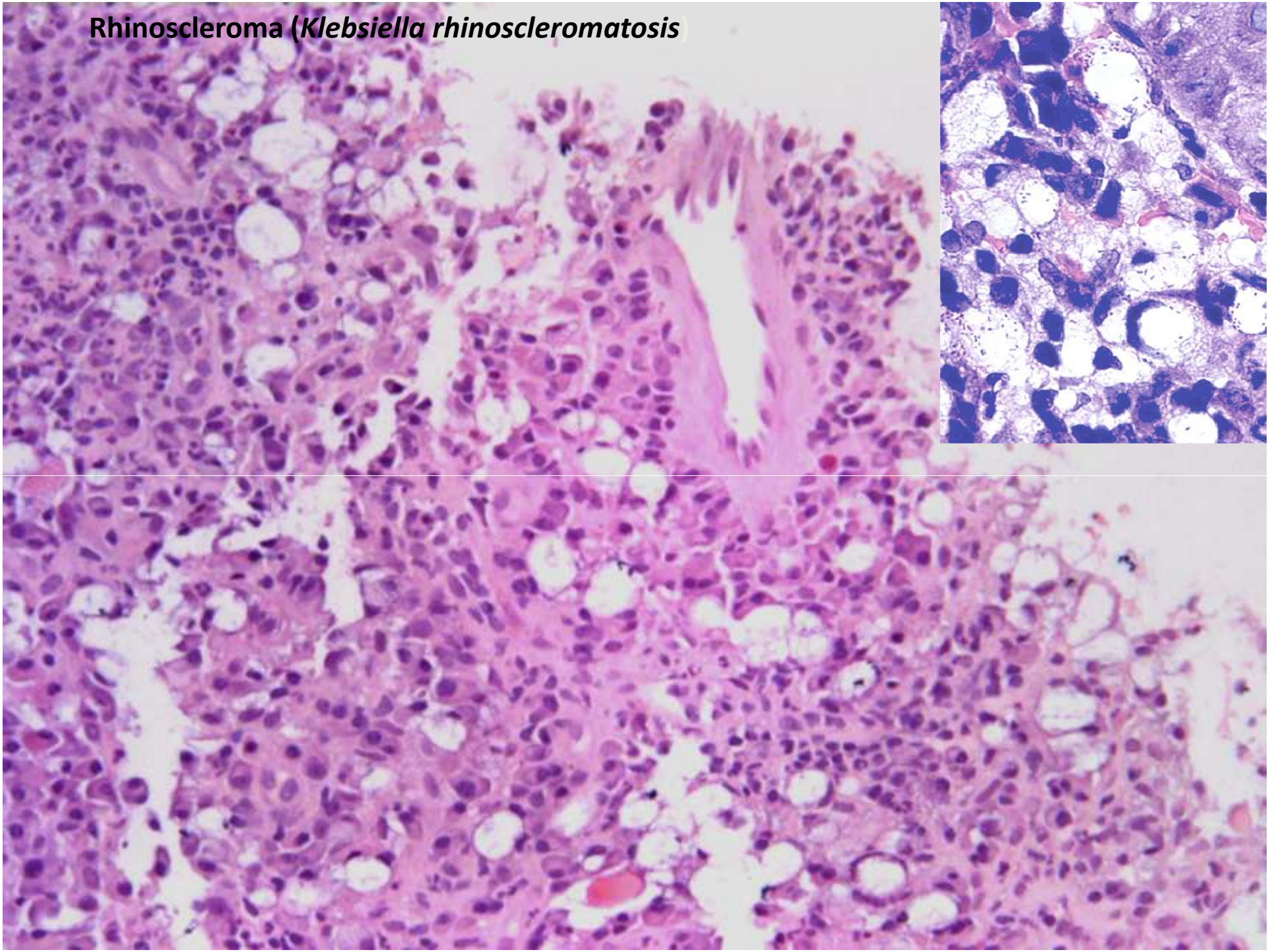

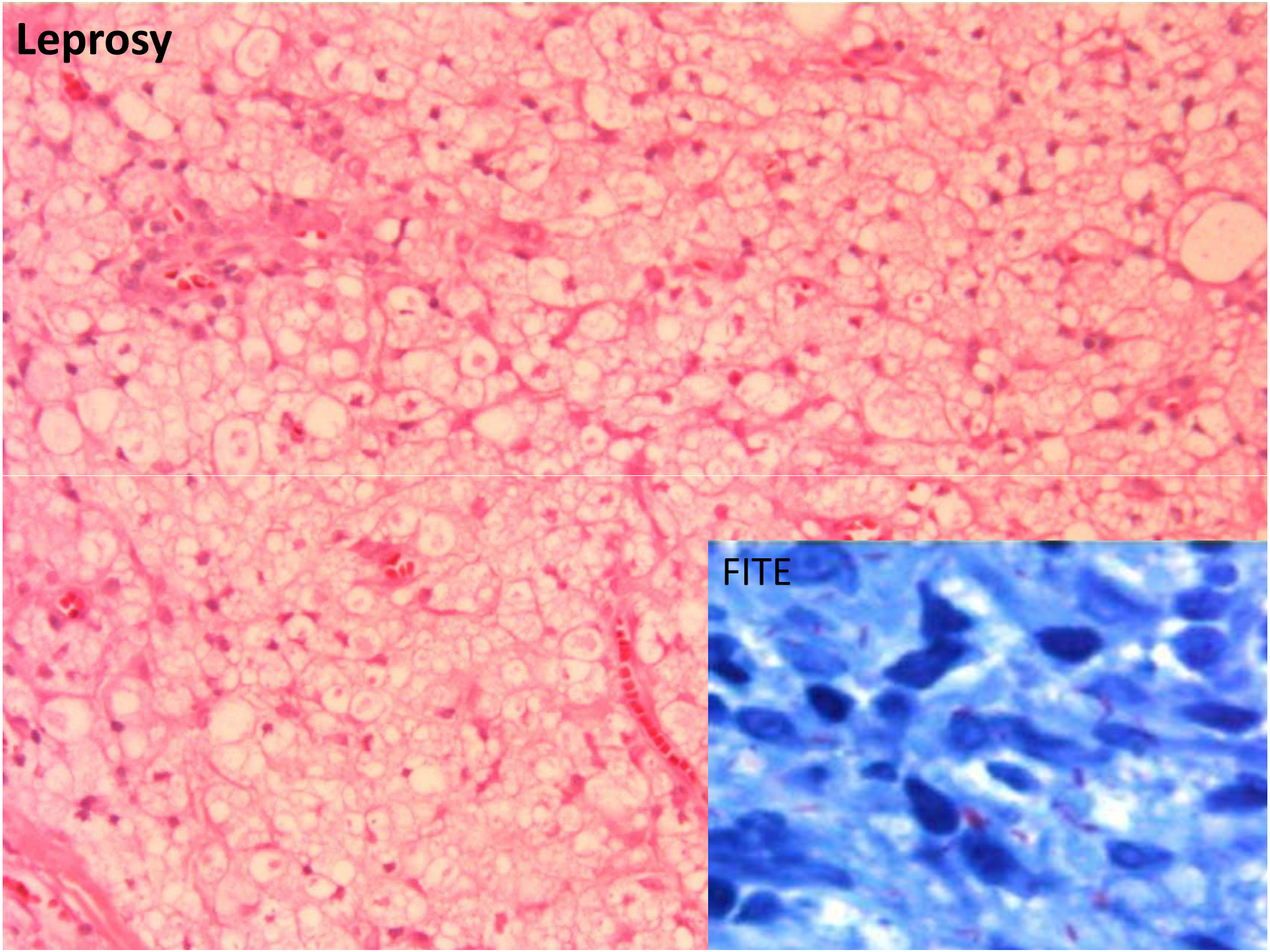
Leprosy
FITE

Case Scenario

- 42 yo male with a history of Hodgkin Lymphoma s/p BMT presents with right and left periorbital abscess and frontal sinus inflammatory mass. Tissue cultures positive for Mucor.

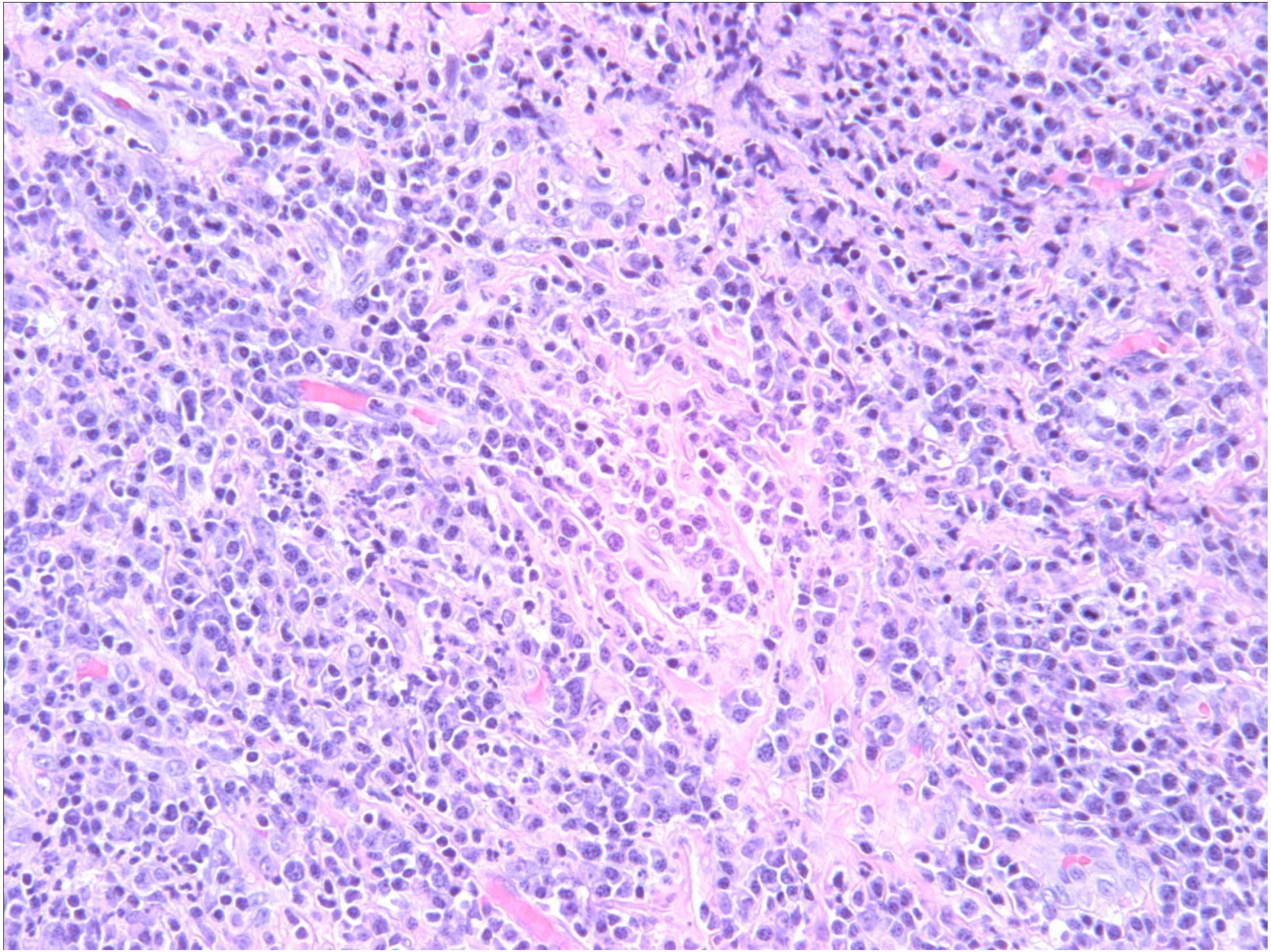

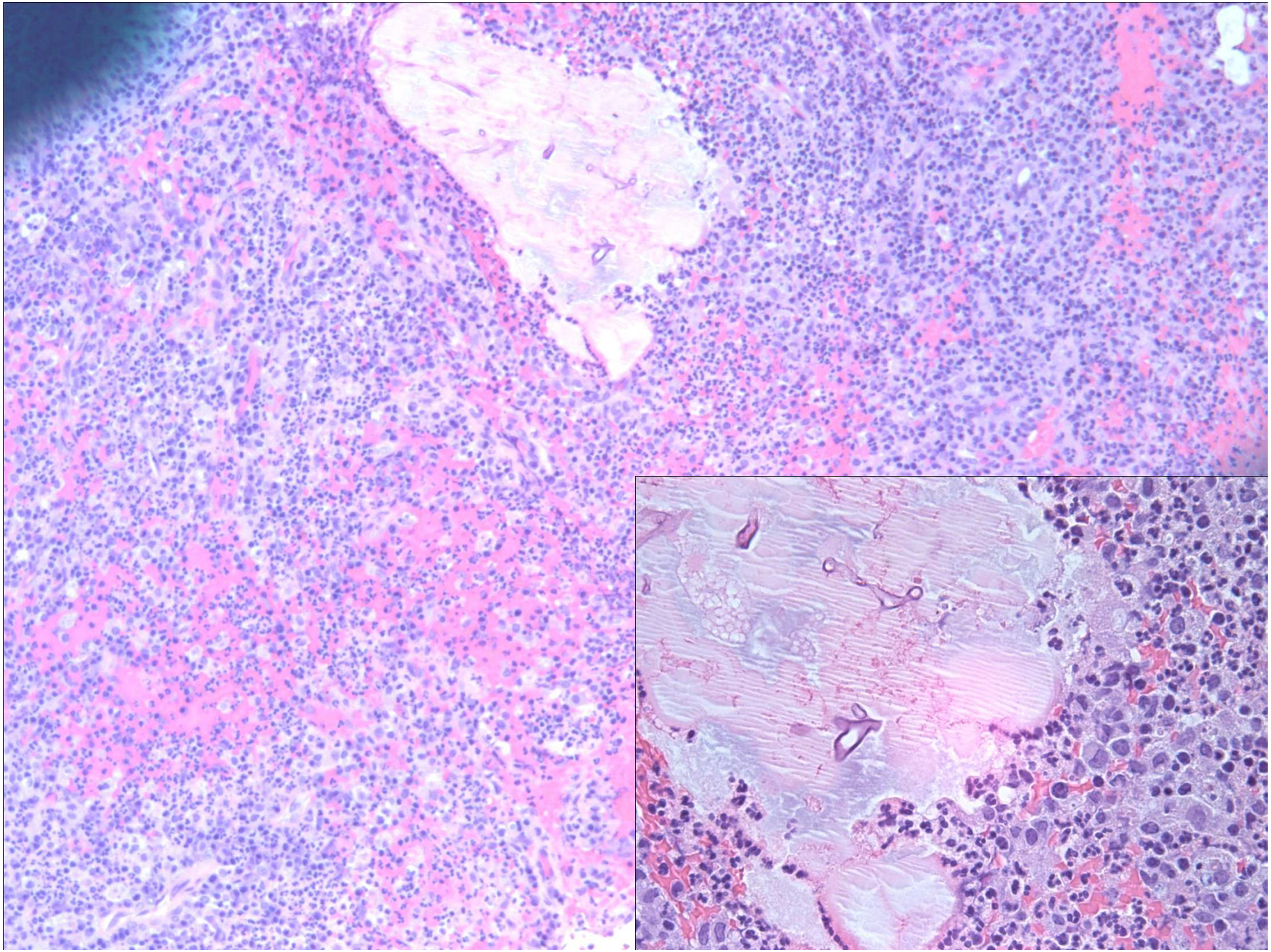

Case Scenario

- ID Physicians – after months of treatment case just does not fit with fungal infection alone.

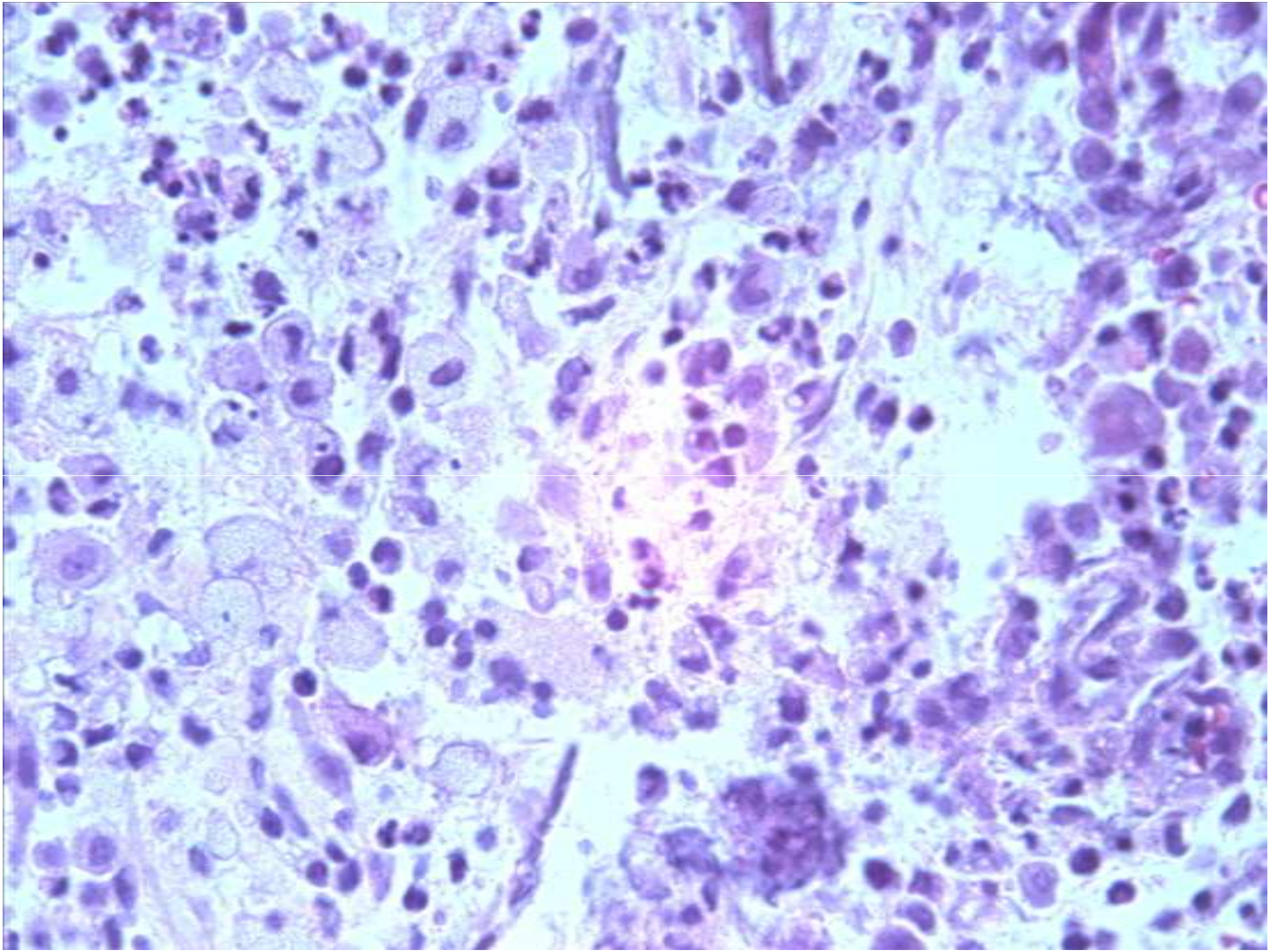

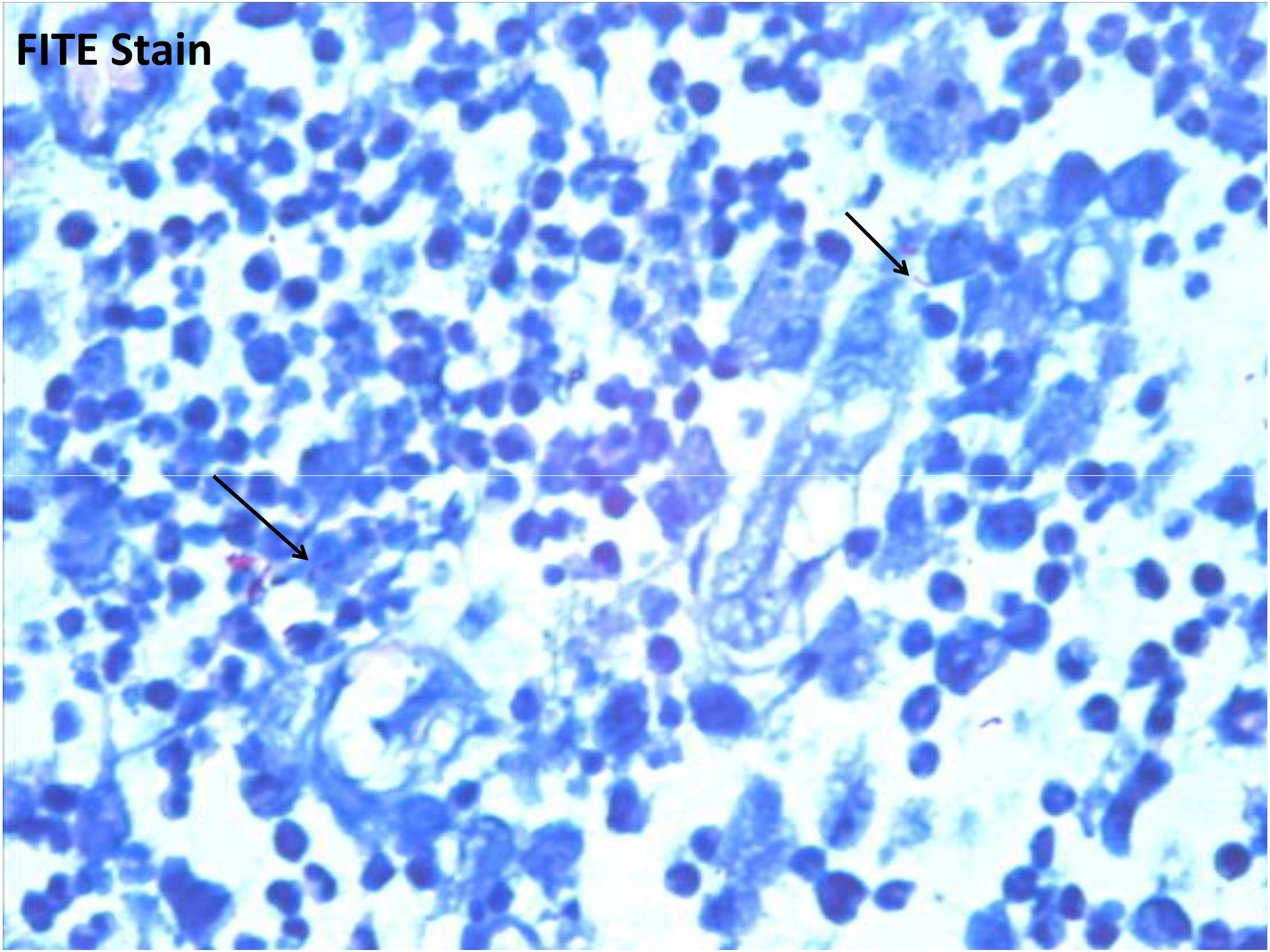
FITE Stain

Small-vessel Vasculitides

- ANCA-Associated Vasculitis
  - Wegener's Granulomatosis
  - Churg-Strauss
  - Microscopic polyangiitis
  - Drug-induced

Wegener's Granulomatosis

- Small vessel vasculitis
- Unknown etiology: probably immune, environmental, genetic
- M=F; any age peak in 40's
- Involves respiratory tract, kidney, skin
- Nasal sx: pain, stuffiness, rhinitis, hearing loss
- Septal perforation – saddle nose deformity
- Associated with c-ANCA

Wegener's Granulomatosis - Pathology

- **Findings often non-specific**
  - **Ulcerative changes/necrosis in sinonasal tract**
  - **Triad: geographic basophilic necrosis, vasculitis, granulomatous inflammation.**
  - **Vasculitis hard to see in sinonasal tract**
  - **Granulomas rare – may see scattered giant cells**
  - **Rarely are all 3 seen**
  - **MULTIPLE BIOPSIES OFTEN REQUIRED FOR DIAGNOSIS**

Basophilic Necrosis

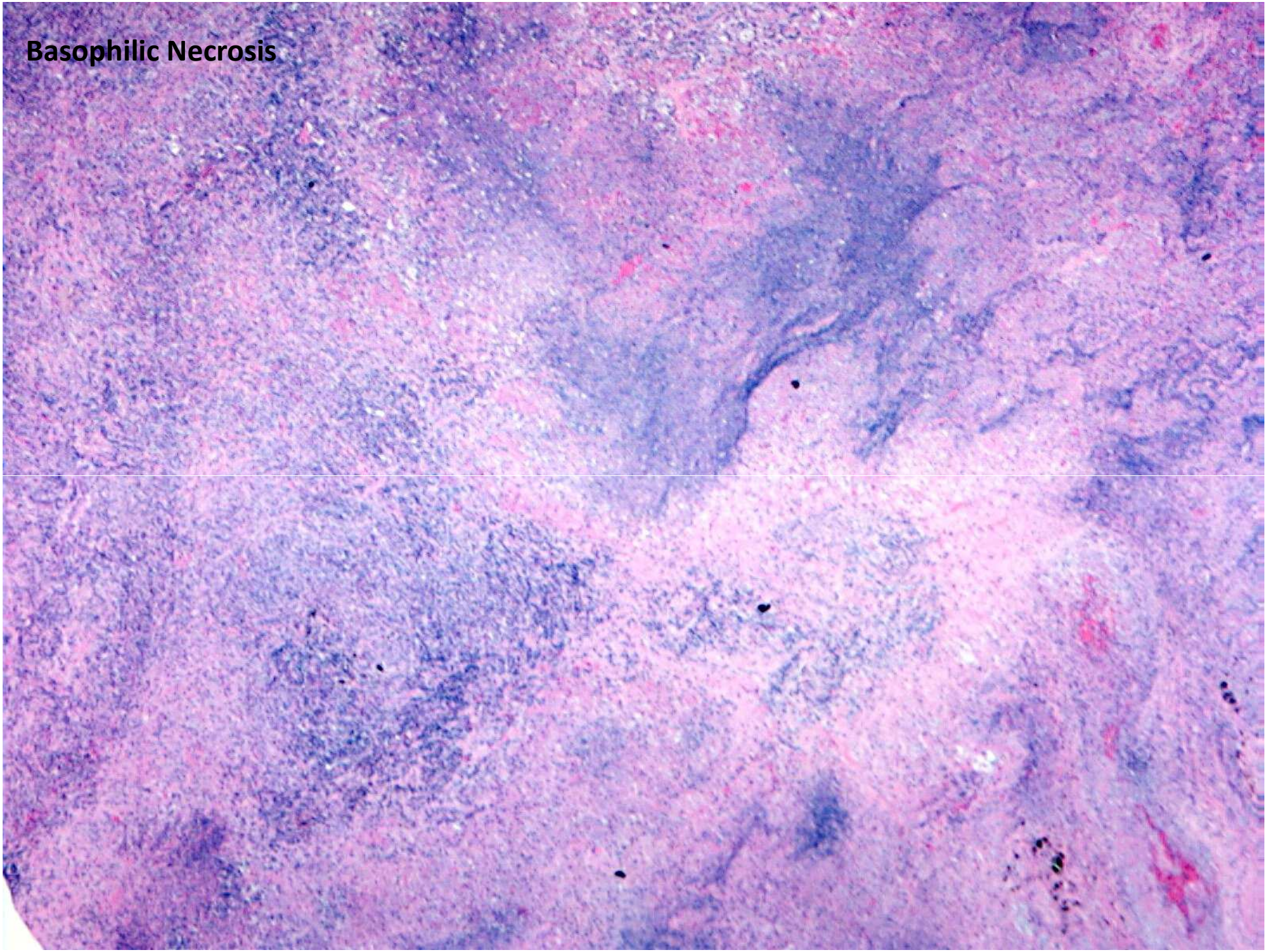

Geographic Necrosis

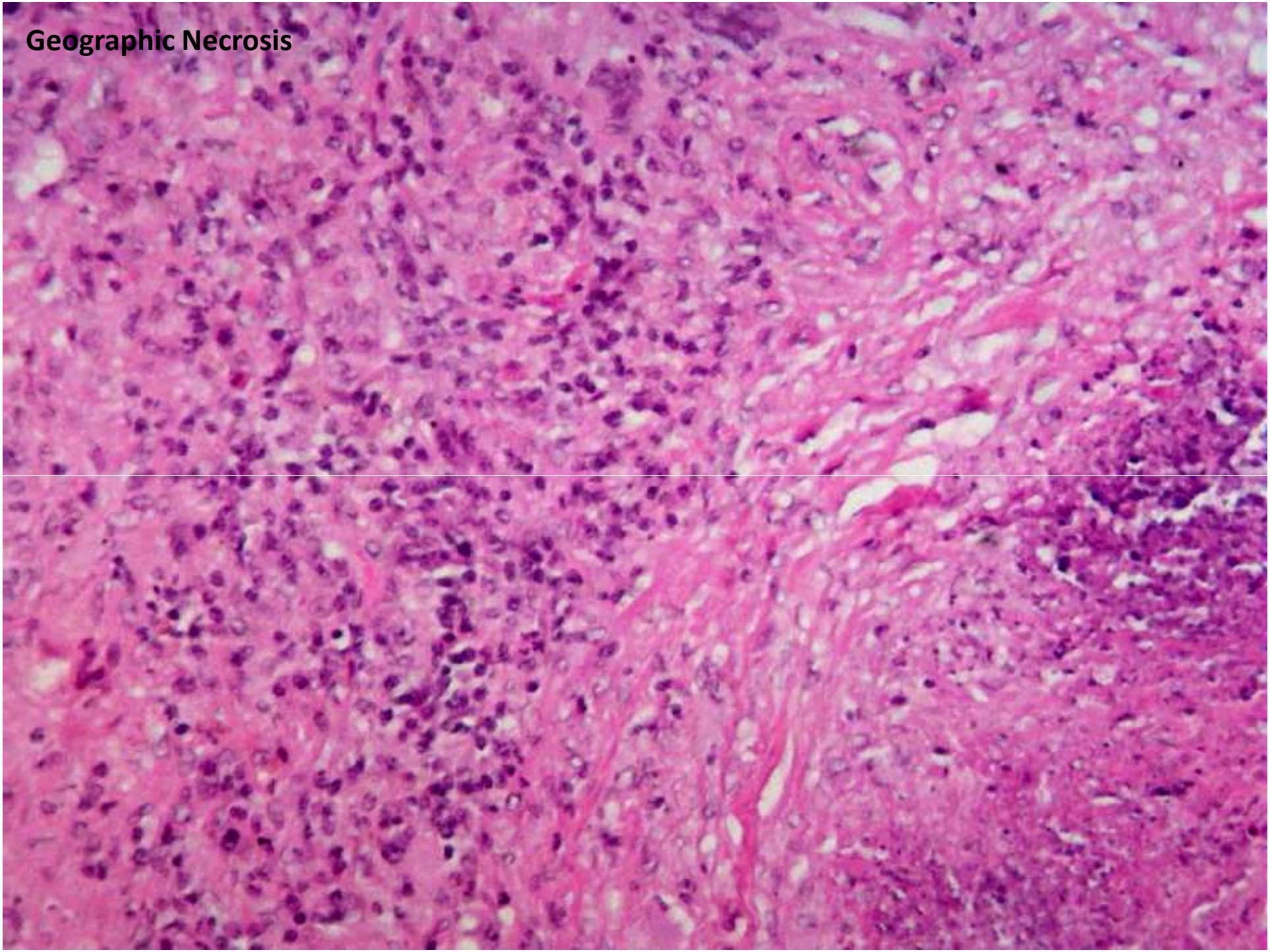

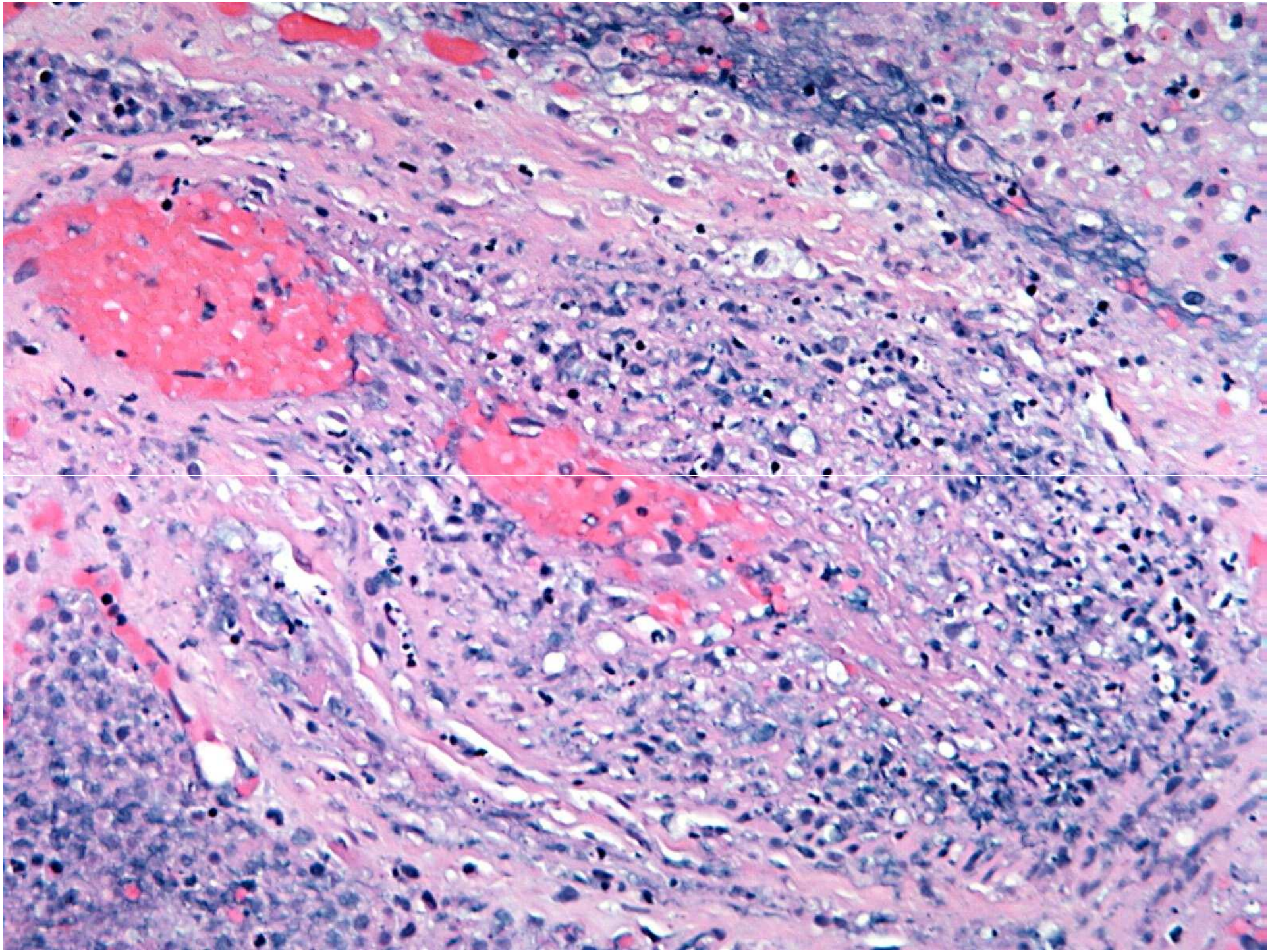

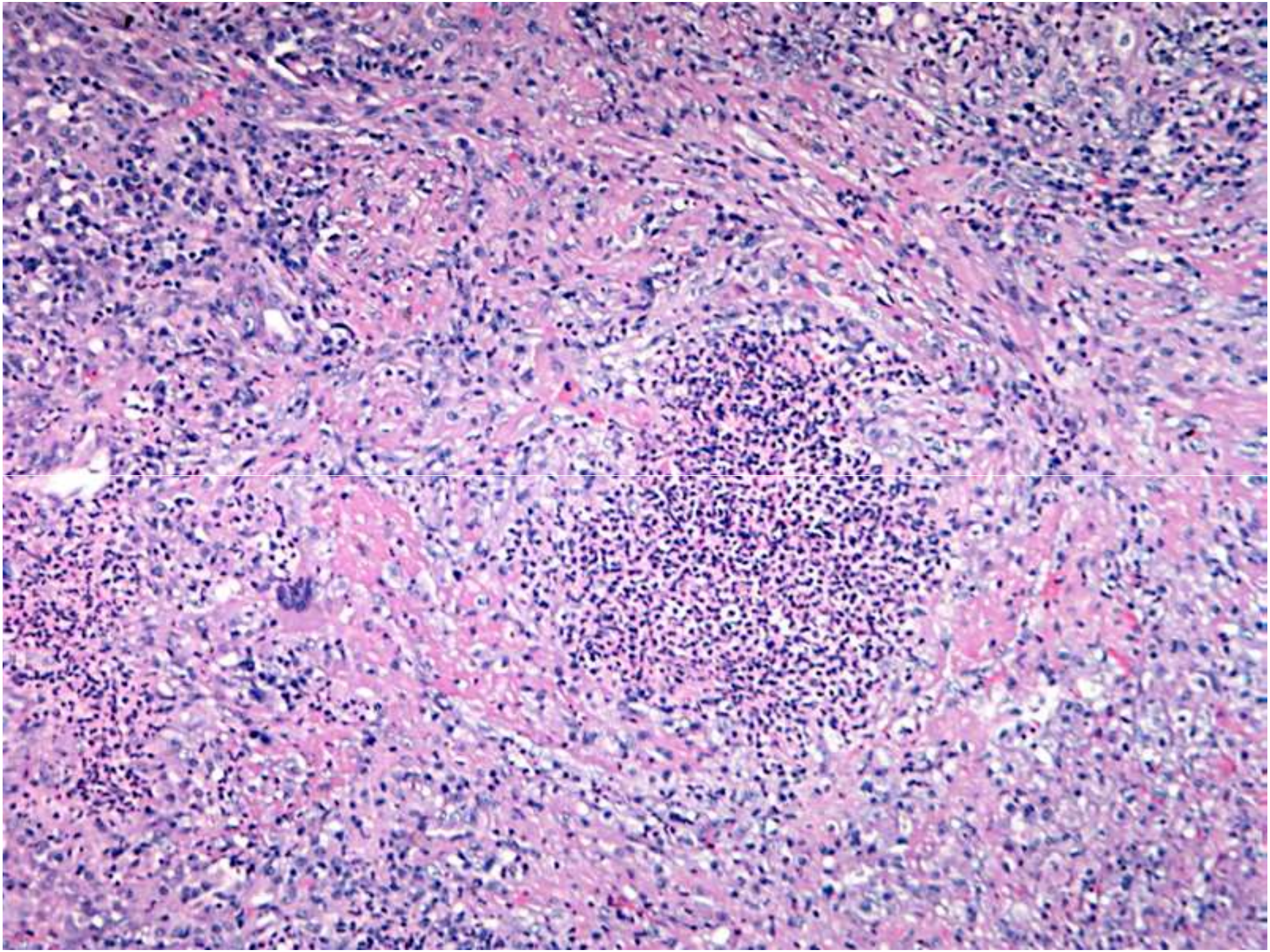

Wegener's Granulomatosis: DDX

- **Infection: Better granulomas, more giant cells**
- **Microscopic polyangiitis: Lungs, kidney, skin, p-ANCA (MPO)**
- **Churg-Strauss: Usually more lung involvement**
- **Extranodal NK/T-cell lymphoma: Cytologic atypia of lymphocytes**
- **Cocaine abuse: Foreign material used to cut the cocaine**

Churg-Strauss Syndrome

Rare to see sinonasal vasculitis or granulomas.

More common to see nasal polyps, chronic sinusitis

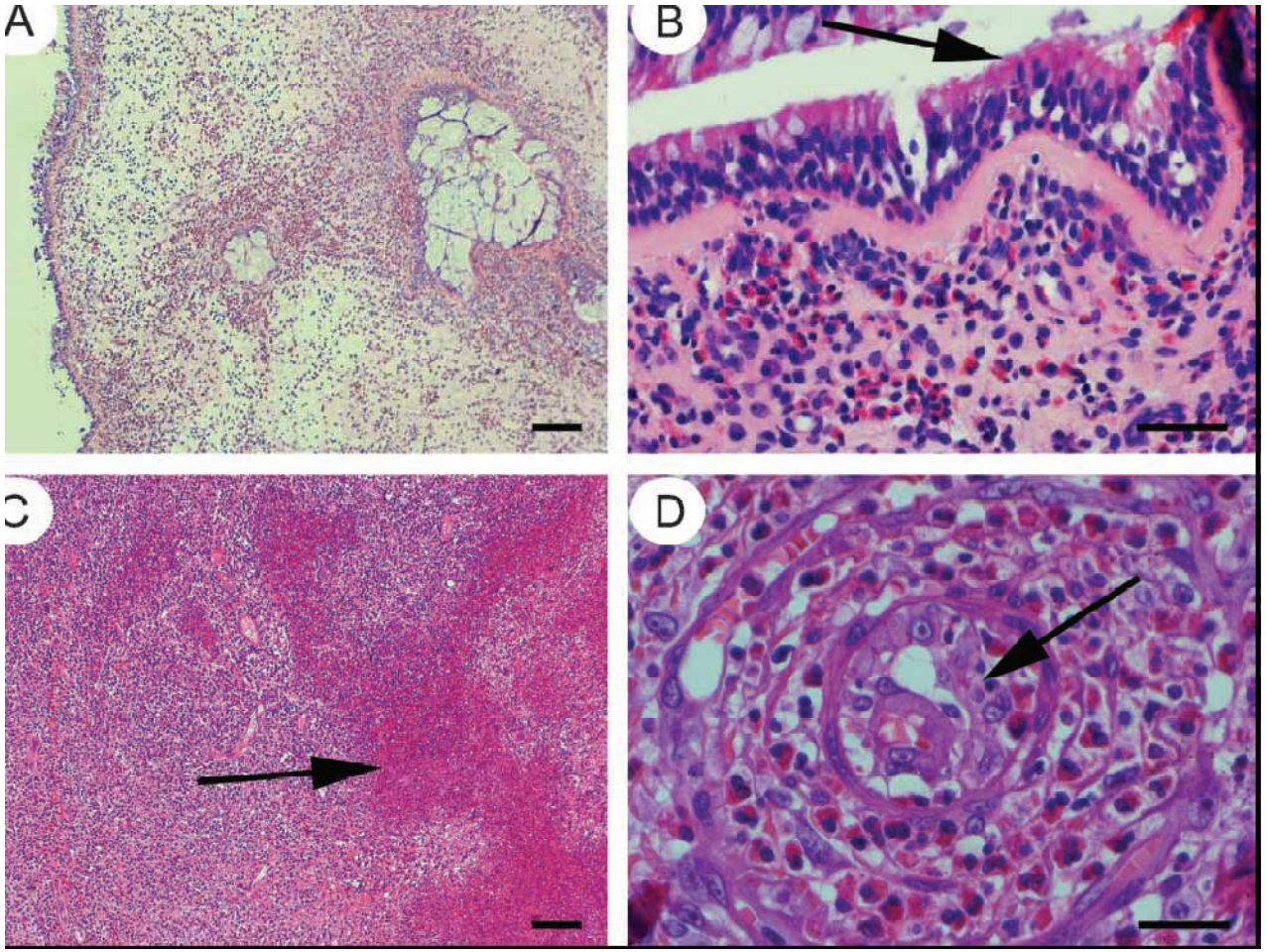

BACCIU A et al: , Ear, nose and throat manifestations of Churg-Strauss syndrome. Acta Oto-Laryngologica, 2006; 126: 503/509

Extranodal NK/T-cell Lymphoma, nasal type

- AKA: lethal midline granuloma, polymorphic reticulosis, midline malignant reticulosis, angiocentric lymphoma/CD56 lymphoma
- High grade, aggressive lymphoma
- M>F; >40 yo
- Uncommon in US comprising <1% but common in Asia; Central and South America.
- Associated with EBV.

Pathology

- **Broad cytologic spectrum: Can be associated with inflammatory "polymorphous " infiltrate – lymphocytes, plasma cells, histiocytes, eosinophils**

- **Tumor cells infiltrate large blood vessels resulting in zones of tissue necrosis in only 70% of tumors**

- **Immunophenotype:**
  - **Usually: $CD2^+$, cytoplasmic $CD3e^+$, and $CD56^+$.**
  - **Possibly: CD7, CD30, CD43, CD45RO, HLA-DR, interleukin-2 receptor, Fas (CD95), and Fas ligand.**
  - **Usually not seen: surface CD3, CD4, CD5, CD8, TCRg, TCRd, CD16, CD 20, and CD57.**

Immunohistochemical testing of surface CD3-, cytoplasmic $CD3e^+$, and $CD56^+$ differentiate NKTCL from peripheral T-cell lymphoma.

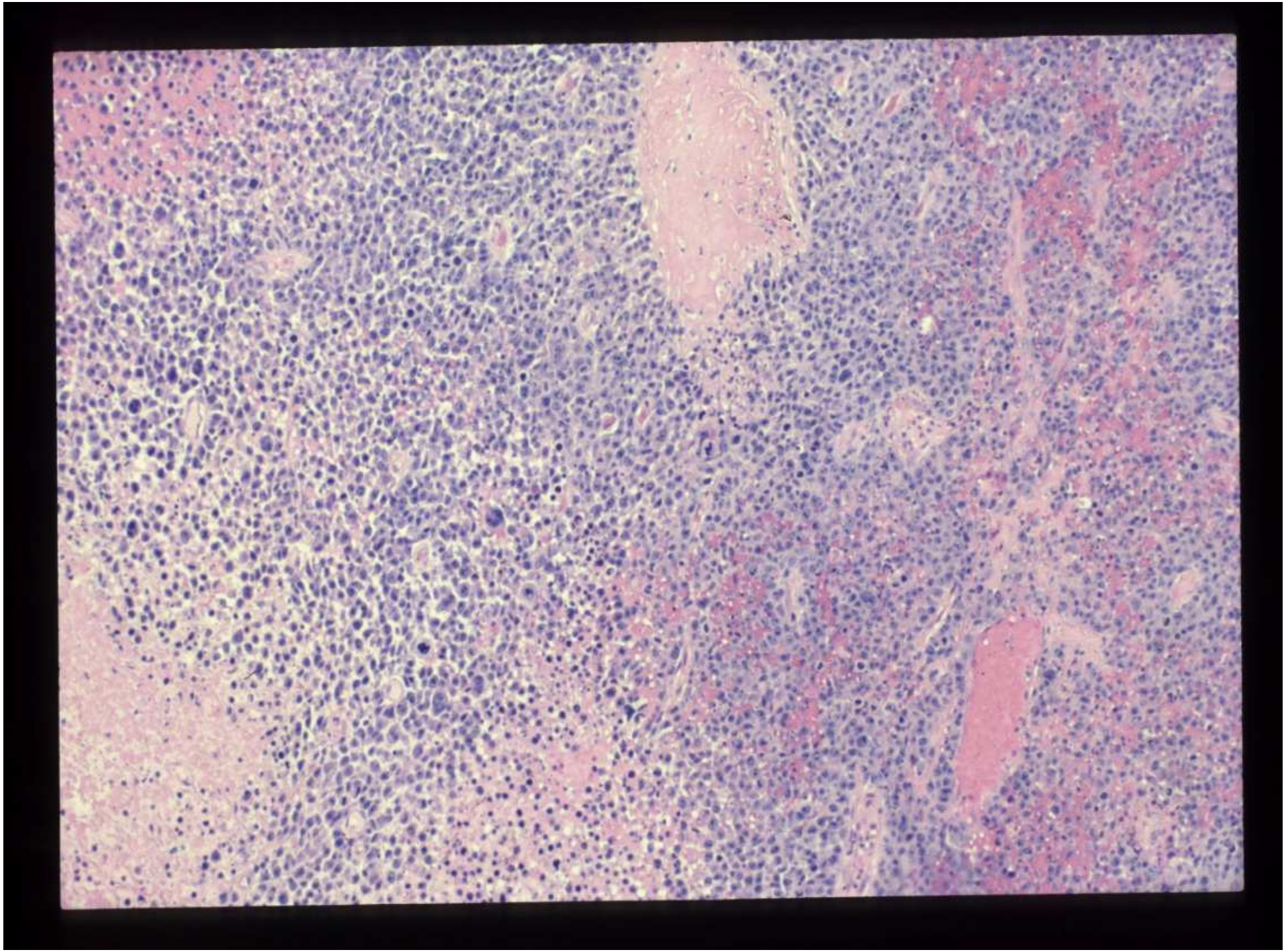

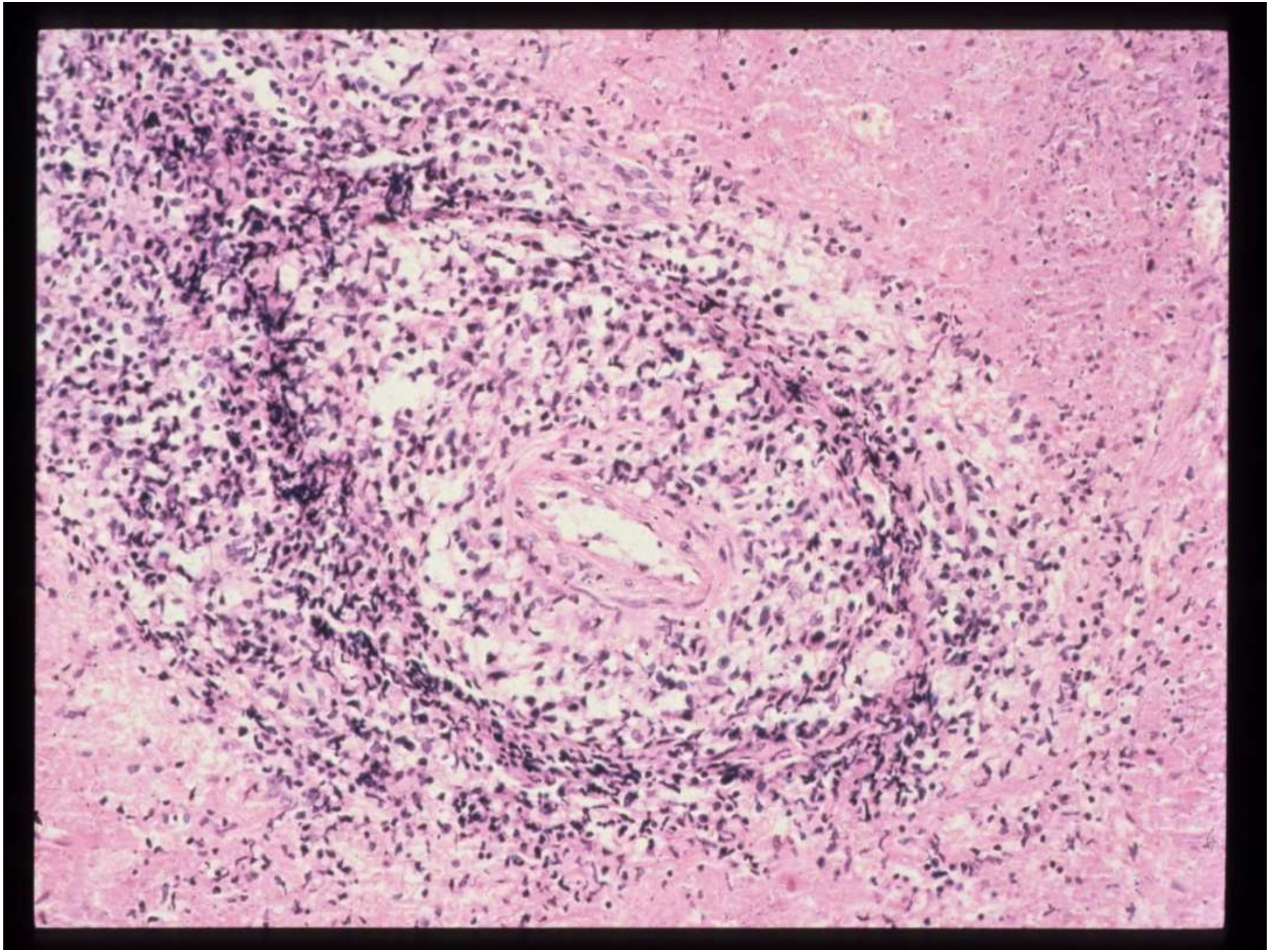

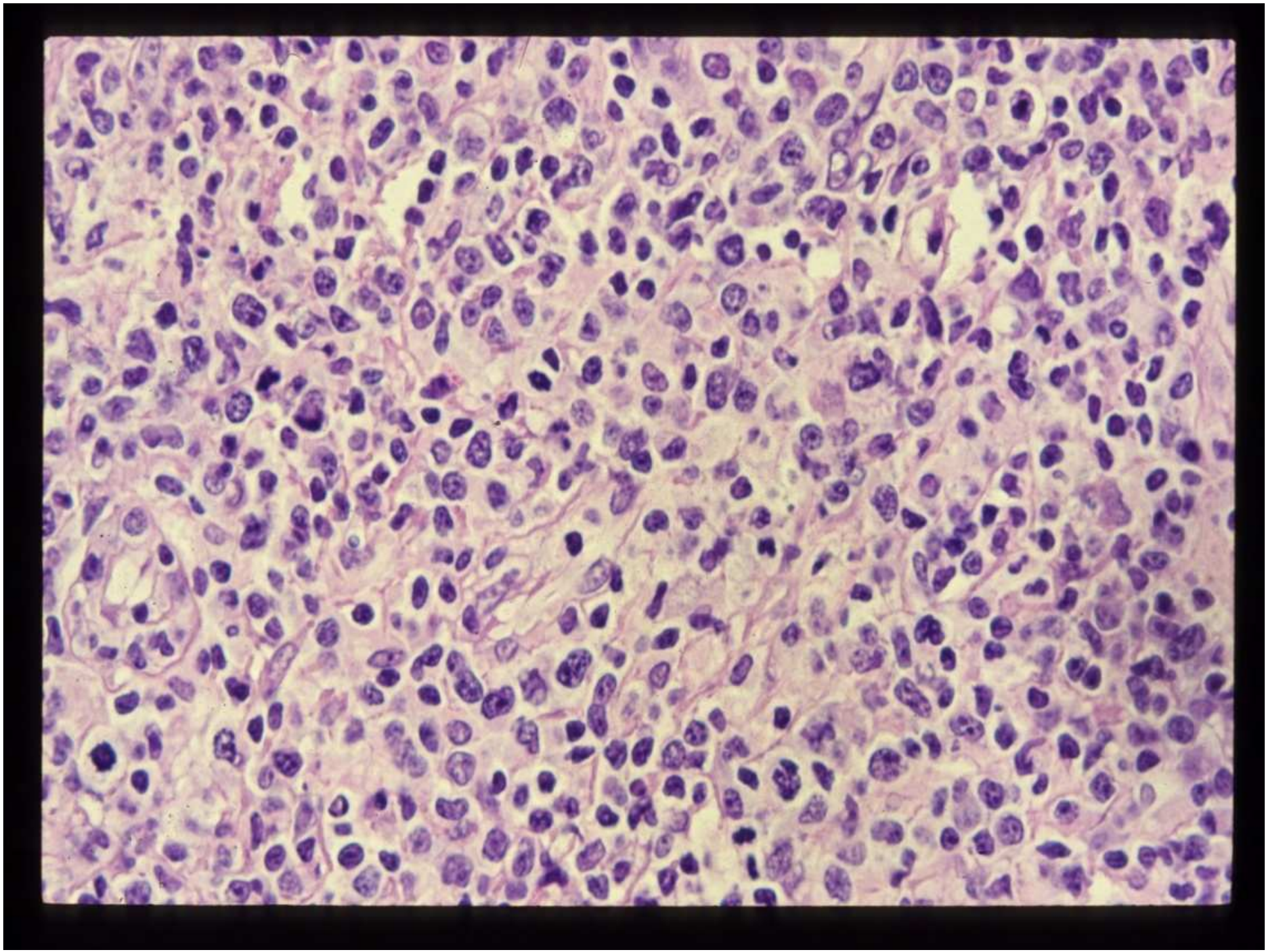

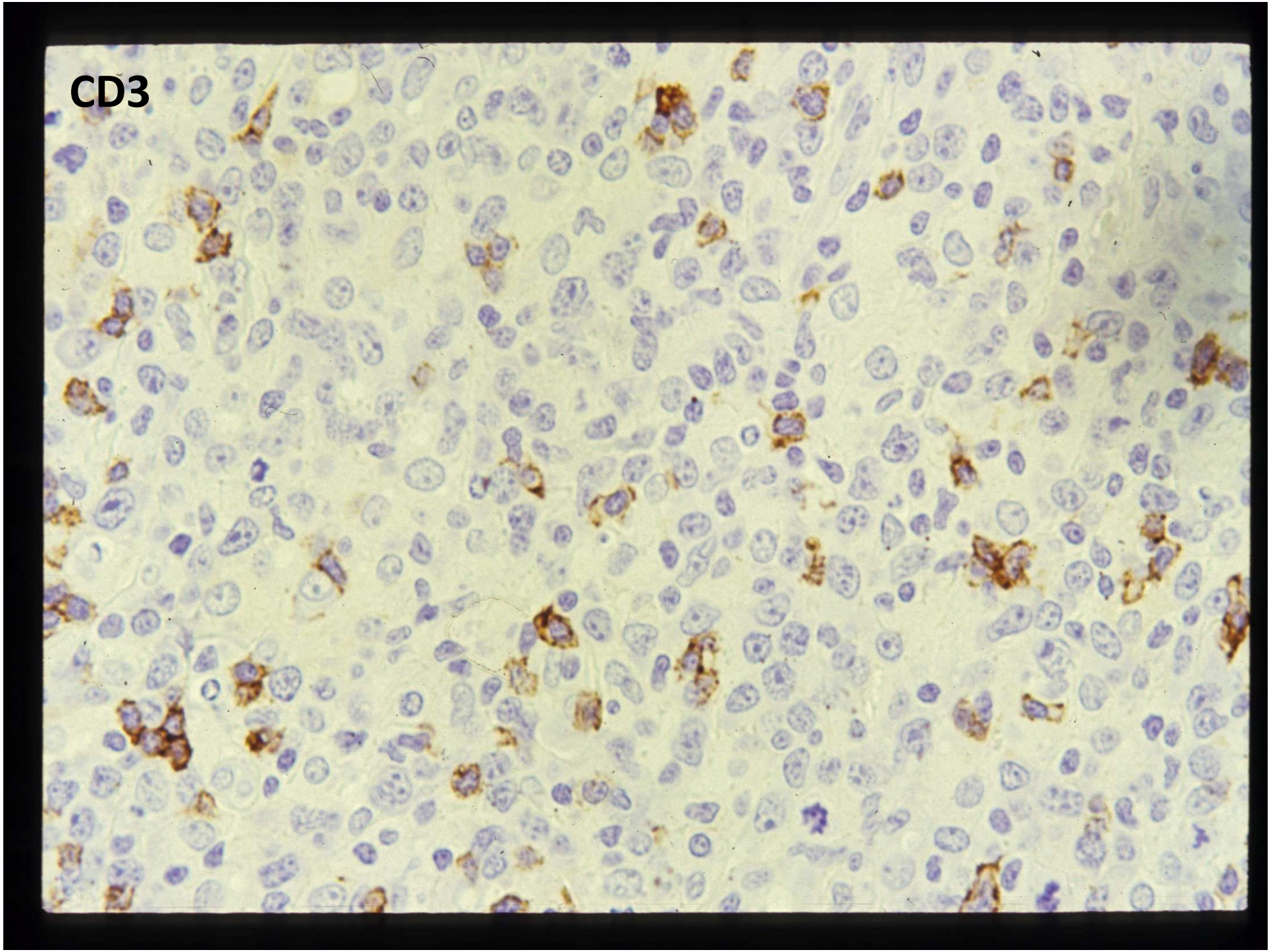
CD3

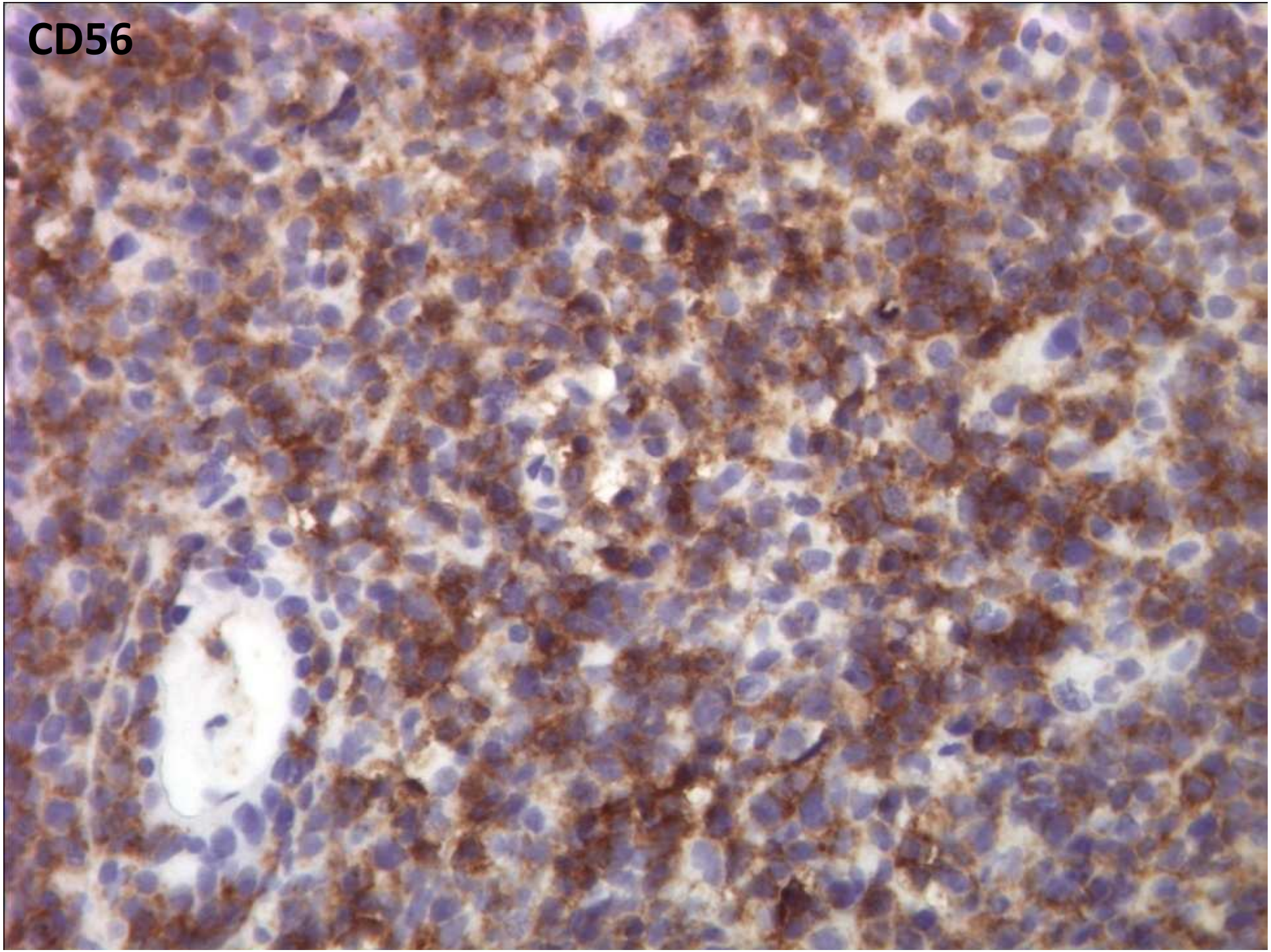
CD56

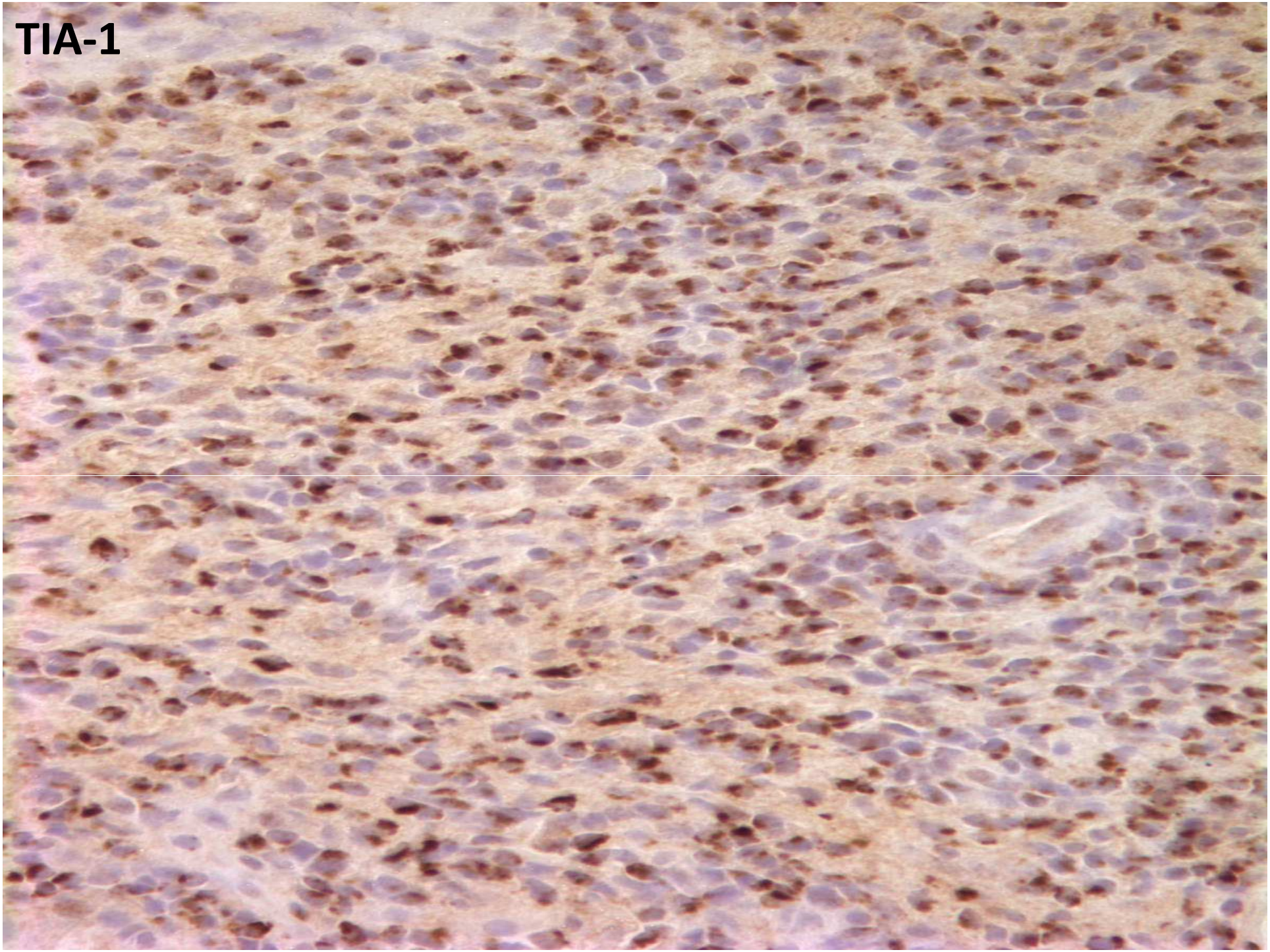
TIA-1

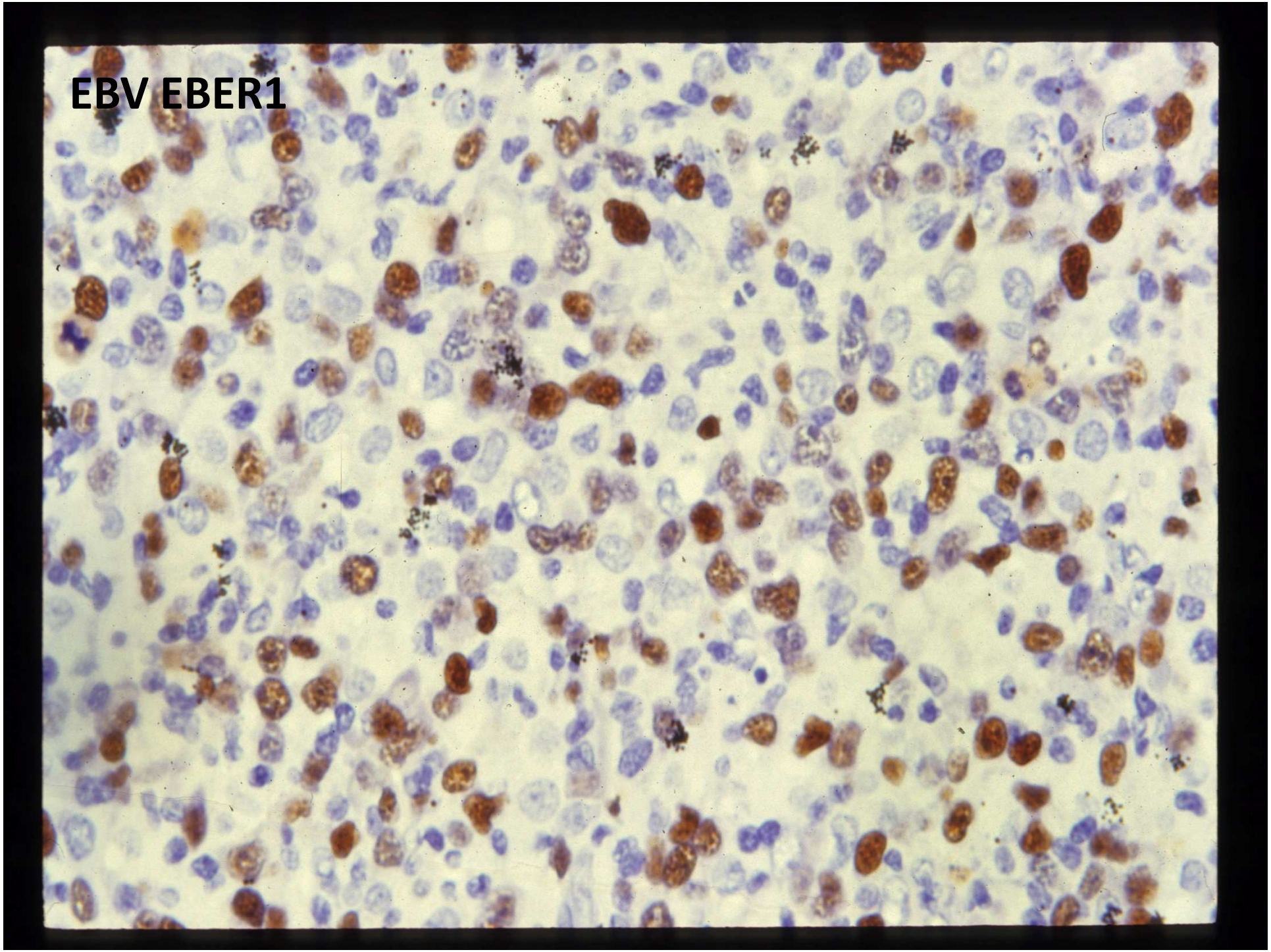
EBV EBER1

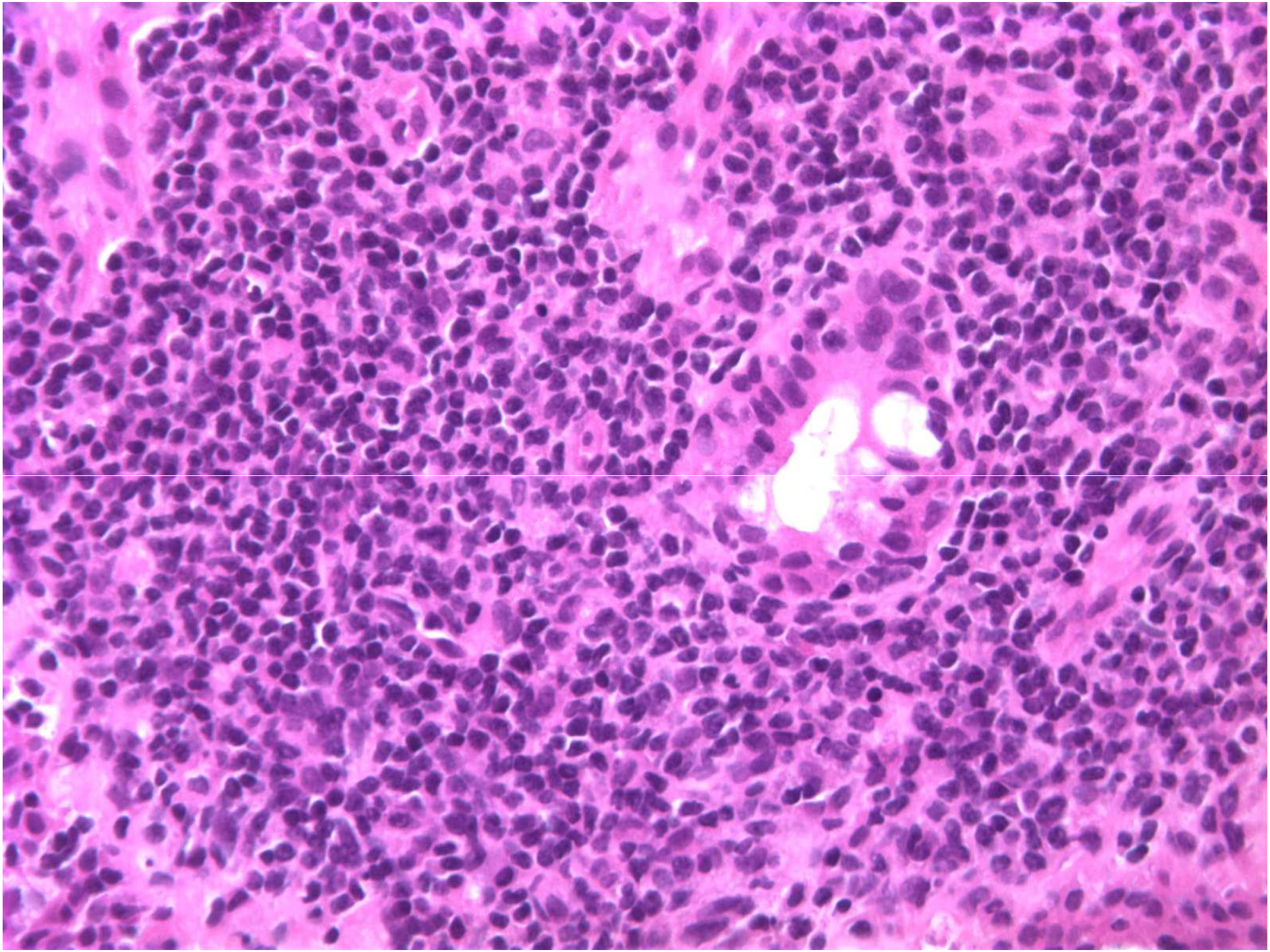

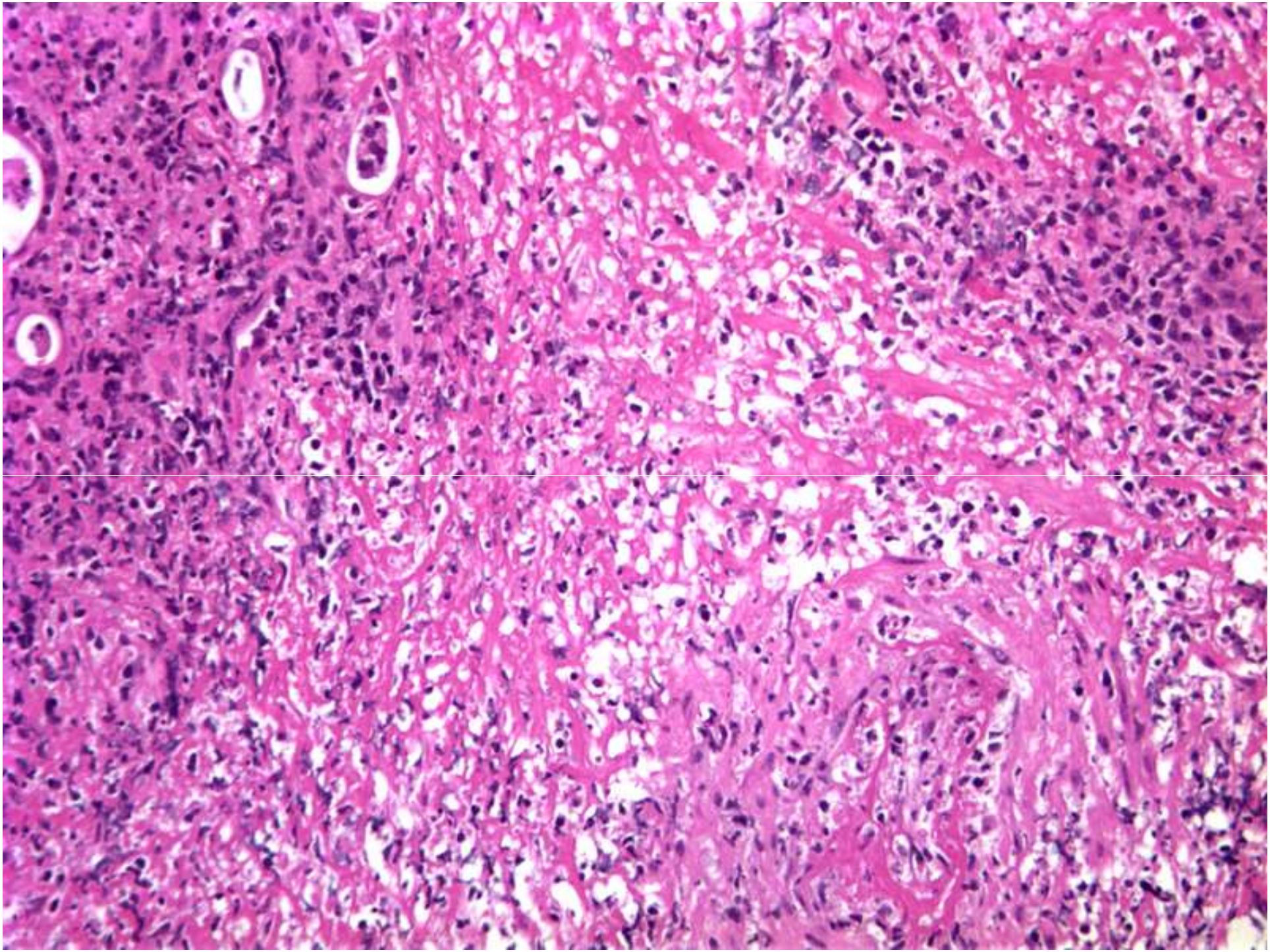

Case Scenario

47 yo female with history of “SLE”, nasal obstruction and presumed chronic rhinosinusitis.

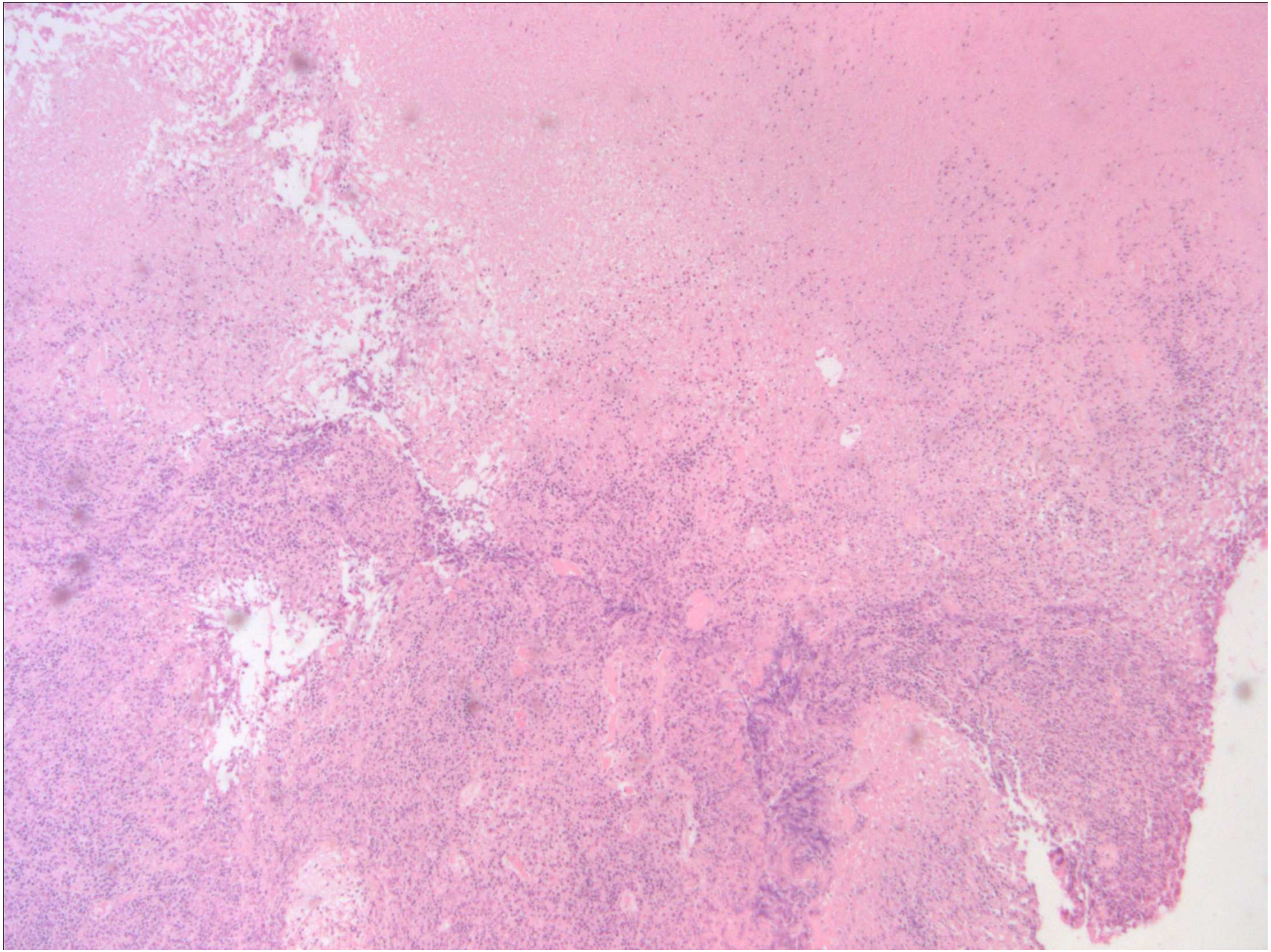

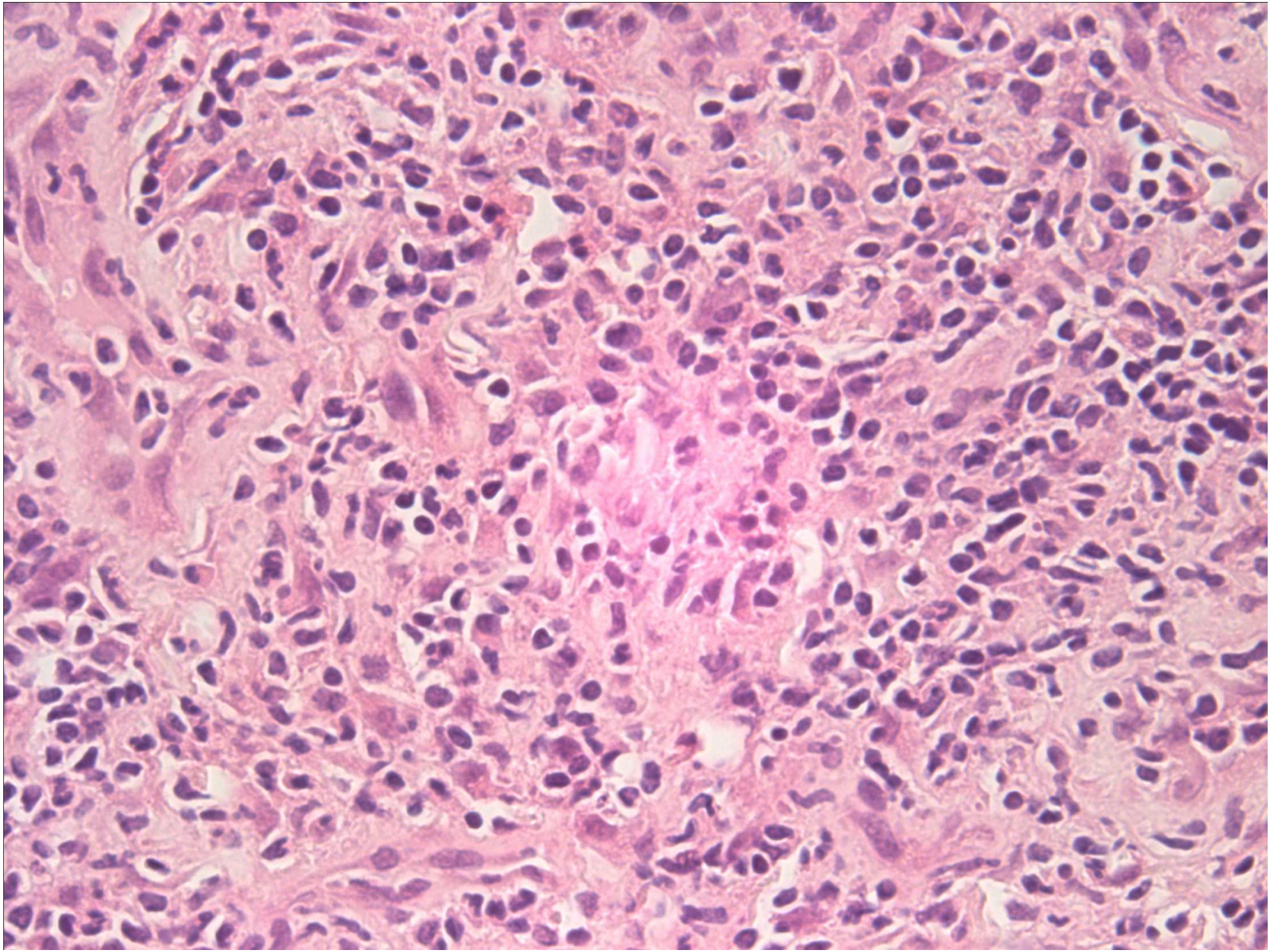

Case Scenario (Continued)

Development of new skin lesions and progressive worsening of sinonasal symptoms.

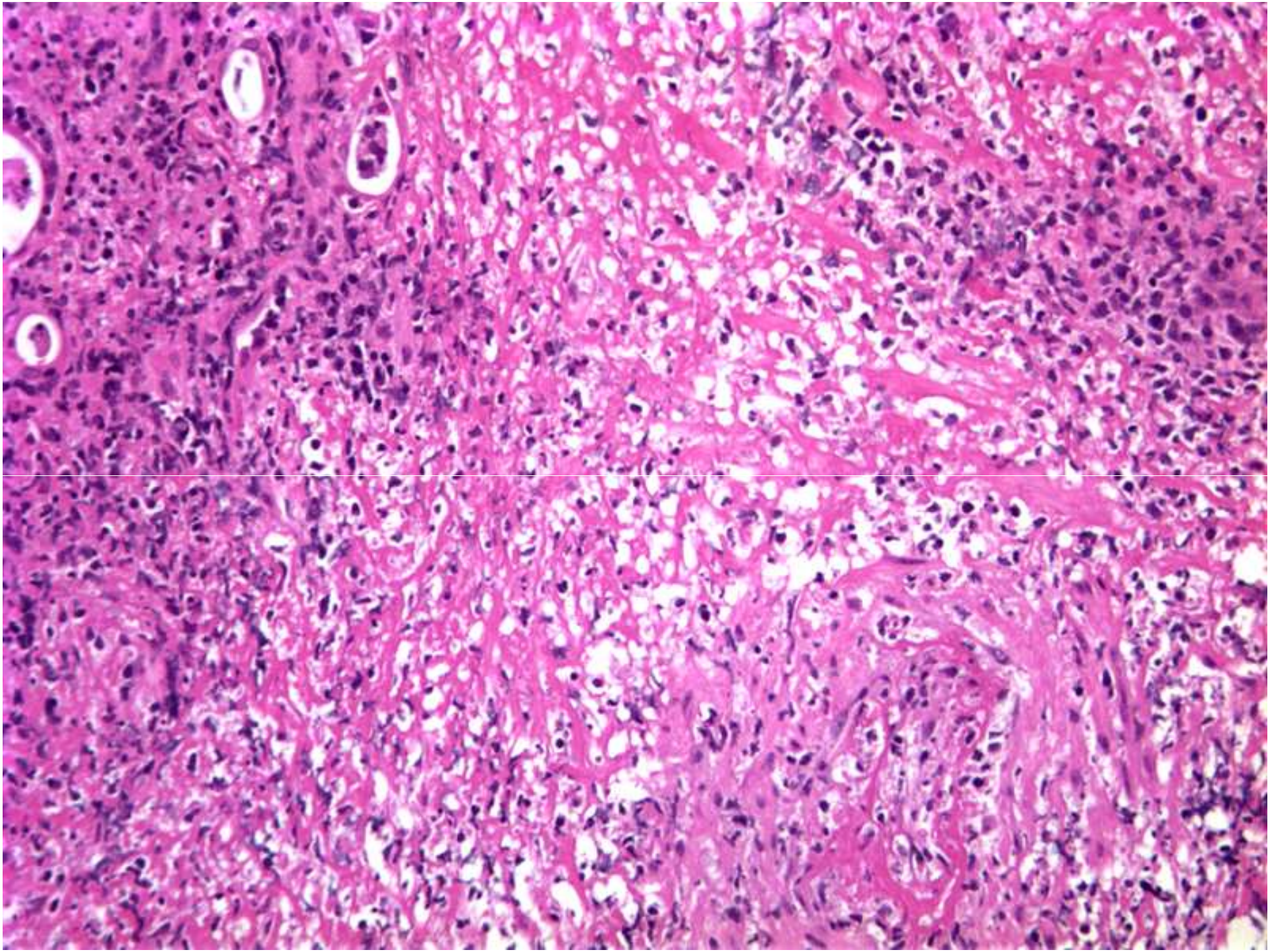

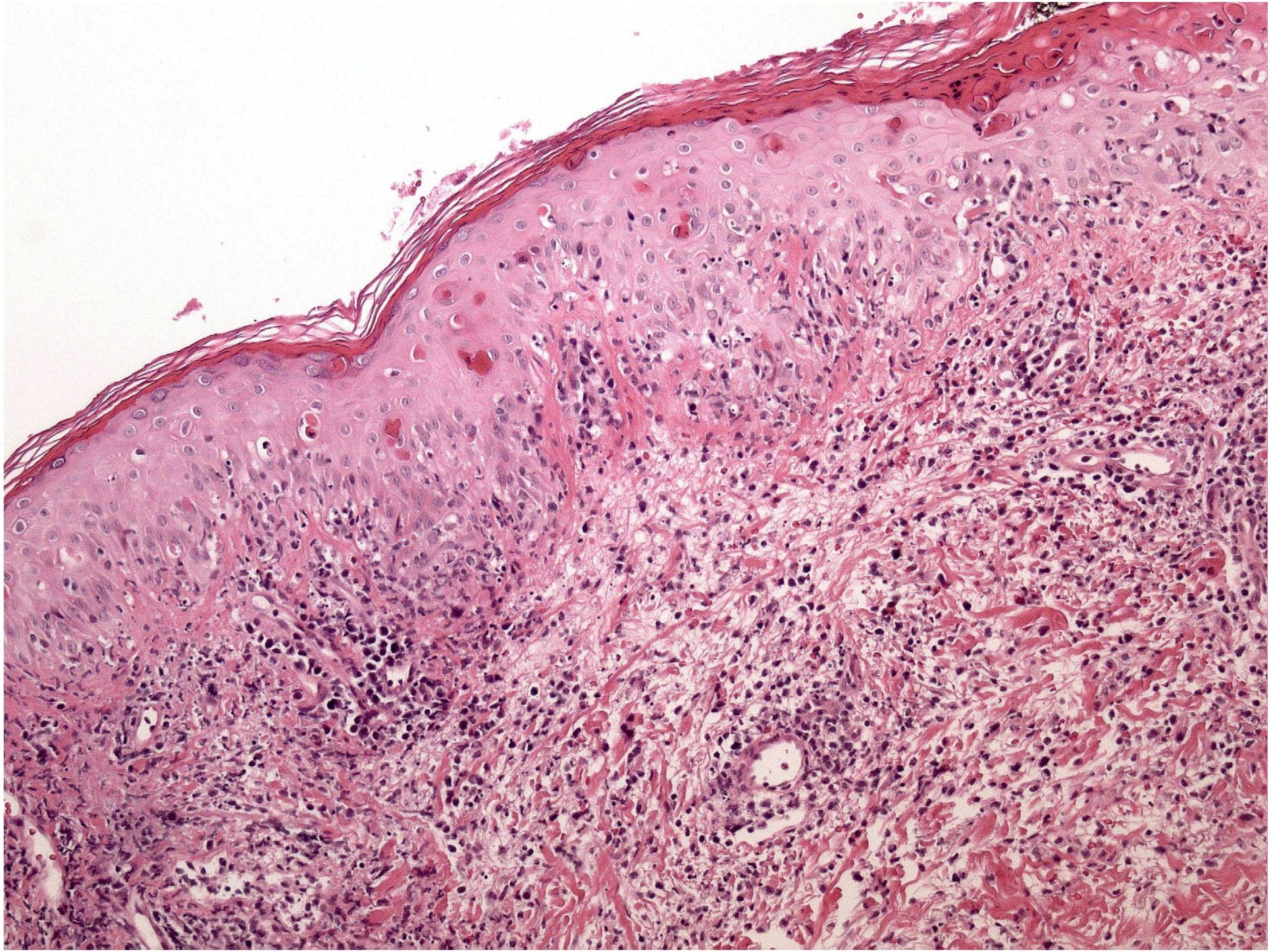

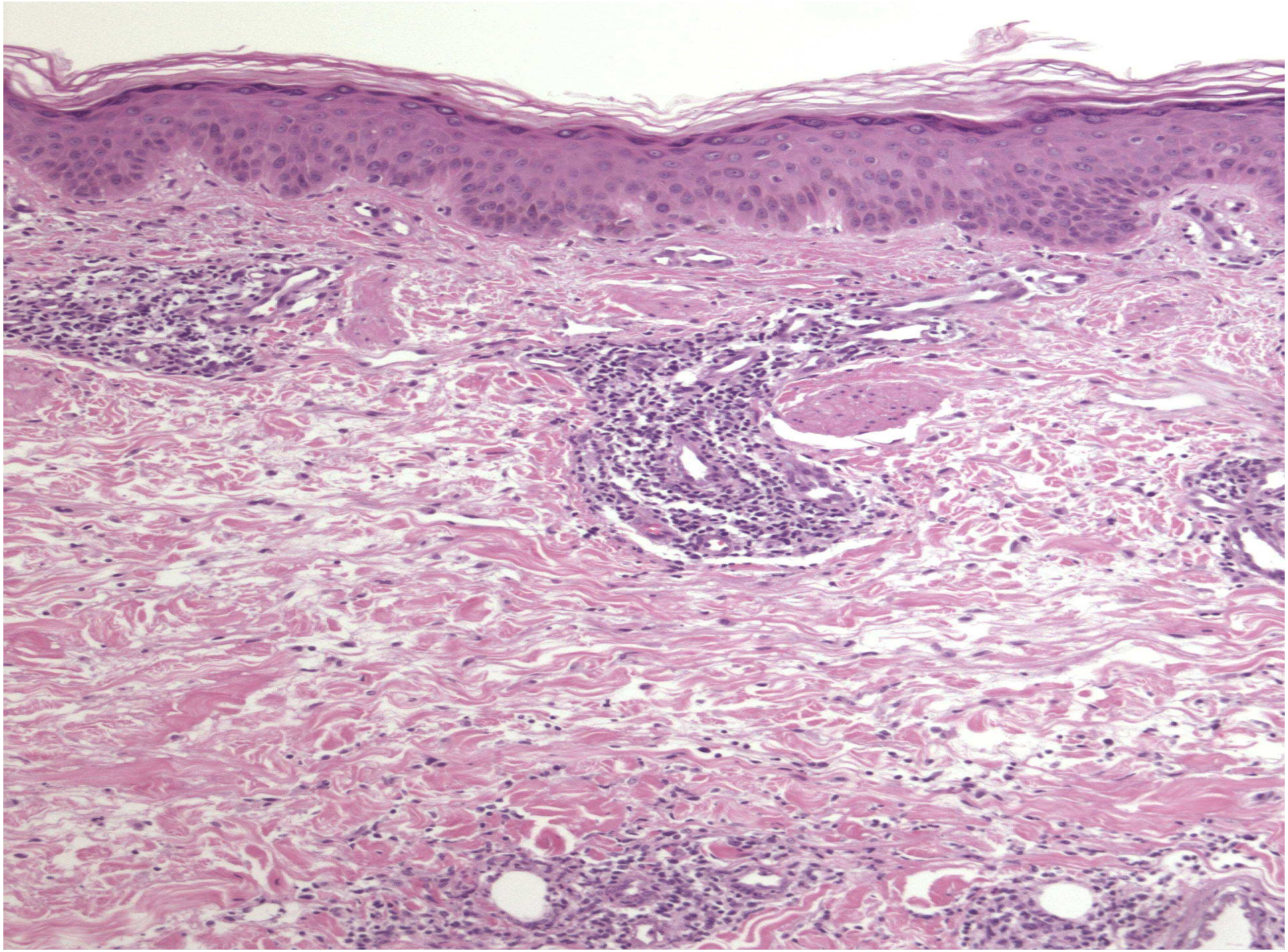

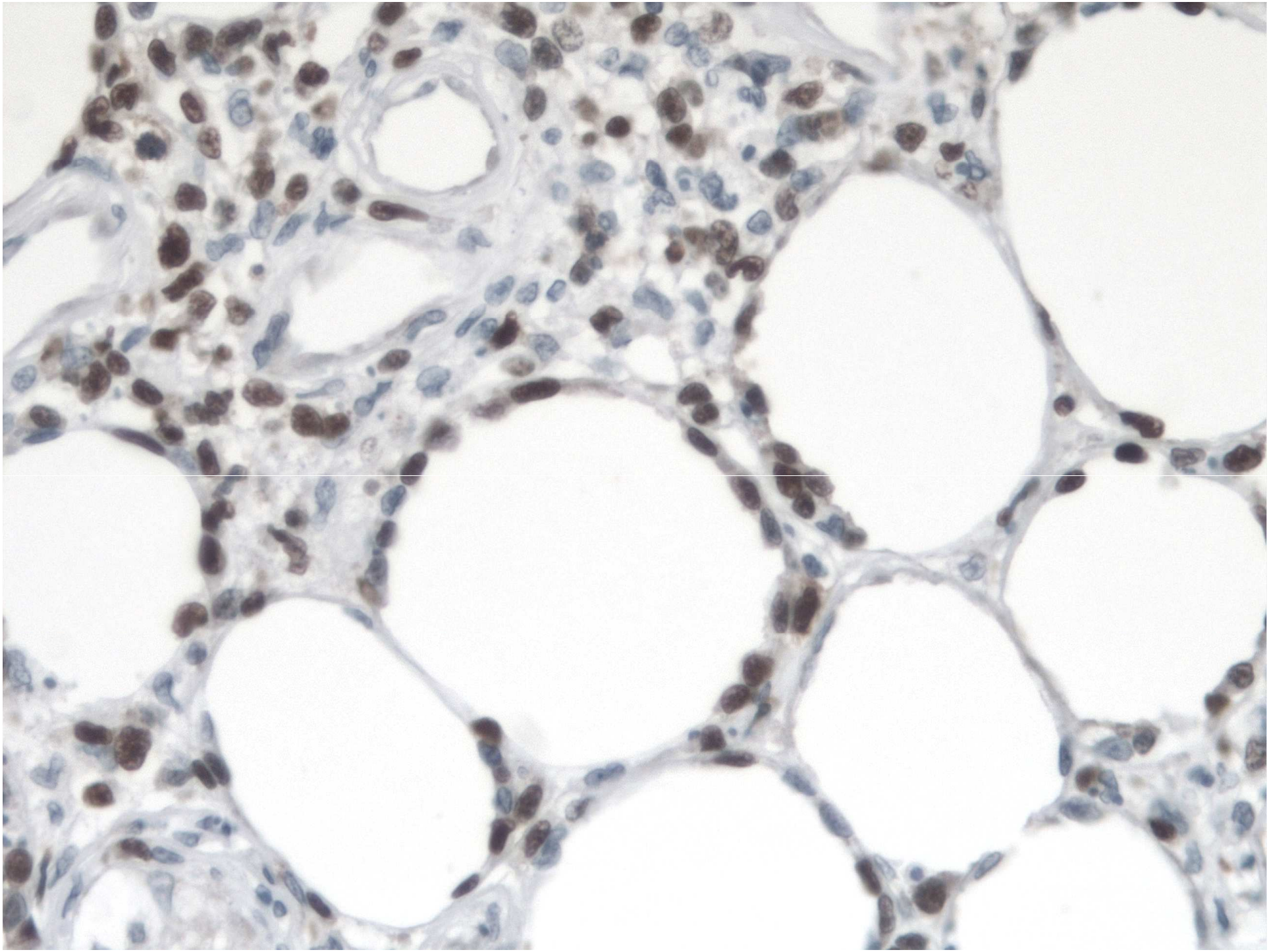

Cocaine Abuse

- Can cause extensive midline nasal destruction
  - Simple septal perforations
  - Alar necrosis
  - Saddle deformities
  - Massive, necrosis of the sinonasal tract and palate bone and cartilage.
  - Similar findings can be seen with “snorting” crushed oxycontin
- Treated conservatively with debridement of necrotic tissues, antibiotics, saline irrigations, and abstinence from cocaine.

Cocaine-Induced Sinonasal Destruction

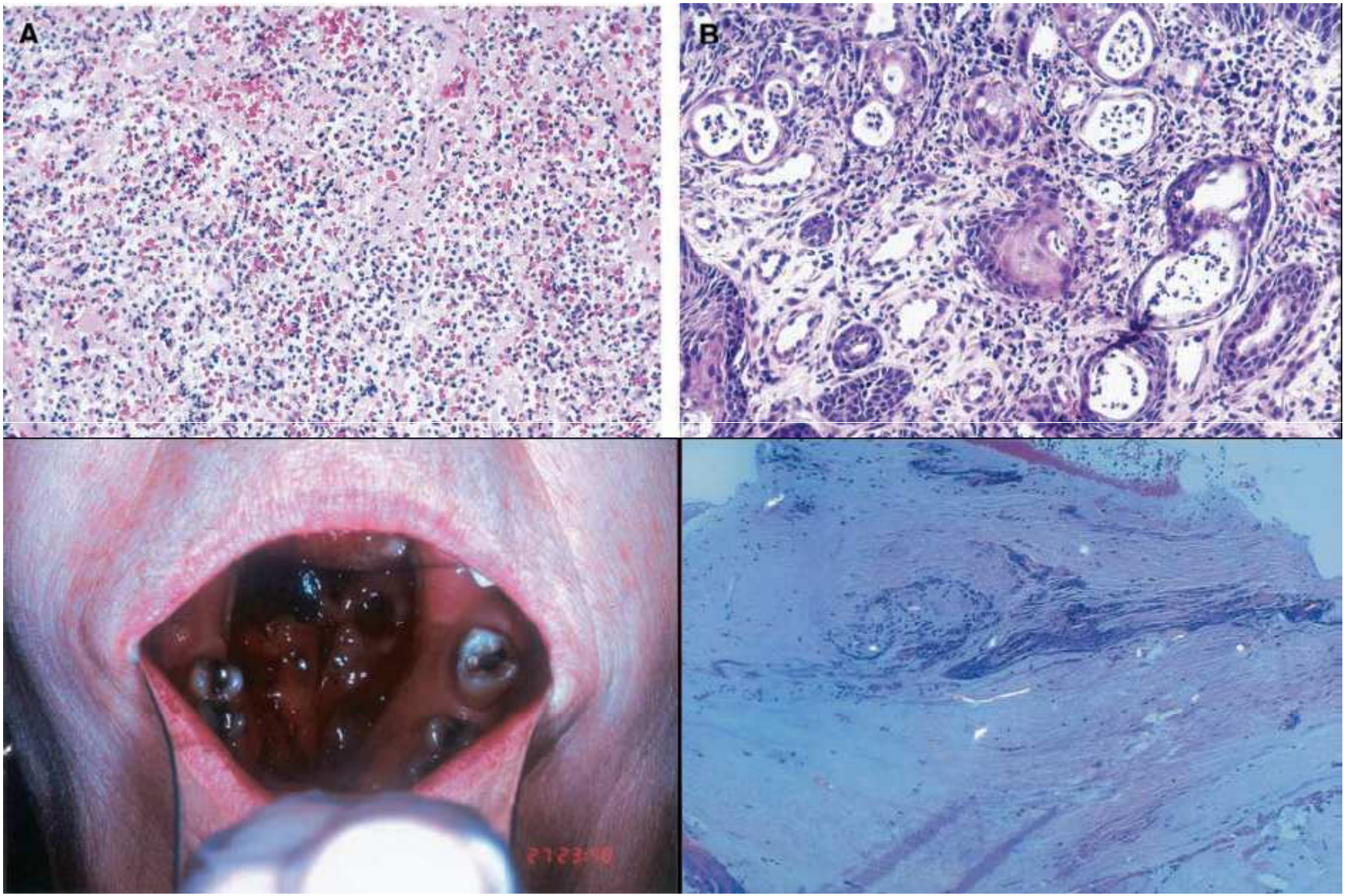

Bradley A et al: Aggressive destructive midfacial lesion from cocaine abuse. Oral Surg Oral Med Oral Pathol Oral Radiol Endod 2002;94:465-70)

Approach to Necrotizing Sinonasal Lesions

- Is it infectious?
  - Special stains: gram, Grocott (GMS), AFB, Fite
- Is it neoplastic?
  - Atypical cells, density of cells; EBER studies; TCR
- Is it autoimmune?
  - Vasculitis, serologies, clinical history
- Is it self-induced?
  - Drug abuse history?; polarize

So what was our case?

43 yo female with history of nasal septal perforation and Bechet's syndrome.

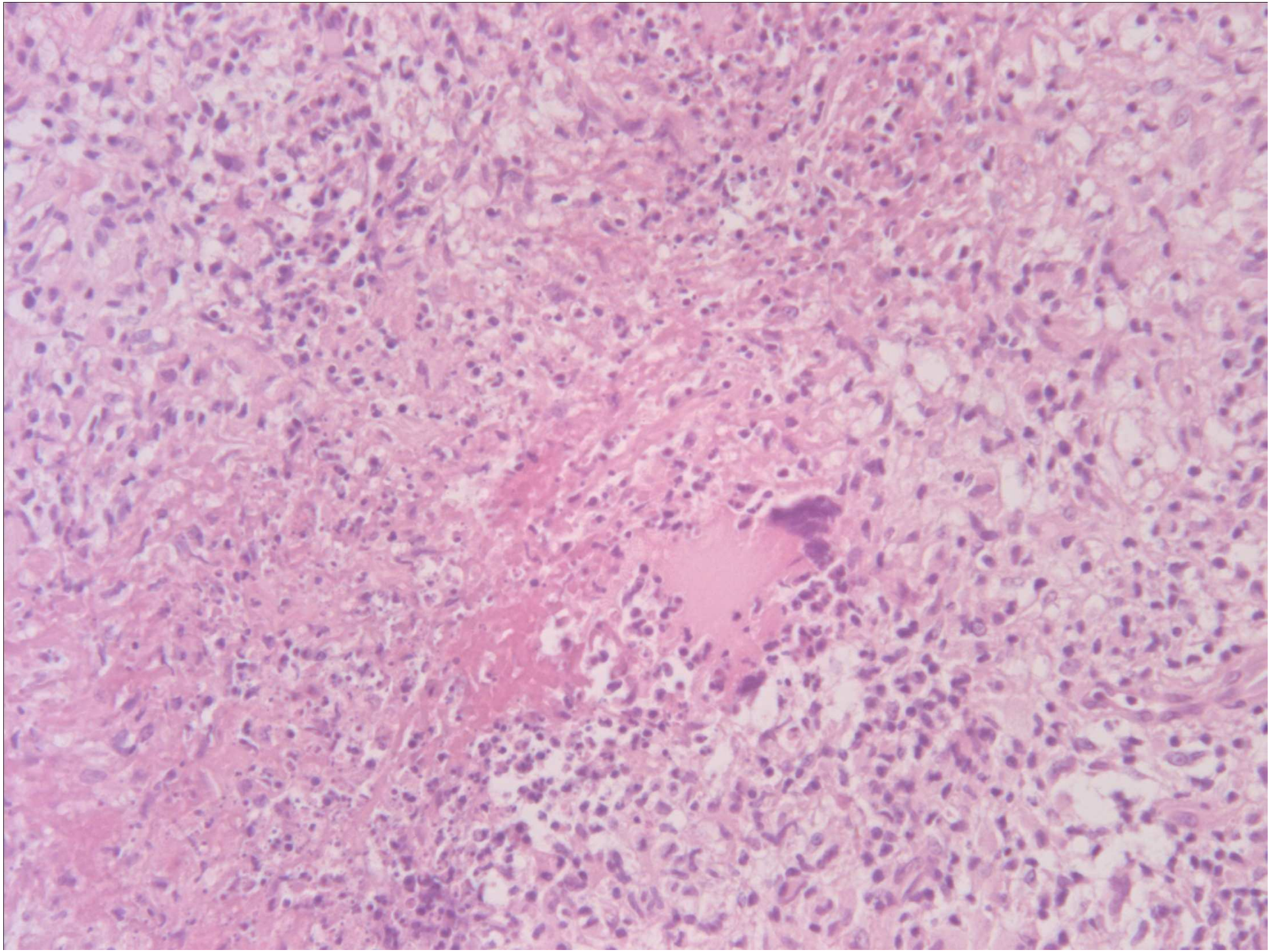

Diagnosis

- Bugs stains negative
- Heme work up including EBER negative
- ANCA negative

- ADDITIONAL HISTORY – longstanding cocaine user

Necrotizing granulomatous inflammation due to cocaine abuse mimicking Wegener's Granulomatosis

Necrotizing Sinonasal Lesions: Conclusions

- **Differential diagnosis of necrotizing intranasal lesions is extensive**
- **Lab tests: ANCA and Fungal skin tests.**
- **Biopsy with special stains and cultures for acid-fast bacilli, fungi, spirochetes, and rhinoscleroma should be performed.**
- **If atypical lymphocytes are seen EBV tests may be indicated.**
- **There are limitations for pathologists in evaluating necrotic sinonasal lesions – MULTIPLE BIOPSIES MAY BE NEEDED TO LEAD TO DEFINITIVE DX**

CASE 3

- A 47 year old woman complained to her dentist of a painless lump on her palate, which she noticed for about one year.
- The lesion appeared firm and was smooth with a normal looking overlying mucosa.
- Biopsy was taken.

SALIVARY GLAND: THE MIMICS

SALIVARY GLAND: THE MIMICS

- **Benign mixed tumor (pleomorphic adenoma)**
- Monomorphic adenoma (including myoepithelioma)
- **Adenoid cystic carcinoma**
- **Polymorphous lowgrade adenocarcinoma**
- Hyalinizing clear cell carcinoma
- Epimyoepithelial carcinoma

SALIVARY GLAND: THE MIMICS

- IMPORTANT PEARL:
- Biopsy of palate salivary gland lesions may not be diagnostic because of *histologic* overlap.
- Preferred diagnosis: Salivary gland neoplasm (comment on differential and indicate final diagnosis needs resection)

SALIVARY GLAND: THE MIMICS

- **BIOPSY OF PALATE**
- Can diagnose as malignant if
  - See infiltrative growth into muscle
  - See perineural invasion

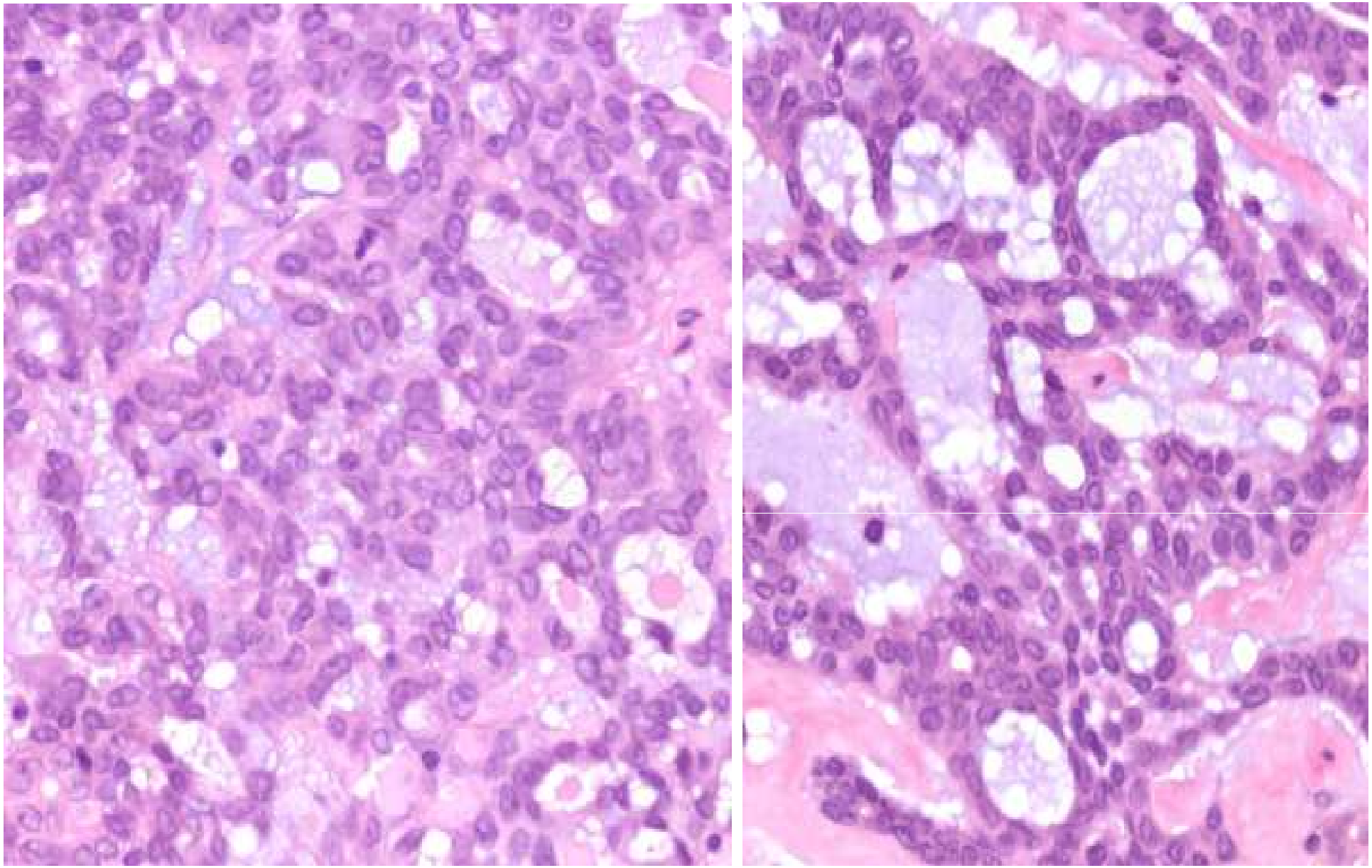

PALATE TUMOR BIOSPY CASE 2

SALIVARY GLAND: THE MIMICS

- ***BENIGN MIXED TUMOR***
  - Most common salivary gland tumor
  - Most frequent benign salivary gland tumor
  - Most often involves parotid, but may occur in any salivary gland
  - Male:Female ratio: 1:2-3
  - Age range: wide, including children
  - Symptoms: usually painless lump

SALIVARY GLAND: THE MIMICS

- ***BENIGN MIXED TUMOR***
- **GROSS**

  Firm circumscribed mass

  Resembles cut surface of potato

  May see foci “hernia” at edges

SALIVARY GLAND: THE MIMICS

- ***BENIGN MIXED TUMOR***
- **MICROSCOPIC**
- Multiple patterns
  - Chondromyxoid, epithelial, cellular
  - Glandular, spindle cells, oncocytes, squamous, mucinous.

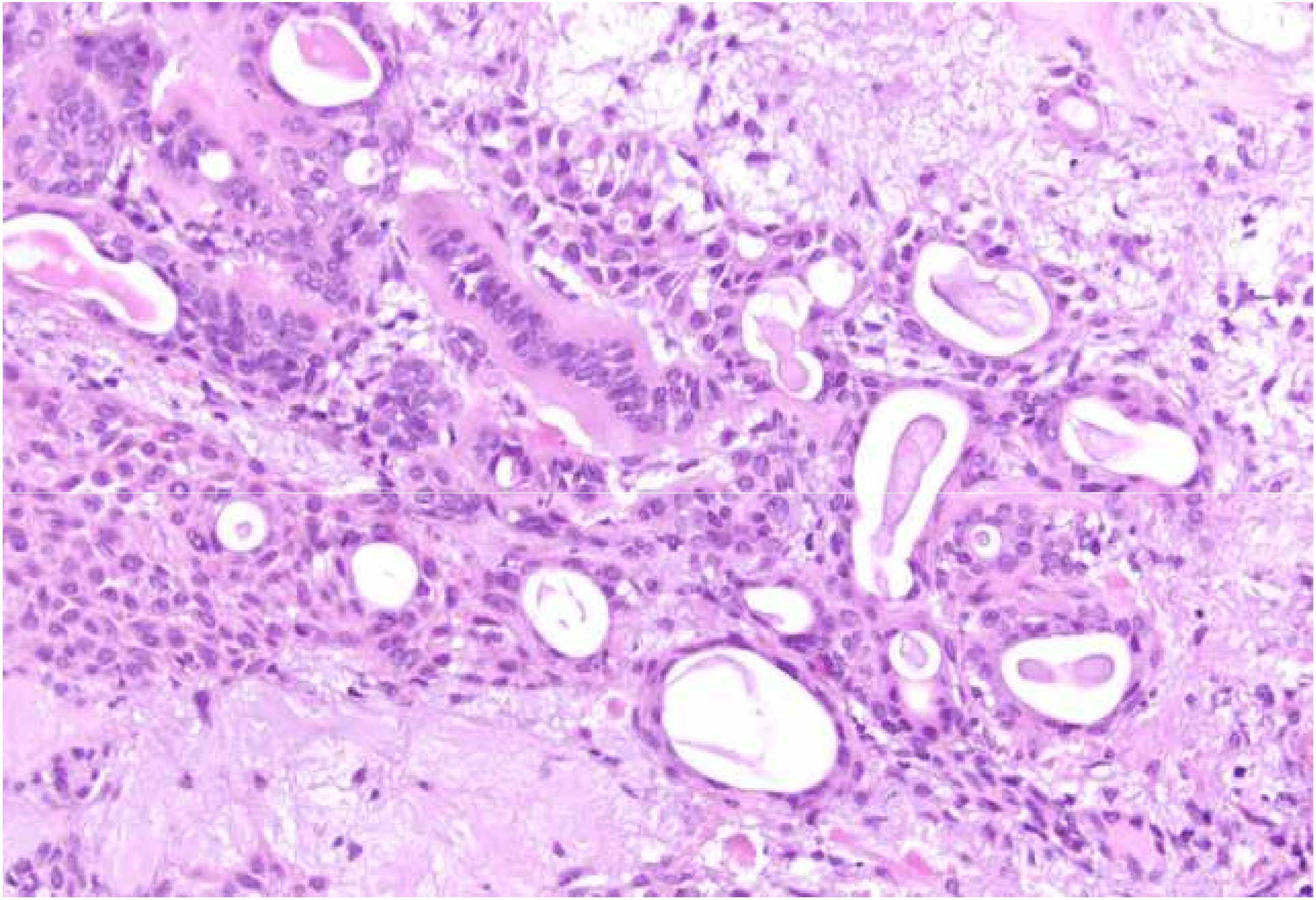

BENIGN MIXED TUMOR

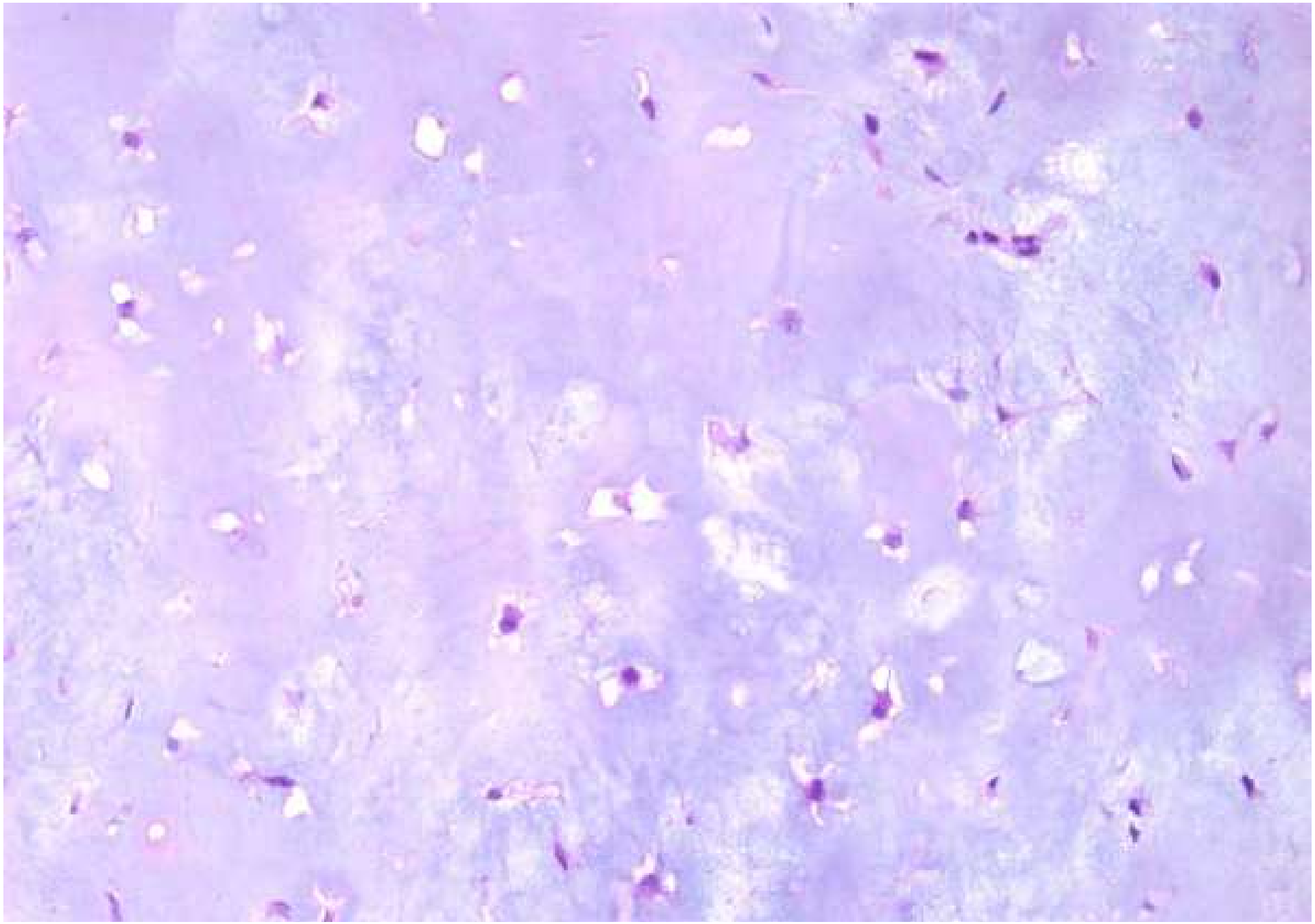

BENIGN MIXED TUMOR CHONDROID

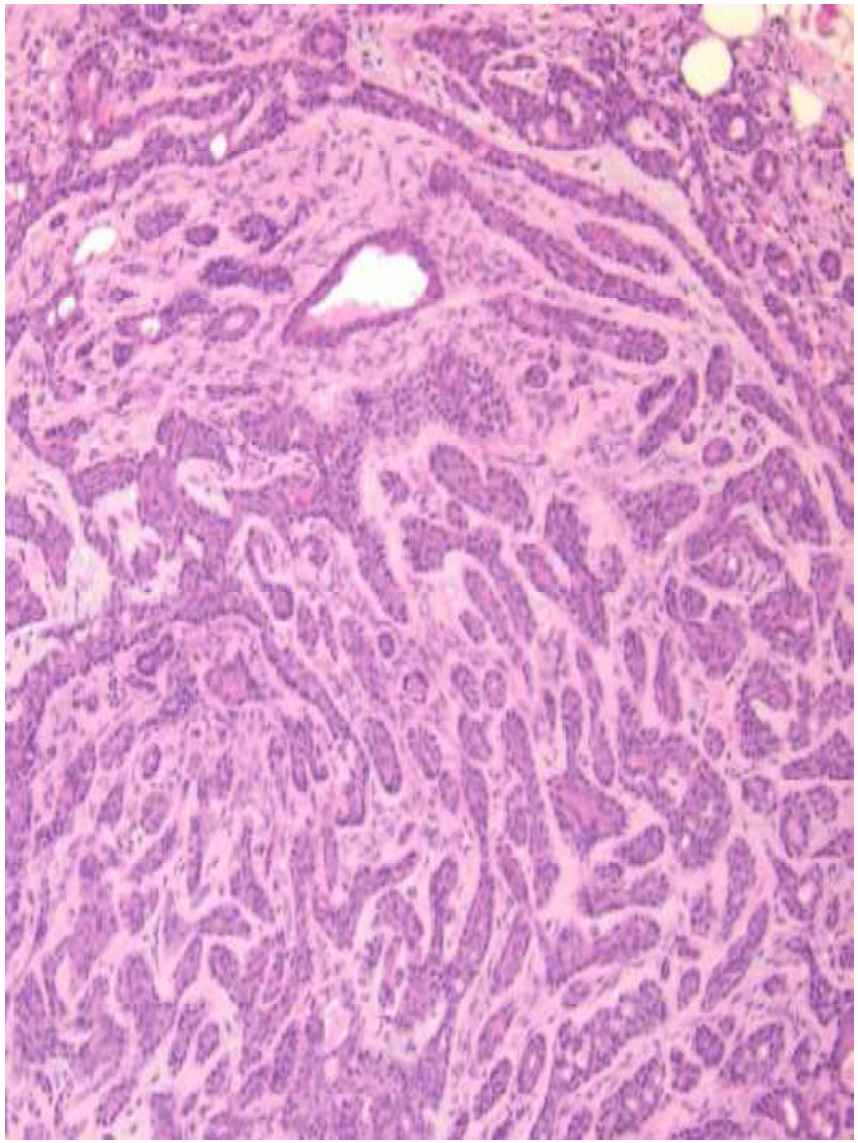

EPITHELIAL RICH PATTERNS

BENIGN MIXED TUMOR

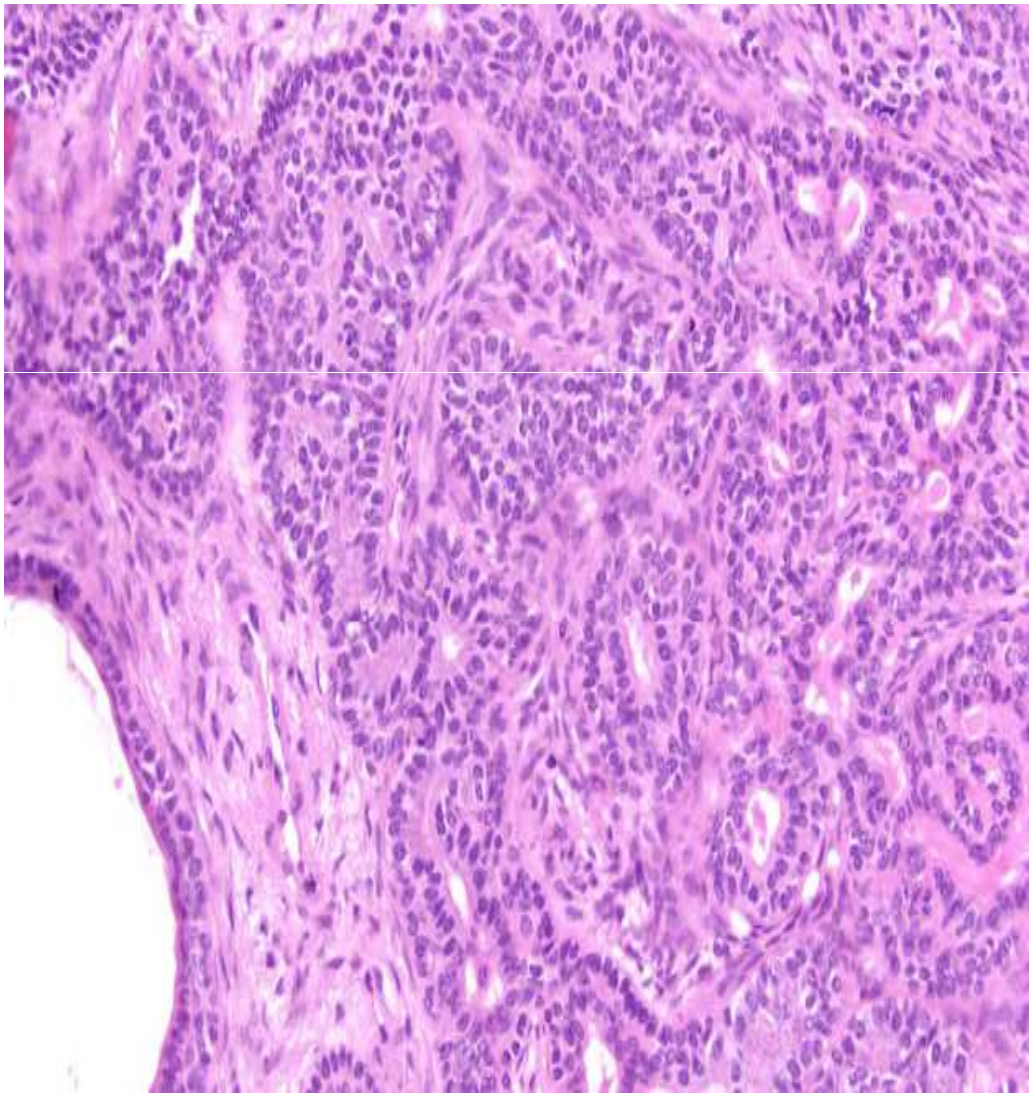

SALIVARY GLAND: THE MIMICS

- ***BENIGN MIXED TUMOR***
- **MICROSCOPIC**
- Usually circumscribed.
- Often have pseudopods or “herniations” at the edge.
- If enucleated or ruptured, these can be left behind ***RECURRENCE***

SALIVARY GLAND: THE MIMICS

- **BENIGN MIXED TUMOR**
- Can recur and be difficult to extirpate but still be benign
- Can undergo transformation to malignancy

usually carcinoma:

MALIGNANT MIXED TUMOR

CARCINOMAS: Adenocarcinma, NOS; squamous carcinoma, NOS; adenosquamous carcinoma; salivary duct carcinoma.

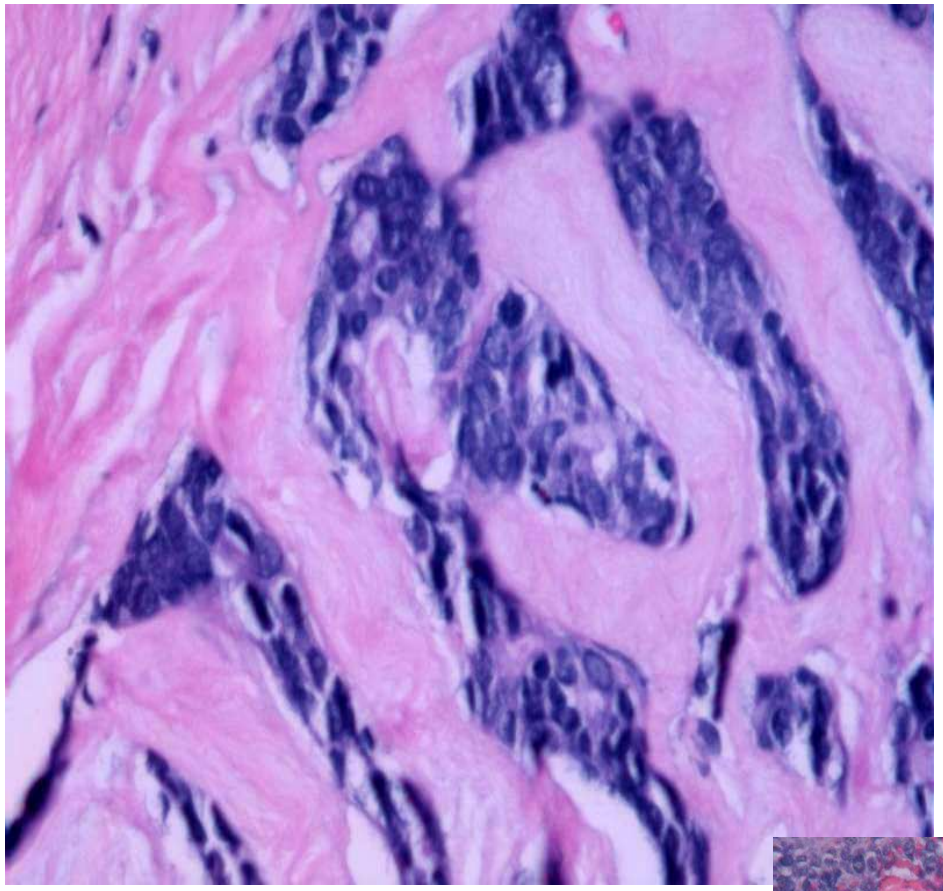

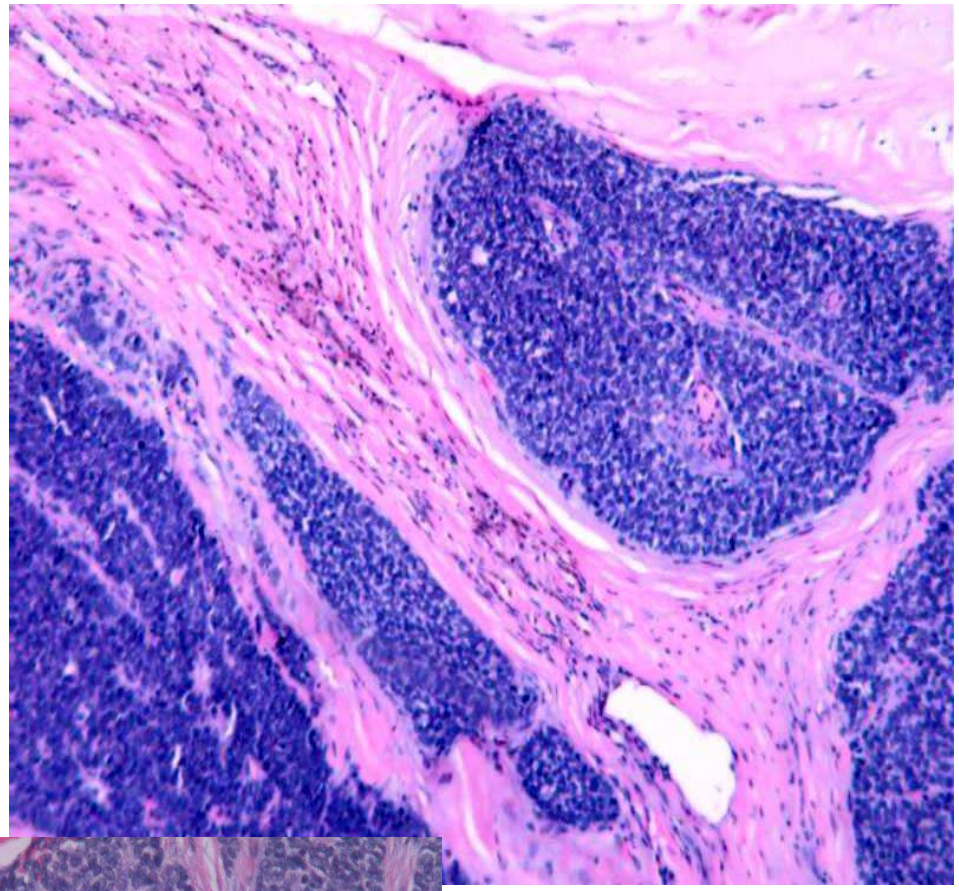

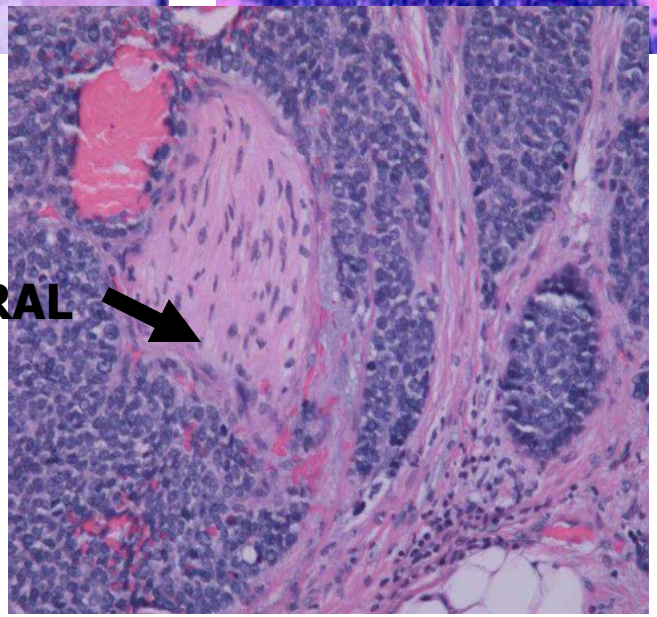

PERINEURAL

CARCINOMA EX MT

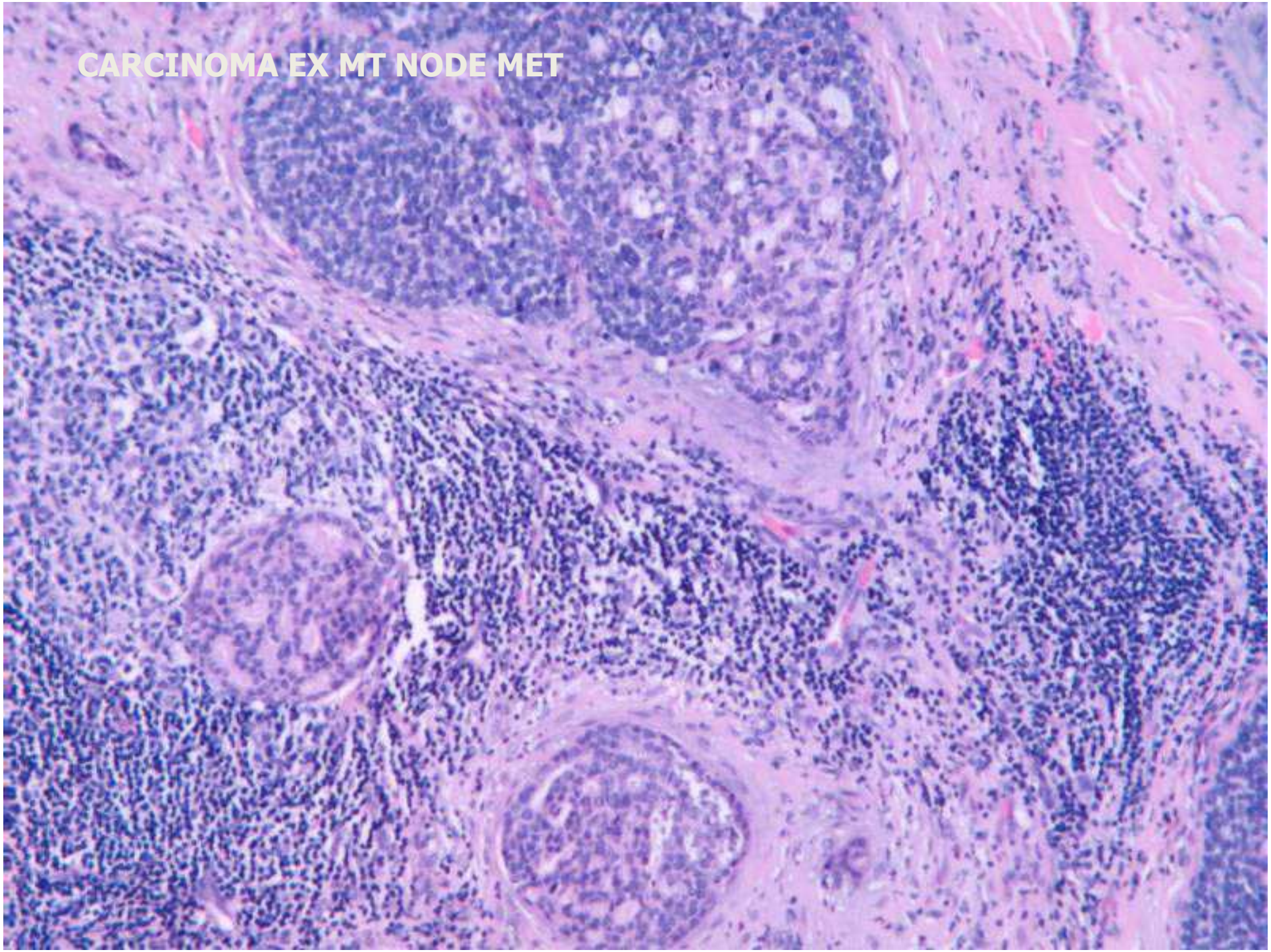
CARCINOMA EX MT NODE MET

SALIVARY GLAND: THE MIMICS

- ***BENIGN MIXED TUMOR***
- When transformation occurs or when CIS,

  note hyalinization, hemorrhage, cellular atypia and anaplasia, and +/- necrosis.

  The necrosis and hyalinization may be grossly seen.

  (ESPECIALLY IF NO FNA).

SALIVARY GLAND: THE MIMICS

- ***BENIGN MIXED TUMOR***
- OTHER
- Cellular mixed tumor—mitoses
- Carcinoma in-situ

SALIVARY GLAND: THE MIMICS

- ***CELLULAR BMT***
  - **Usually heavily epithelial**
  - **Often spindly cells**
  - **May have mitoses**
  - **No necrosis or pleomorphism**
  - **No invasion**
  - **?More likely to recur**

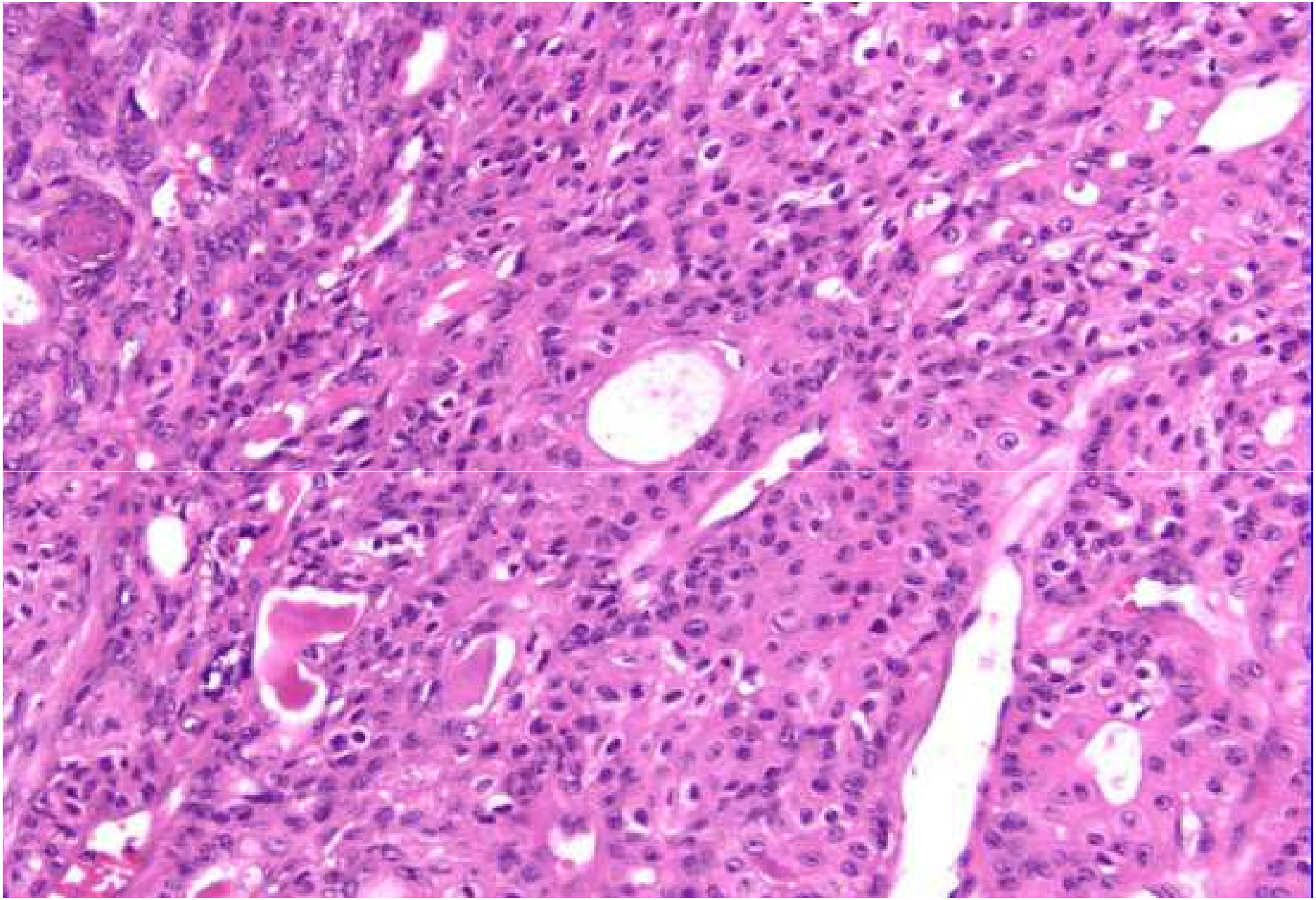

CELLULAR MIXED TUMOR

SALIVARY GLAND: THE MIMICS

- ***BENIGN MIXED TUMOR***
- OTHER
- Cellular mixed tumor—mitoses
- Carcinoma in-situ

SALIVARY GLAND: THE MIMICS

- **Carcinoma in situ in mixed tumor**
- ***Two definitions:***
  - Cytologic change only; no stromal invasion.
  - Invasive carcinoma with stromal invasion but confined within the capsule of the BMT.

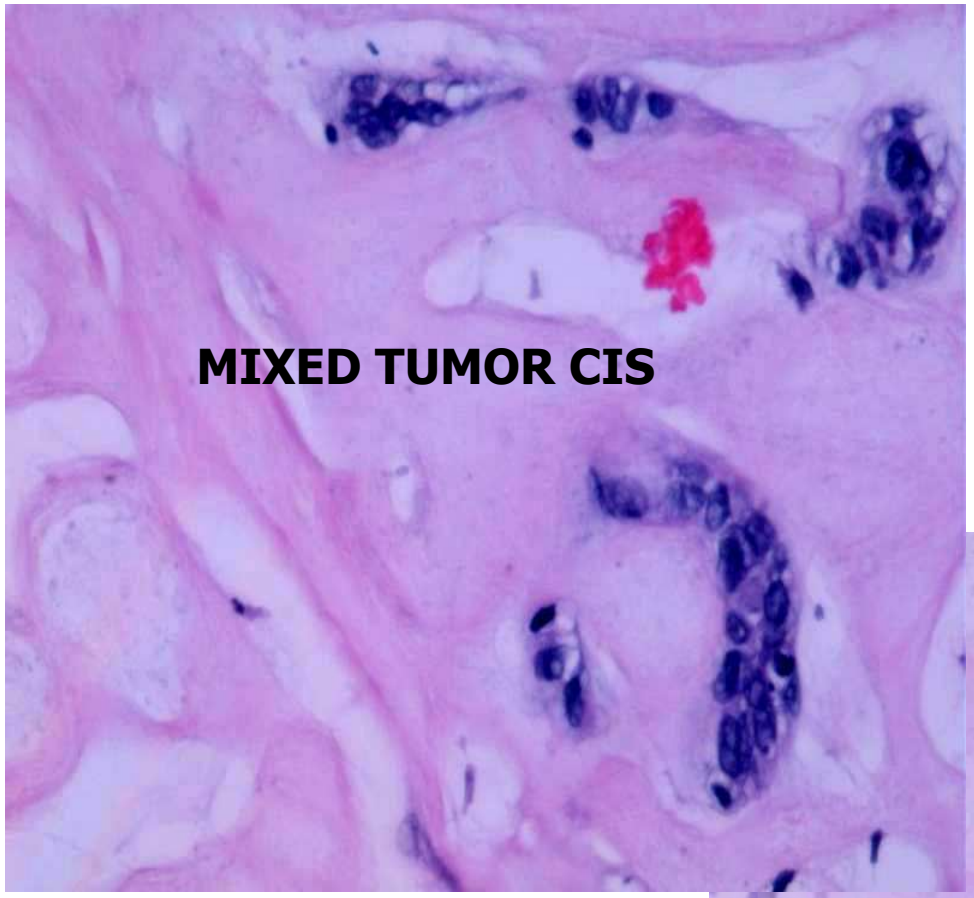
MIXED TUMOR CIS

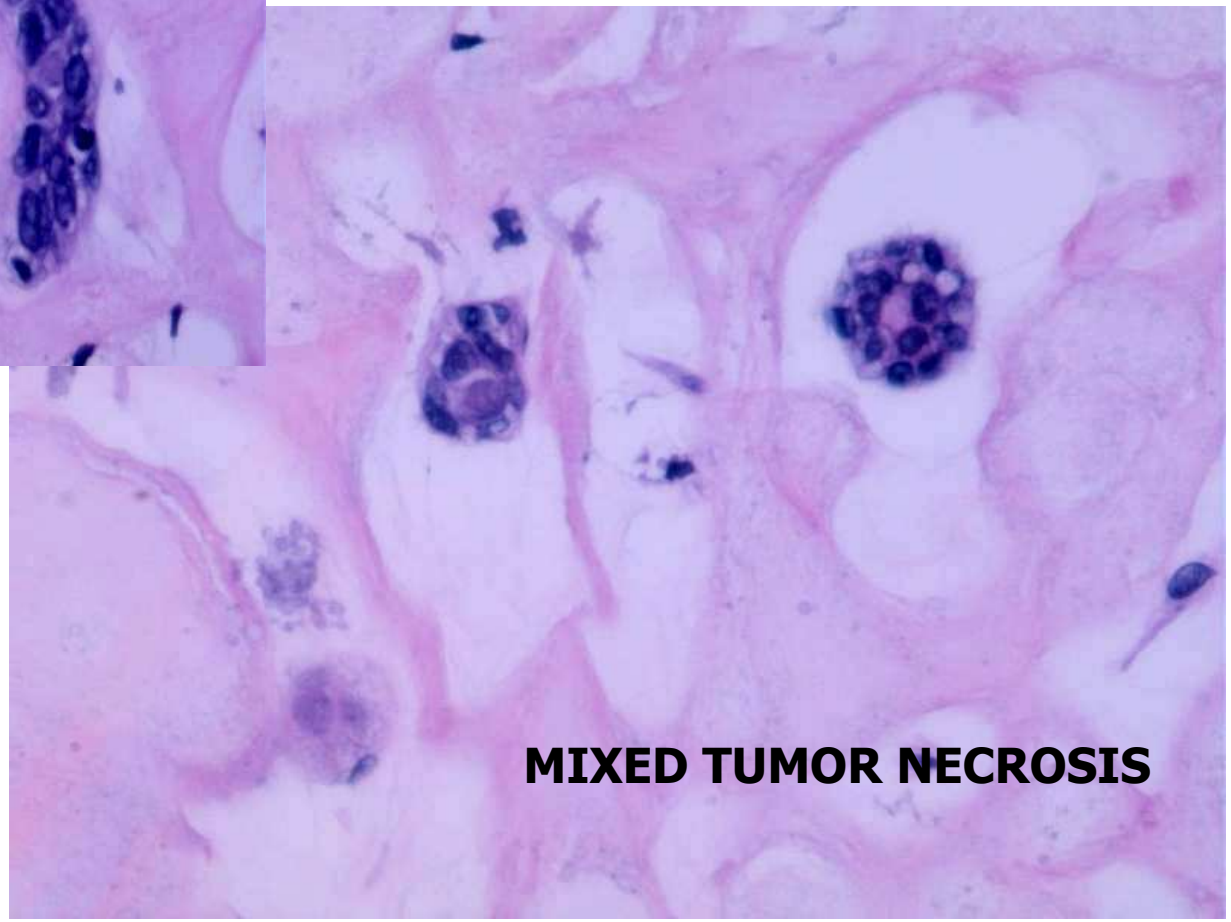
MIXED TUMOR NECROSIS

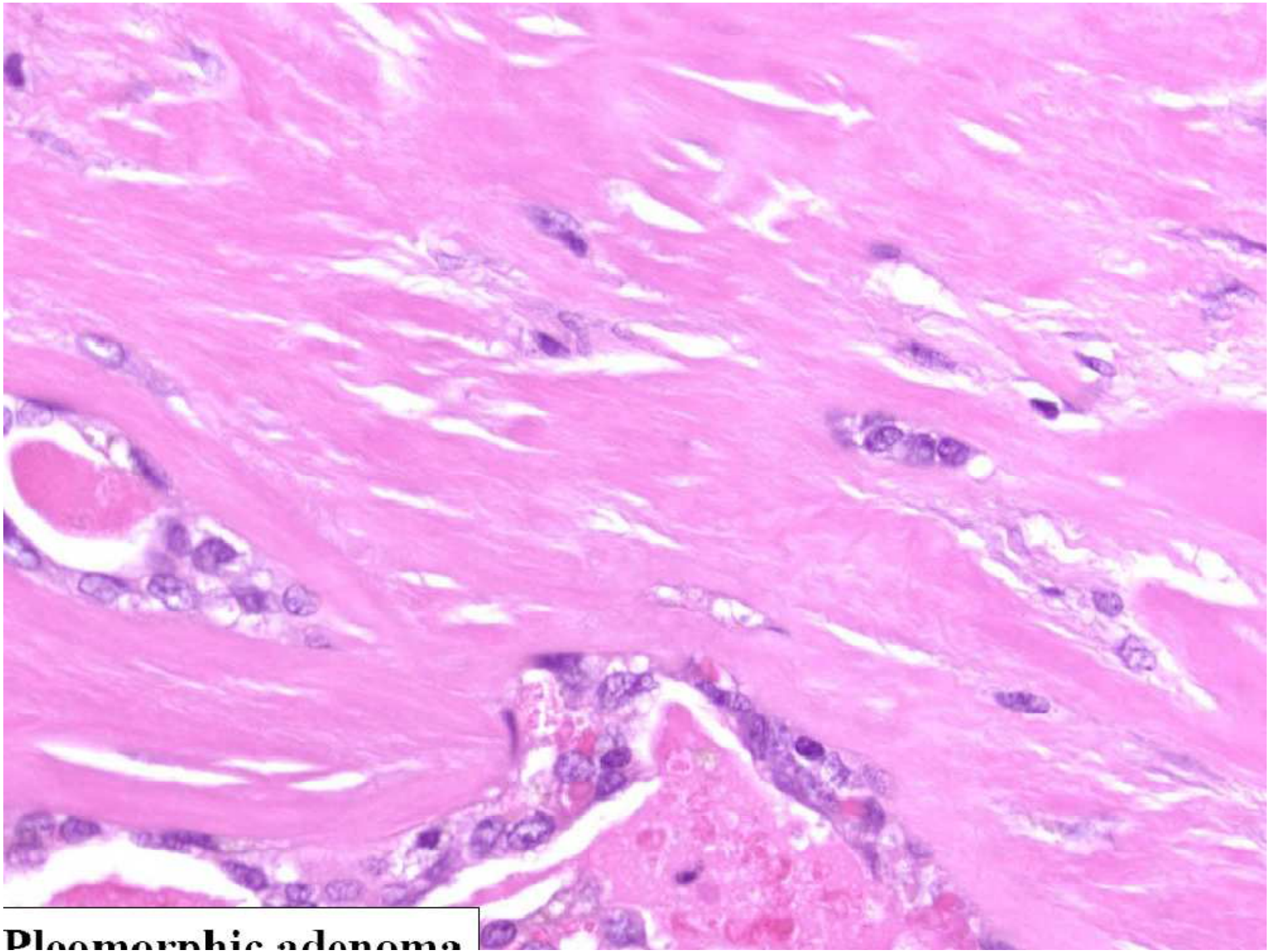

Pleomorphic adenoma

SALIVARY GLAND: THE MIMICS

- ***TRANSFORMATION*** DIFFERENT FROM RECURRENCE OF BENIGN MIXED TUMOR

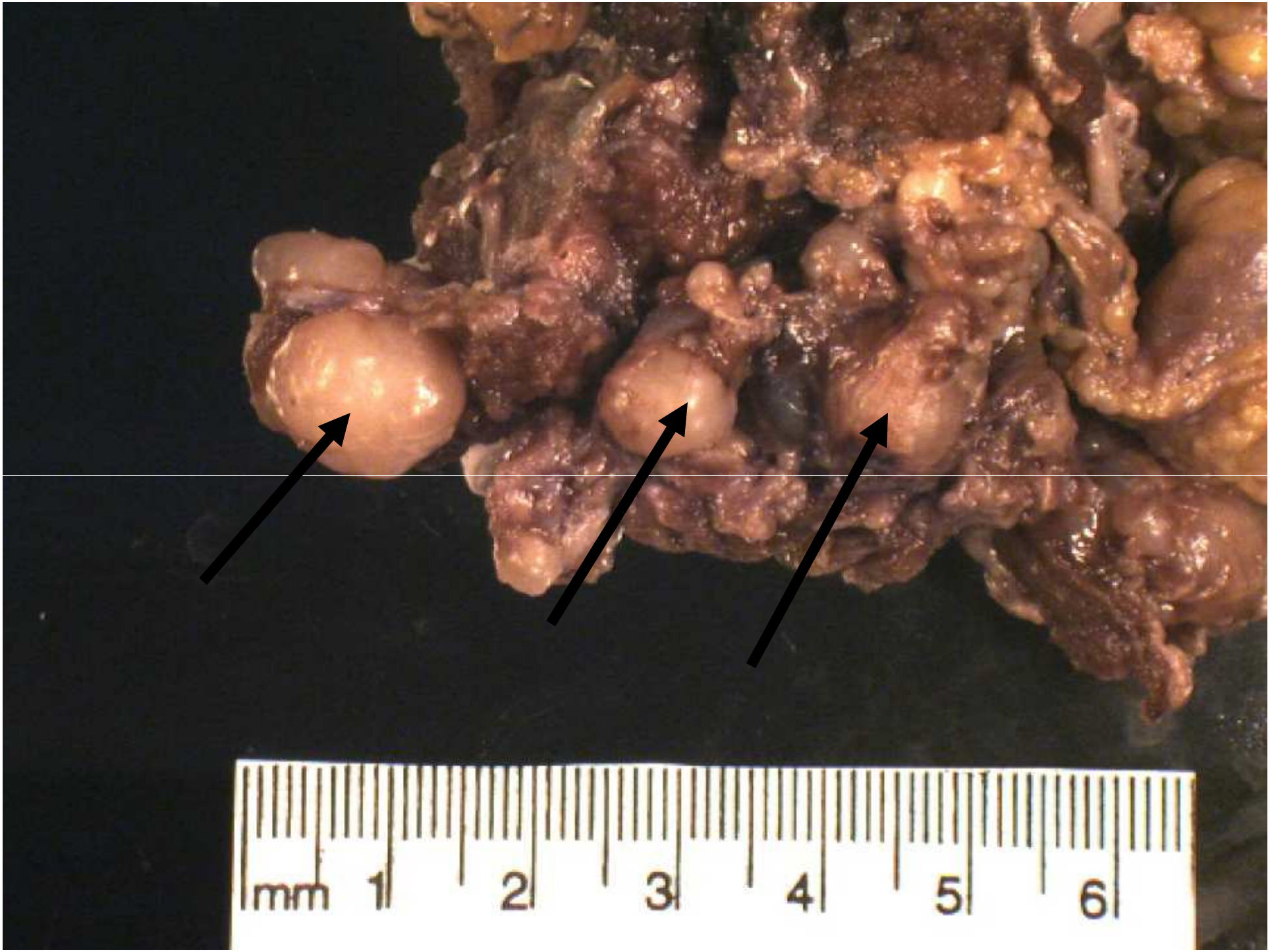
mm 1
2
3
4
5
6

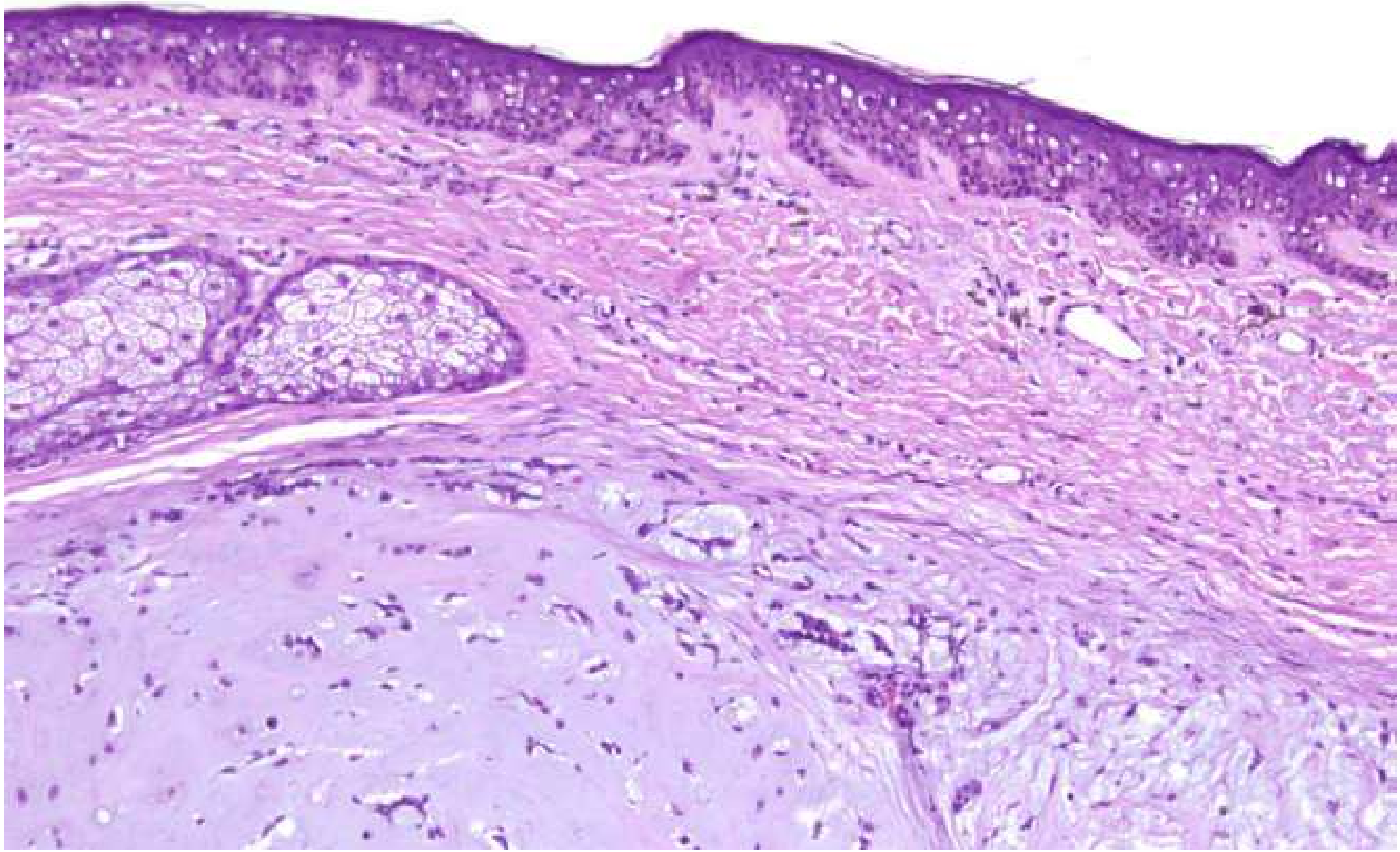

RECURRENT BENIGN MIXED TUMOR IN SKIN

SALIVARY GLAND: THE MIMICS

- **ADENOID CYSTIC CARCINOMA**

SALIVARY GLAND: THE MIMICS

- ***ADENOID CYSTIC CARCINOMA***
- **CLINICAL FEATURES**
  - Second most common salivary gland carcinoma; any salivary gland
  - Mass lesion
  - Nerve palsies

SALIVARY GLAND: THE MIMICS

- ***ADENOID CYSTIC CARCINOMA***
- **GROSS**
  - **Mass lesion**
  - **Infiltrative**

SALIVARY GLAND: THE MIMICS

- ***ADENOID CYSTIC CARCINOMA***
- **MICROSCOPIC**
  - Multiple patterns: tubular, cribriform, solid
  - Peri- and intraneural invasion
  - Epithelial cells have open nuclei whereas myoepithelial cells have dark angulated ones

SALIVARY GLAND TUMORS

- ***ADENOID CYSTIC CARCINOMA***
- **MICROSCOPIC:**
- **GRADING:**
  - Grade 1 ---tubular
  - Grade 2 ---cribriform
  - Grade 3 ---solid
  - Dedifferentiated nuclear pleomorphism; p53 mutations

SALIVARY GLAND: THE MIMICS

- ***ADENOID CYSTIC CARCINOMA***
- **PROGNOSIS**
  - ***Related to grade***
  - **Prolonged usually**
  - **Rarely cured**
  - **Treatment is surgical; margins problem because of neural invasion**
  - **Radiation may be added.**
  - **10 year survival about 70%; 20 year about 30%**

SALIVARY GLAND TUMORS

- ***ADENOID CYSTIC CARCINOMA***
  - **PROGNOSIS**
    - **Distant metastases to lung, liver, bone and brain.**
    - **May be amenable to surgical excision (especially lung and liver).**
    - **No successful chemotherapy—c KIT saga.**
    - **If tumor dedifferentiates, bad prognosis and rapid demise.**

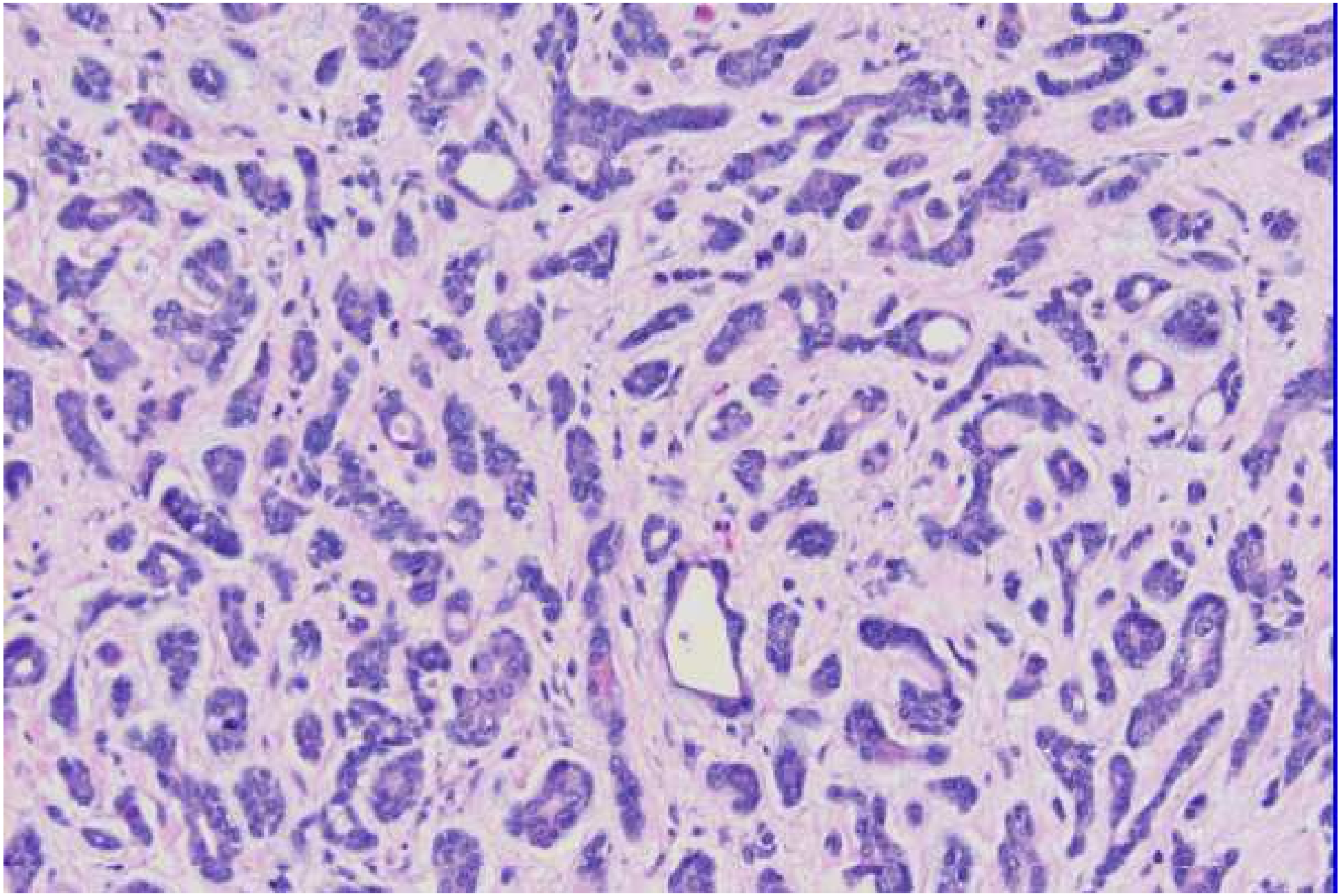

ADENOID CYSTIC CARCINOMA: TUBULAR PATTERN

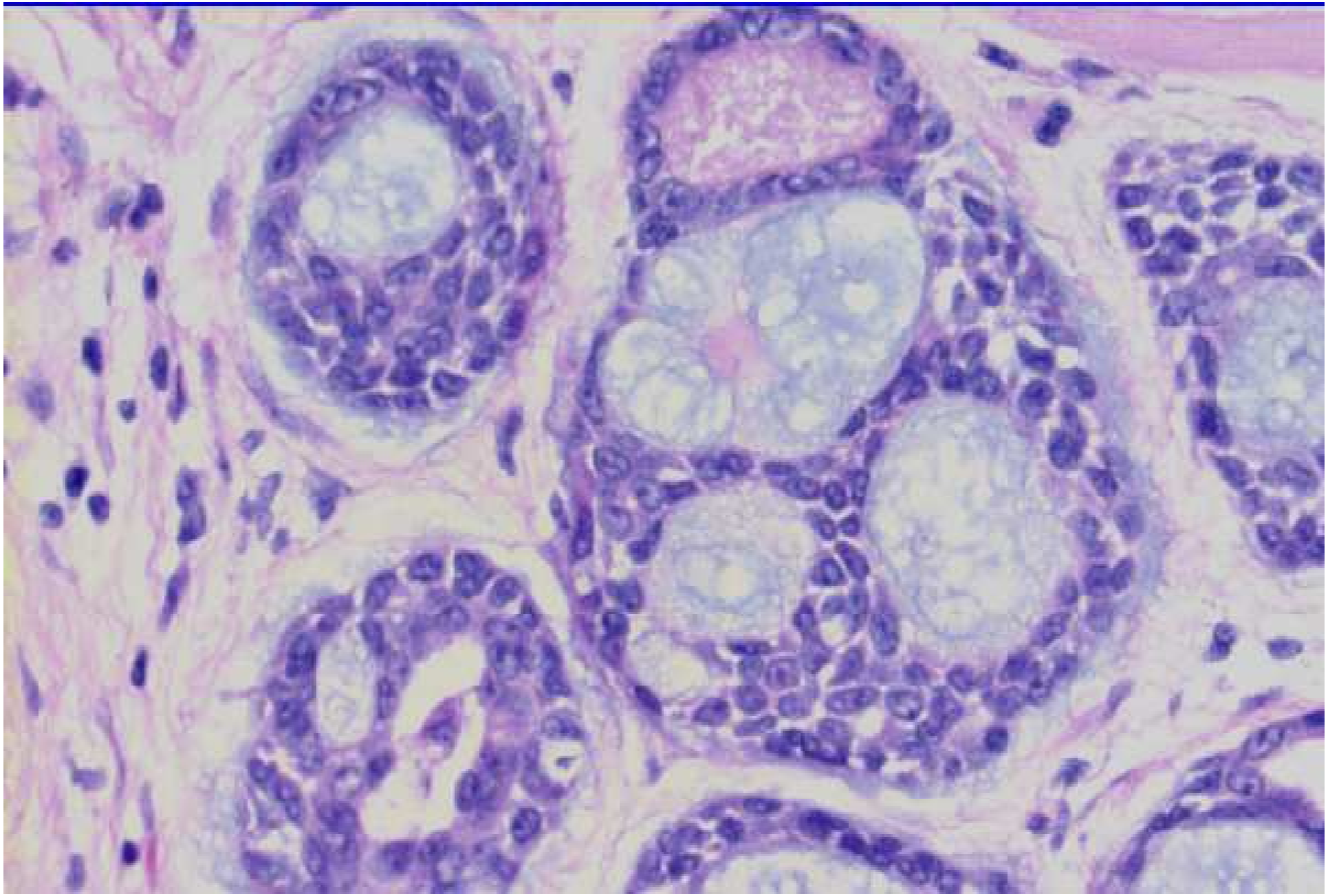

ADENOID CYSTIC CARCINOMA: CRIBRIFORM PATTERN

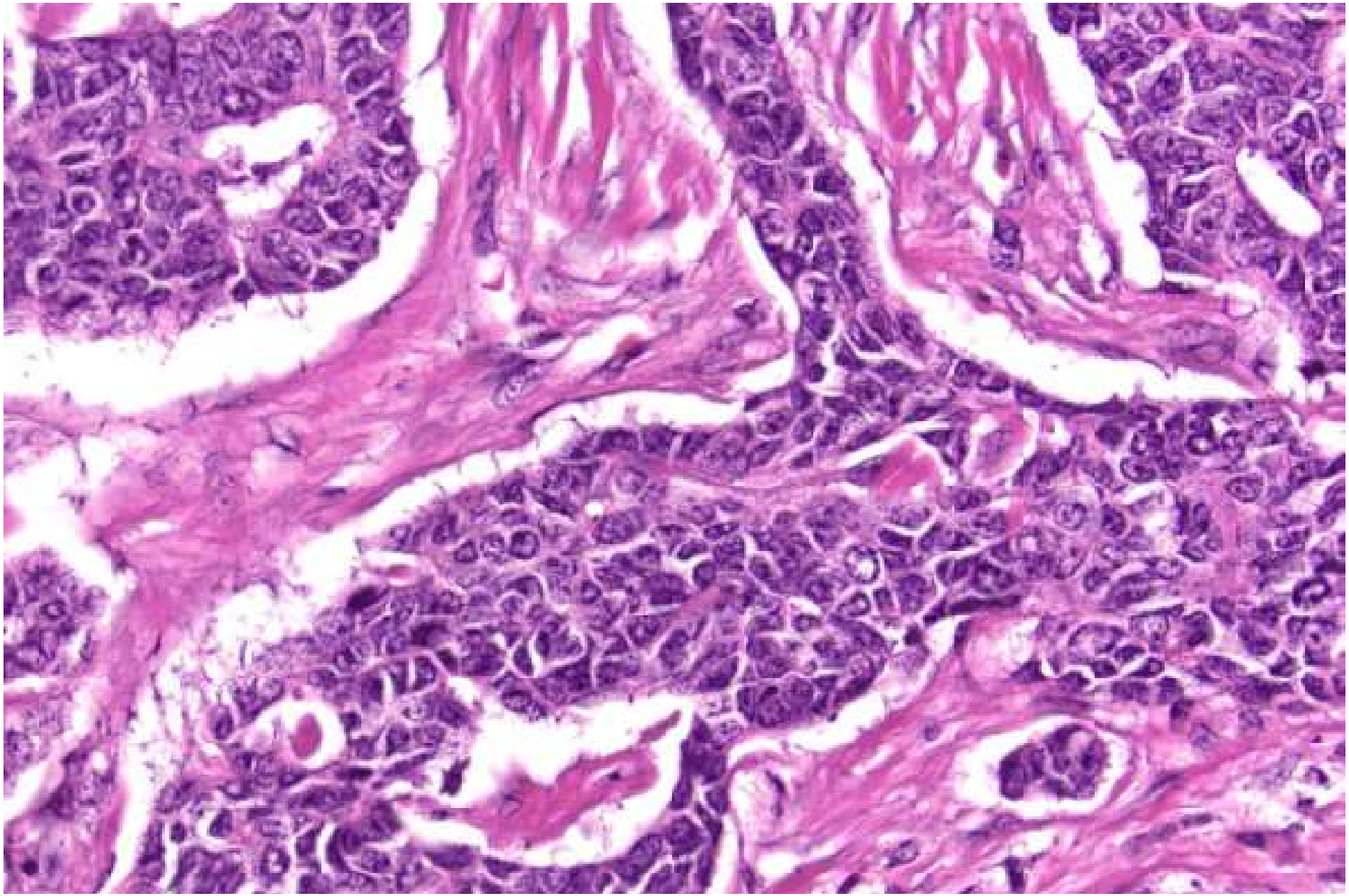

ADENOID CYSTIC CARCINOMA: SOLID PATTERN

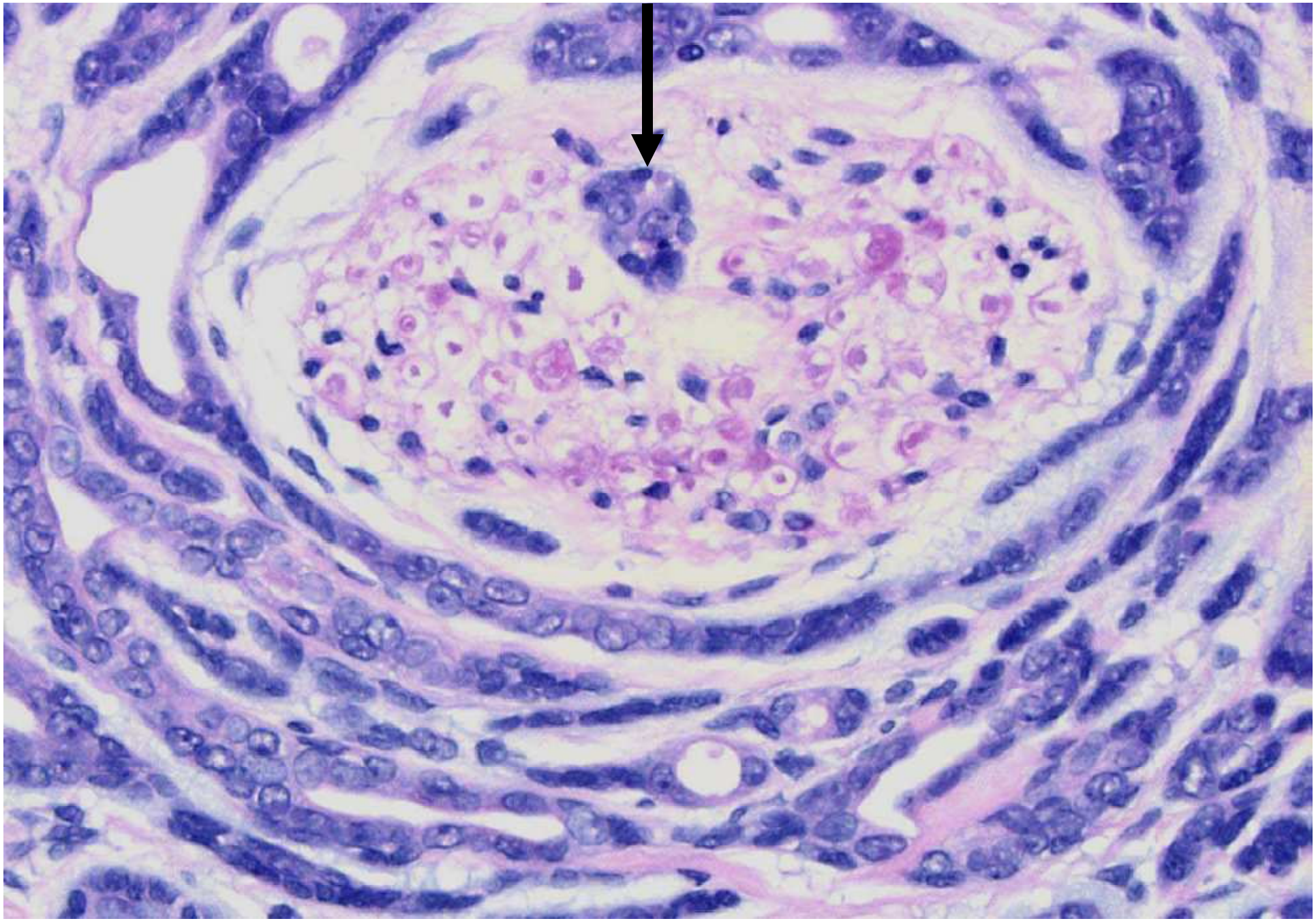

ADENOID CYSTIC CARCINOMA: PERINEURAL AND INTRANEURAL INVASION

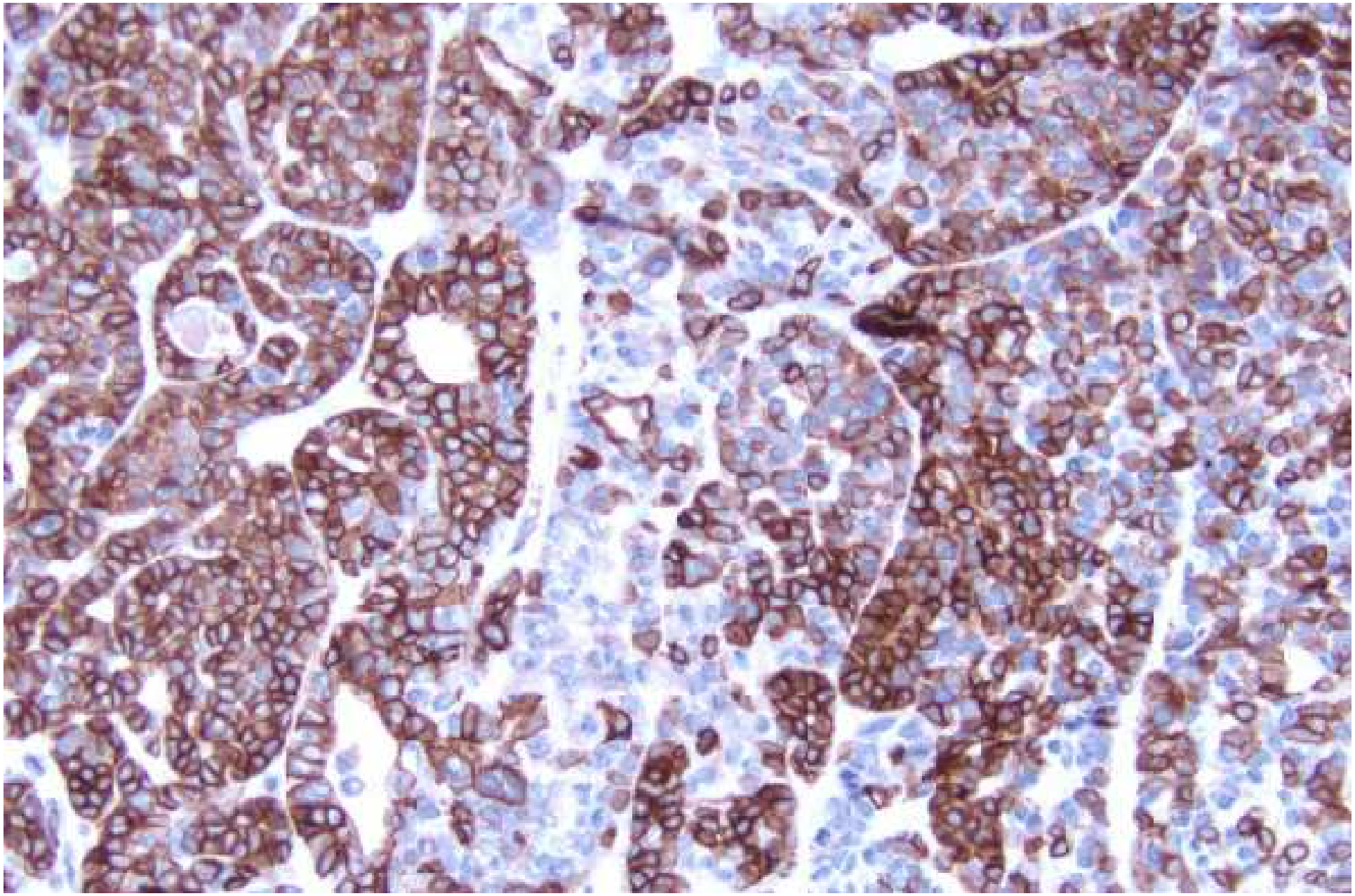

ADENOID CYSTIC CARCINOMA: c KIT

SALIVARY GLAND TUMORS

- ***ADENOID CYSTIC CARCINOMA***

- **DEDIFFERENTIATION**

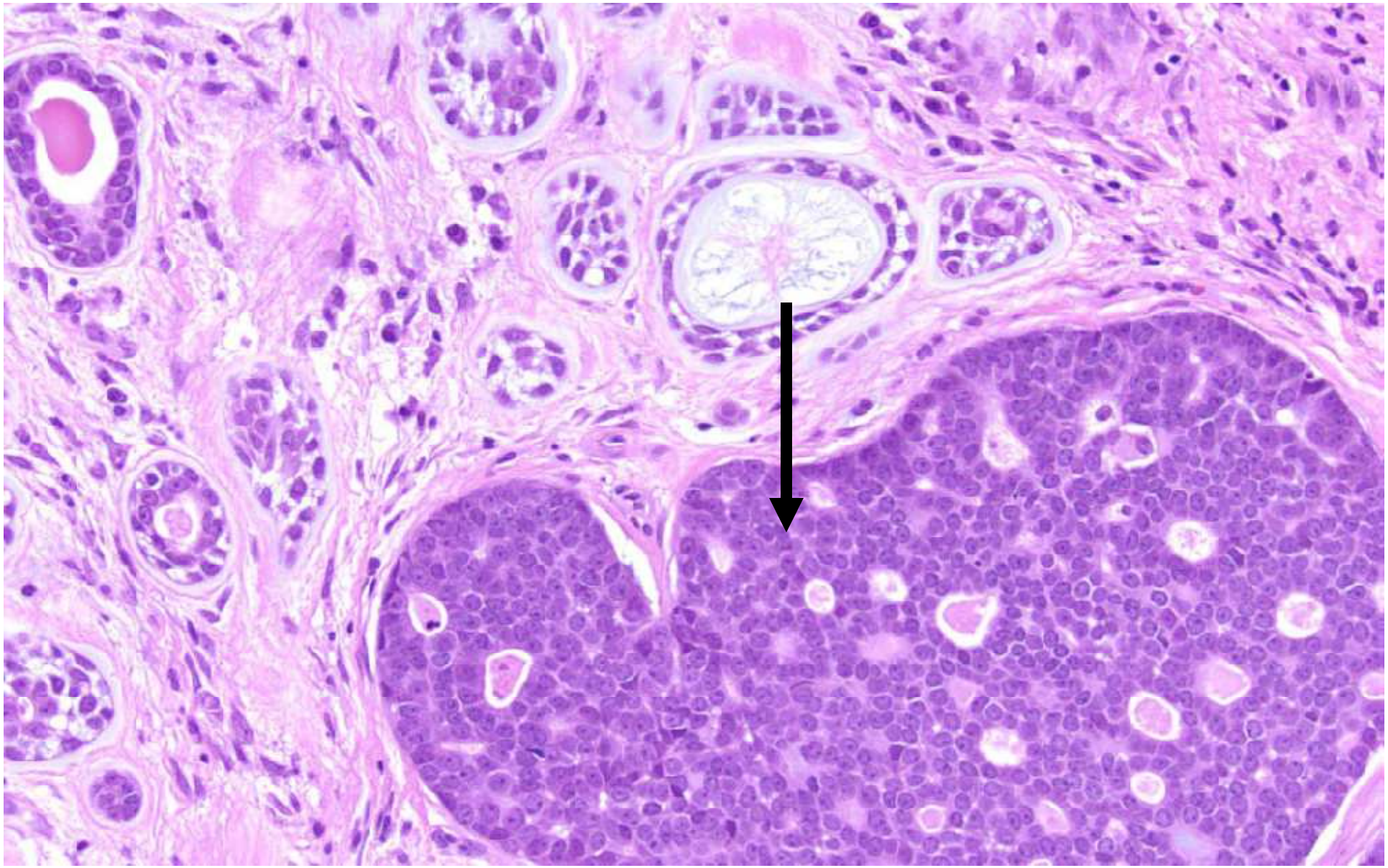

ADENOID CYSTIC CARCINOMA WITH DEDIFFERENTIATION

SALIVARY GLAND: THE MIMICS

- ***POLYMORPHOUS LOWGRADE ADENOCARCINOMA***
- **CLINICAL**
  - **Mass lesion usually in palate**
  - **Other names:**
  - **Terminal duct carcinoma**
  - **Lobular carcinoma**
  - **Papillary adenocarcinoma (probably not PLGA)**

SALIVARY GLAND: THE MIMICS

- ***POLYMORPHOUS LOWGRADE ADENOCARCINOMA***
- **MICROSCOPIC**
  - **Mixed growth patterns**
  - **Glandular, tubular**
  - **Open nuclei**
  - **Perineural invasion**

SALIVARY GLAND: THE MIMICS

- ***POLYMORPHOUS LOWGRADE ADENOCARCINOMA***
- **SPECIAL STAINS**
  - Bcl2 positive
  - S100 positive
  - GFAP negative
  - cKIT rare positive

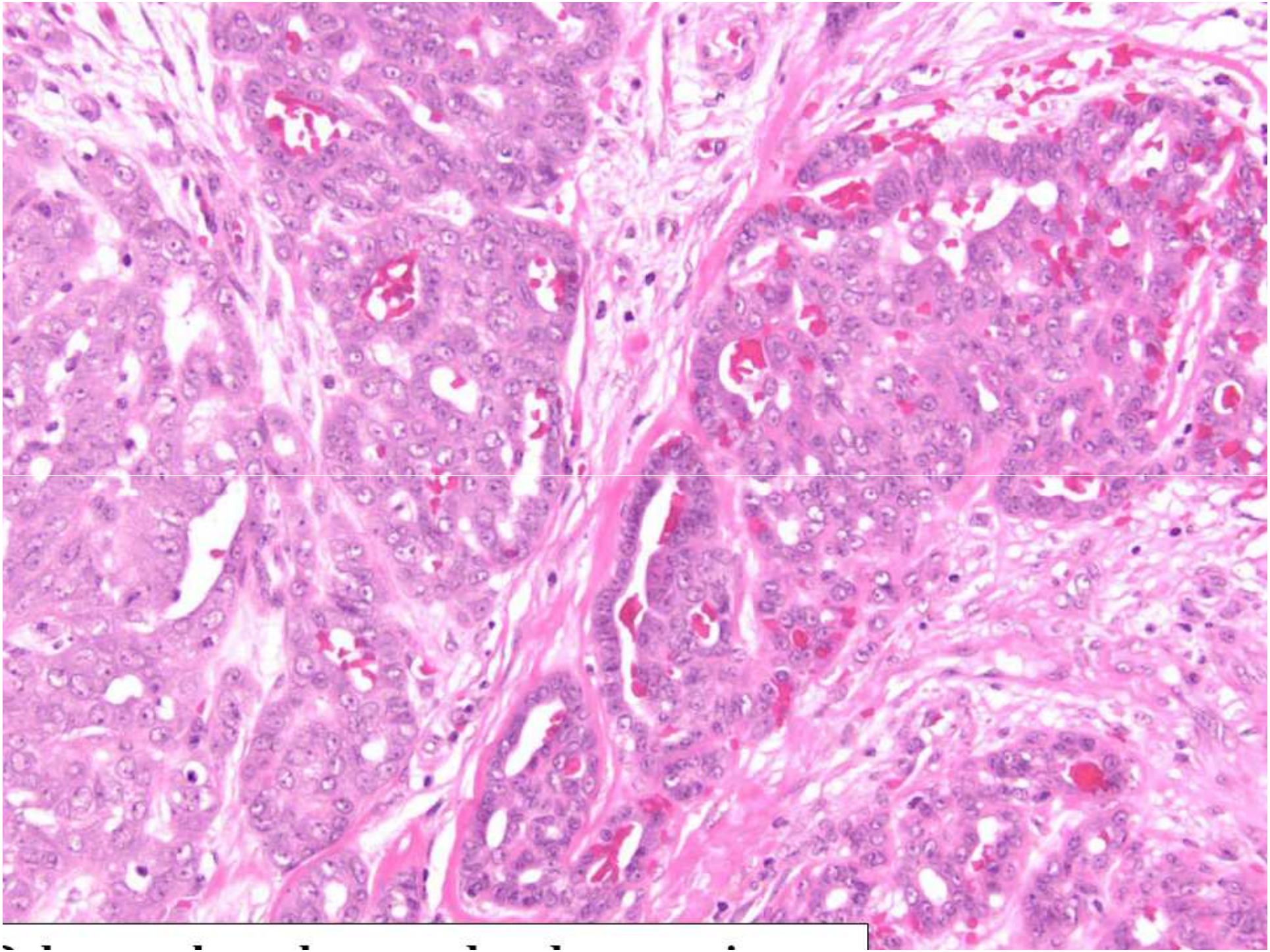

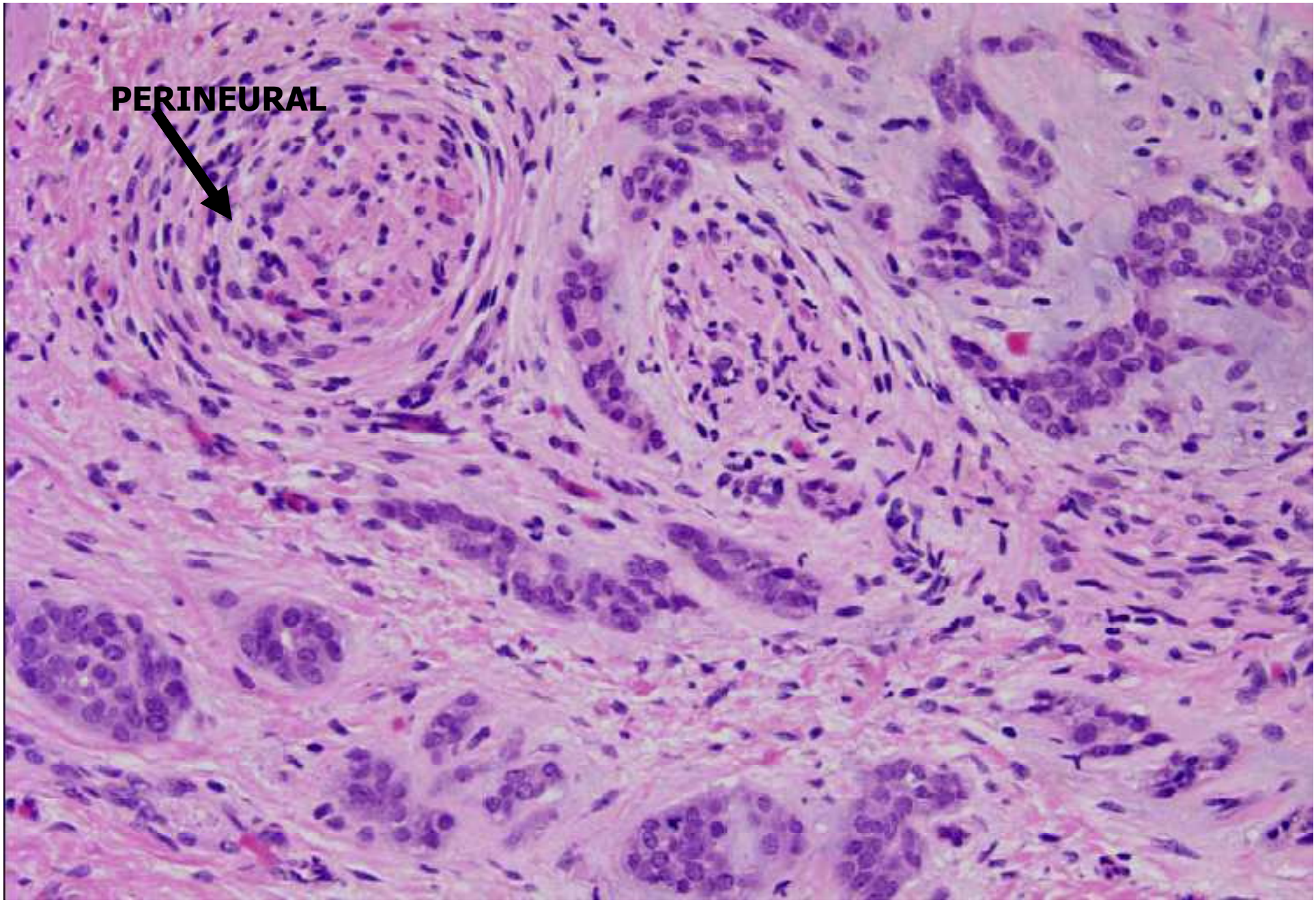

POLYMORPHOUS LOWGRADE ADENOCARCINOMA

SALIVARY GLAND: THE MIMICS

- ***POLYMORPHOUS LOWGRADE ADENOCARCINOMA***
- **PROGNOSIS**
  - **Often long course; good prognosis**
  - **If excised with good margins, may be cured**
  - **Recurrence late can be seen**
  - **Rare lymph node met 10-15%**
  - **Even rarer, distant mets**

SALIVARY GLAND: MIMICS

Feature	ACC	PLGA	BMT
Tubules	+	+	+
Invasion	+	+	-
Matrix	+	+	Chondroid
Cytology	Small, angulated, dark	Open nuclei, bland	Two cell types

SALIVARY GLAND: MIMICS

STAIN	ACC	PLGA	BMT
SMA	+	-	+
Calponin; p63	+	-	+
Ckit	+	+/-	-
GFAP	-	_	+
S100	Myoep	Diffuse	Myoep

SALIVARY GLAND: MIMICS

- **RARE TUMORS**
- **Hyalinizing clear cell carcinoma**

SALIVARY GLAND: MIMICS

- **Hyalinizing clear cell carcinoma**
  - **Occurs in oral cavity**
  - **Most in females**
  - **Indolent malignancy**
  - **By IHC, keratin + and negative for myoepithelial markers.**
  - **(Mardi and Sharma 2008)**

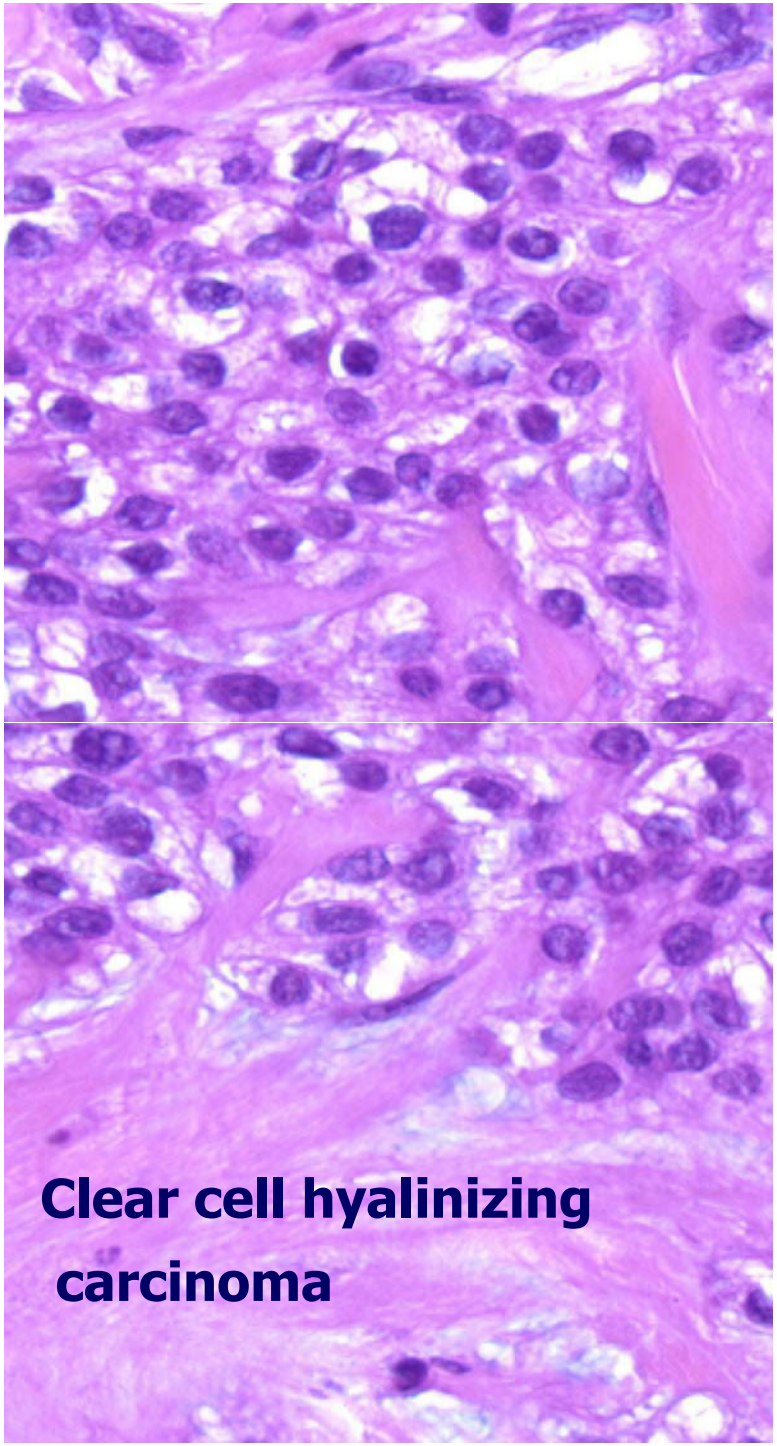
Clear cell hyalinizing
carcinoma

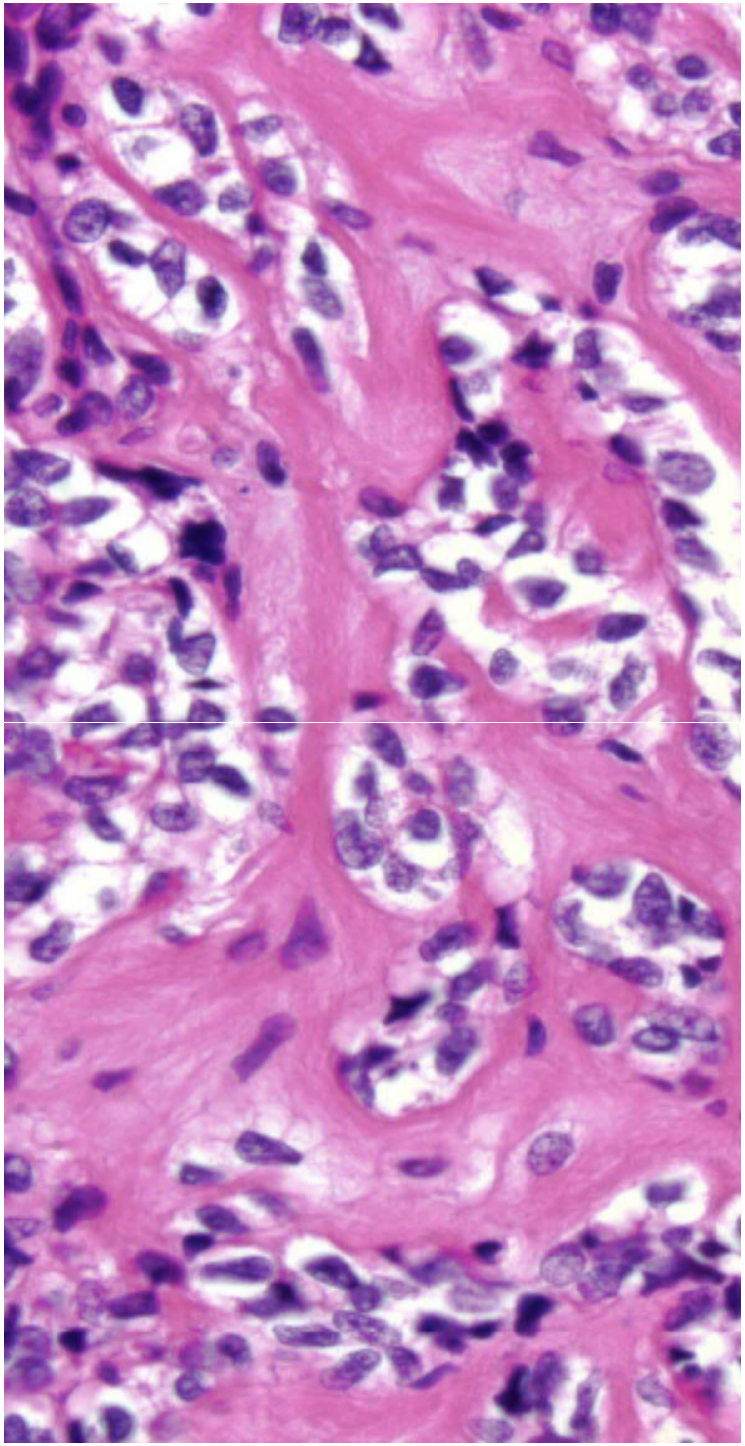

SALIVARY GLAND: MIMICS

- ***EPIMYOEPITHELIAL CARCINOMA***
- **Rare biphasic tumors that contain both epithelial cells and myoepithelial cells that lined ducts in two layers.**
- **Ducts are characteristically surrounded by dense basement membrane material.**
- **The tumor can be difficult to distinguish from adenoid cystic carcinoma; may stain for c Kit.**
- **Considered low grade with 25% node metastases and a 70% or more survival rate**

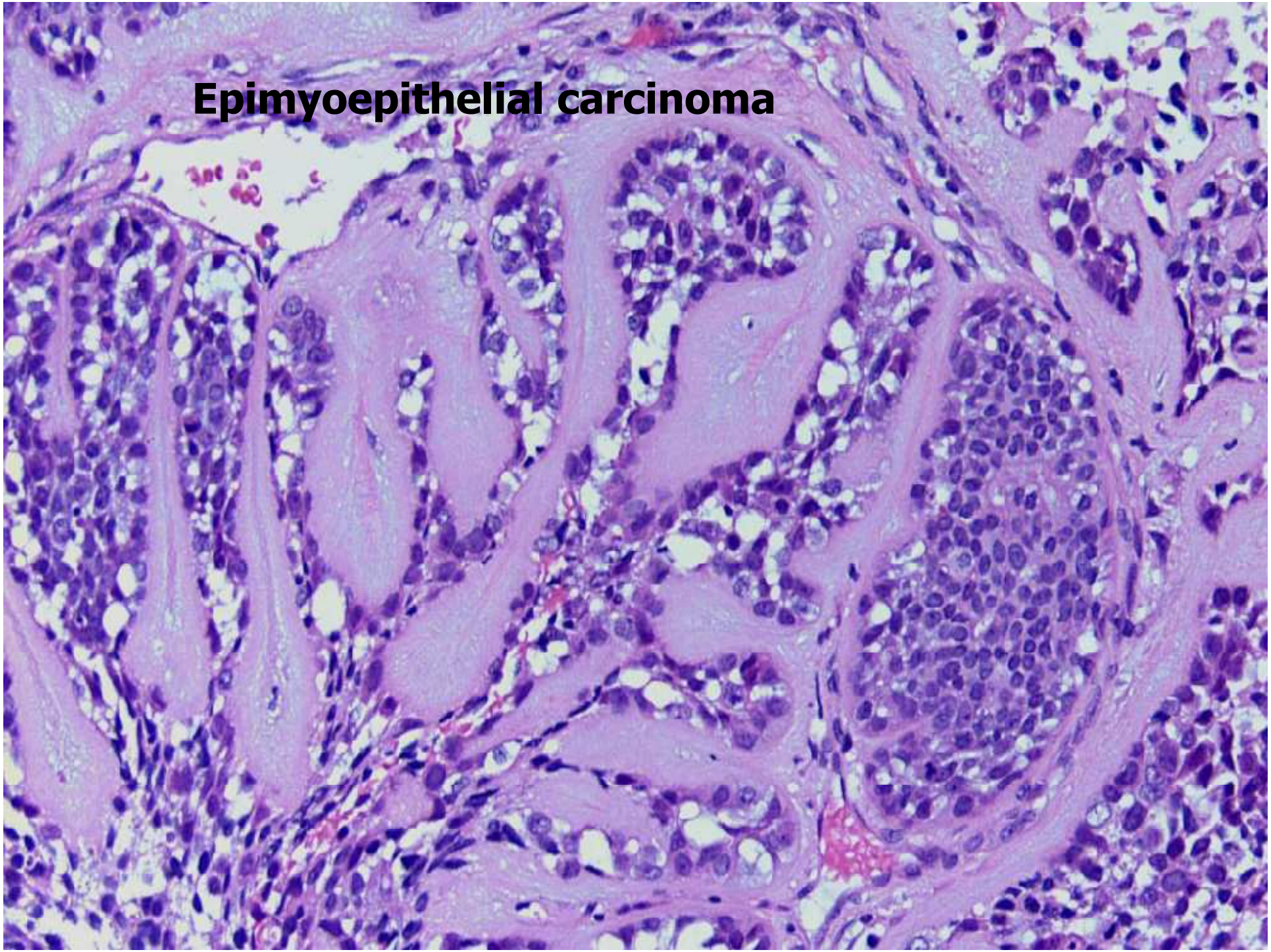
Epimyoepithelial carcinoma

SALIVARY GLAND TUMORS

- **WHAT IS THE INTERRELATIONSHIP (IF ANY) OF THESE:**
- **POLYMORPHOUS LOWGRADE CARCINOMA**
- **EPIMYOEPITHELIAL CARCINOMA**
- **ADENOID CYSTIC CARCINOMA?**

SALIVARY GLAND

- **MOLECULAR ANALYSES--?ANY HELP**
  - DIAGNOSIS--NOT AT THIS POINT
  - Various cytogenetic and mutational abnormalities seen in different salivary gland tumors. Not specific or frequent enough for diagnostic or prognostic import (NOTE: cKIT)

SALIVARY GLAND: MIMICS

- **MOLECULAR ANALYSES--?ANY HELP**
  - HELP IN THERAPEUTICS?
  - EGFR:
    - Immunostaining for EGFR in over 90% of adenoid cystic and mucoepidermoid carcinomas.
    - HOWEVER, no mutations or gene amplification of EGFR noted.

    (Macarenco et al Mod Pathol 2008)

SALIVARY GLAND: MIMICS

- **MOLECULAR ANALYSES--?ANY HELP**
  - HELP IN THERAPEUTICS?
  - HER2 neu
    - Immunostaining positive in over 80% of salivary duct carcinoma, 4% tom 45% of adenoid cystic carcinoma.
    - Result of Herceptin treatment—only one responder.
    - Clinical trial suspended.

    - Glisson et al Can. Cancer Res 2004; Slaehinejad et al Iranian J Pathol 2011.

CASE 3

- **DIAGNOSIS:**

  POLYMORPHOUS LOWGRADE ADENOCARCINOMA